

TABLE II  
COMPARISON OF CLINICAL FEATURES AND CYTOGENETIC FINDINGS IN 4 EXAMPLES OF  
TRISOMY FOR LONG ARM OF No. 4

	Franeke	Surana and Conen	Schrott <i>et al</i>	Propositus
Face	Small palpebral fissures; epicanthal folds; prominent occiput	Hypertelorism and low-set malformed ears	Minor anomalies of nose and right ear; mild micrognathia	Moderately dysmorphic; hypertelorism; ? low-set ears
Genitalia	'Hypoplastic external genitalia'	Undescended testes; at necropsy right testis was abdominal, left not located	Right testis undescended	Left testis only identified; in inguinal canal
Renal tract	Not mentioned	Bilateral renal hypoplasia; hydronephrotic right kidney	Hydronephrotic left kidney; outflow obstruction	Normal
Additional clinical features	Mental subnormality; limitation of motion in neck and hips; alive at 4 years	Short neck with loose skin folds posteriorly; supernumerary digit right hand; bilateral rockerbottom deformity; dilated rectosigmoid area; but normal biopsy findings; ? tetralogy of Fallot; died at 7 months; necropsy revealed pulmonary stenosis, ventricular septal defect, right ventricular hypertrophy, and overriding aorta	Low birthweight; microcephaly, mental subnormality; poor muscle tone; bilateral simian creases with <i>atd</i> angles in <i>r'</i> position; alive at 30 months	Microcephaly; mental subnormality; exomphalos; Hirschsprung's disease; simian creases not present; <i>atd</i> angles in <i>t</i> position; alive at 40 months
Cytogenetic findings	46,XY,20q + mat; trisomy distal half long arm No. 4; partial monosomy long arm No 20	46,XY,18q + mat; trisomy distal half long arm No. 4; partial monosomy long arm No. 18	46,XY,13q + mat[t(4;13)(q26 or q27;q34)]; trisomy distal third long arm No. 4; monosomy terminal part long arm No. 13	46,XY,9q + mat[t(4;9)(q31;q34)]; trisomy distal third long arm No. 4; monosomy terminal part long arm No. 9

tion of segments of varying length, and that chromosomal deficiency (different in each patient) may further complicate the gene imbalance, the present authors see no clear indication of a distinctive pattern of clinical abnormality associated with 4q+. All four patients are male and in each case unbalanced chromosome abnormality followed segregation from a mother with a reciprocal translocation.

The authors thank Dr Doreen C. B. Colver for her help in examining the patient and the Department of Paediatric Pathology, The Children's Hospital, Sheffield, for access to the case notes of the propositus.

M. ISSA, A. M. POTTER, and C. E. BLANK  
*From the Department of Zoology, Damascus University; and the Centre for Human Genetics, Sheffield*

#### REFERENCES

- Franeke, U. (1972). Quinacrine mustard fluorescence of human chromosomes: characterization of unusual translocations. *American Journal of Human Genetics*, **24**, 189-213.
- Schrott, H. G., Sakaguchi, S., Franeke, U., Luzzatti, L., and Fialkow, P. J. (1974). Translocation, t(4q-;13q+), in three generations resulting in partial trisomy of the long arm of chromosome 4 in the fourth generation. *Journal of Medical Genetics*, **11**, 201-205.
- Seabright, Marina (1971). A rapid banding technique for human chromosomes. *Lancet*, **2**, 971-1972.
- Surana, R. B. and Conen, P. E. (1972). Partial trisomy 4 resulting from a 4/18 reciprocal translocation. *Annales de Génétique*, **15**, 191-194.

## Tetraploidy in a liveborn infant

**Summary.** A congenitally malformed infant with a tetraploid chromosome complement who survived to 1 year of age is reported. The relationship of the polyploidy and the anomalies is discussed.

Polyploidy is generally well tolerated in plants and invertebrate animals but appears to be lethal or sublethal in man and other mammals. Niebuhr (1974) collected data on 275 cases of triploid abortuses and 18 cases of triploid fetuses surviving 28 weeks of gestation. He noted that the 8 infants who lived more than a few days were all 2n/3n mosaics. There has been great variability among the malformations reported in these patients. Tetraploidy is less common and only 16 tetraploid abortuses have been reported (Geneva Conference, 1966; Hamerton, 1971) none of which contained a formed embryo. We wish to report a congenitally malformed infant with a tetraploid chromosome complement who survived to 1 year of age.

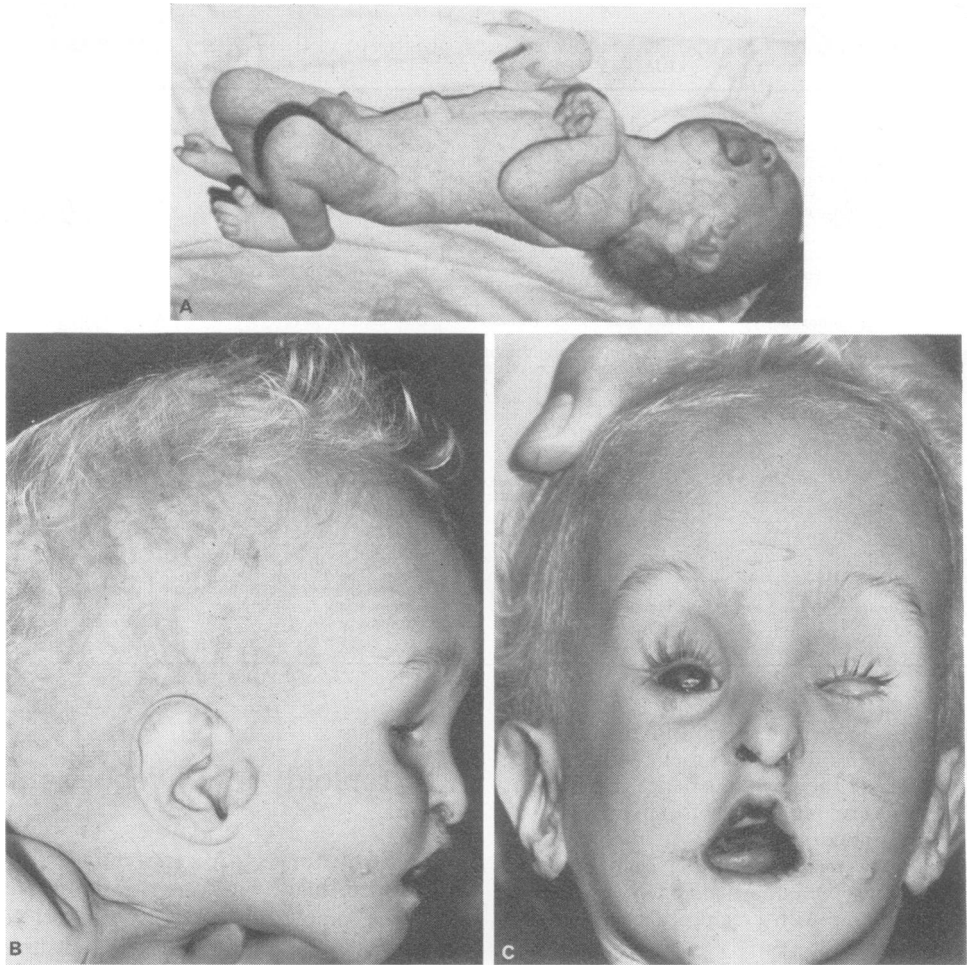


FIG. 1. The propositus at birth (A) and at 1 year of age (B and C).

### Case report

The patient was a white boy, the third child of a 26-year-old mother and 30-year-old father. There was no family history of consanguinity, multiple abortions, congenital malformations, or mental retardation. No drugs were ingested during early pregnancy, though the mother had used spray adhesives before conception and throughout early pregnancy in her art work. There were no prenatal infections and no other known complications. The maternal blood type is O, Rh negative without demonstrable antibody titre. Fetal activity was felt by 4 to 5 months' gestation but was decreased in comparison with the two earlier pregnancies.

The patient was delivered vaginally at term weighing 2150 g (<3rd centile). The length was 47.5 cm (<10th centile); head circumference 32.5 cm (<3rd centile); and chest circumference, 29.5 cm. Other physical findings at birth included a prominent narrow bifrontal

diameter, blond sparse hair, low set ears deficient in cartilage so that the superior and posterior helices were unravelled, bilateral preauricular tags, a papular lesion on the left mid-cheek, left anophthalmia, right microphthalmia with an opacified cornea, short philtrum, beaked nose, bifid uvula, hyperconvex fingernails, low set thumbs, left simian line, bilateral wide spacing between the hallux and 2nd toes, and generalized hypotonia (Fig. 1). The wrists, fingers, and ankles were held in flexion but there were no contractures. The dermatoglyphs were difficult to read, but included 5 arches, 1 ulnar loop, 1 radial loop, 2 whorls, and one undetermined.

X-rays revealed a shortened left first metacarpal and midthoracic kyphosis and scoliosis. An intravenous pyleogram and retrograde studies showed normal kidneys, normal renal calyces, bilateral megaureters, bilateral ureteral reflex, and urethral stenosis. An

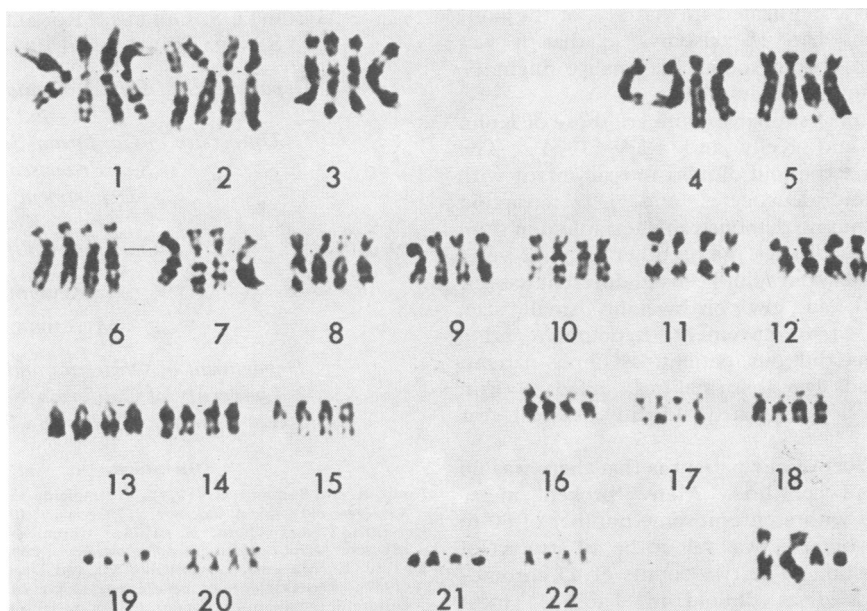


FIG. 2. Karyotype from a skin fibroblast.

electrocardiogram was normal and the serum phenylalanine level was 1 mg/100 ml.

Analysis of cultured peripheral lymphocytes on two occasions revealed that almost all cells had 92 chromosomes (Fig. 2). Giemsa banding studies delineated the karyotype as tetraploidy (92,XXYY). Chromosome analysis of skin and lung fibroblasts verified the tetraploidy (Table).

The propositus grew poorly and at 1 year of age weighed 4540 g and had a length of 57 cm, head circumference of 43.5 cm, and chest circumference of 37 cm. There had been no developmental progress and he never developed head control. He died unexpectedly of clinically undetermined causes at 51 weeks of age.

Necropsy revealed that in addition to the anomalies noted above there were multiple foci of suppuration in both kidneys, thymic hypoplasia, lymphoid depletion of the spleen, gut, lymph nodes, and thymus, and an unexplained encephalopathy. The pyelonephritis was considered to be the proximate cause of death and blood

cultures were positive for enterococci, *Klebsiella pneumoniae*, and *Esch. coli*.

### Discussion

There have been a few reports of patients with a mosaic tetraploid line. DeToni *et al* (1967) described three children with transient leucocyte tetraploid/diploid mosaicism whose mothers had been taking anticonvulsive treatment throughout pregnancy. None of these children had anomalies that could be related to the chromosomal findings and the significance of this temporary mosaicism is not clear. Hauschka *et al* (1962) reported a patient whose major leucocyte line had an XYY sex chromosome complement and whose skin fibroblasts were tetraploid in 15% of the metaphase spreads: the patient was described as intelligent and physically normal, but 5 of his 10 children were abnormal and a number had abnormal karyotypes secondary to non-disjunction. Turner and Wald (1965) described an apparently normal infant who had 9 to 14% tetraploid cells in repeated leucocyte cultures and who later died of leukaemia. Unfortunately, no other cell lines had been studied cytogenetically. A boy with multiple anomalies and borderline intelligence was reported by Atnip and Summitt (1971) as having 11-17% tetraploid leucocytes and 22% tetraploid skin fibroblasts.

TABLE  
CHROMOSOME ANALYSIS IN TISSUES EXAMINED

	Diploid	Tetraploid
Lymphocytes (Aug., 1973)	2	22
Lymphocytes (Oct., 1973)	0	500
Skin	0	1000
Lung	0	500

This case was complicated in that 9% of the non-polyploid cells had 18 trisomy, so that it was unclear which chromosome abnormality might be responsible for which anomalies.

The cases most similar to ours are those of Kohn *et al* (1967) and Kelly and Rary (1974). The former was a tetraploid/diploid mosaic infant with 69% tetraploid leucocytes and 1% tetraploid marrow cells but no demonstrable tetraploid in skin, muscle, or lung tissues. The other was a 2-year-old girl with 29% tetraploid cells in different tissues. Both infants had low birthweight, small size, decreased *in utero* movement, hypotonia, and a simian line as did our patient. Kohn's patient, like ours, had eye abnormalities, failed to gain weight or develop, and died suddenly before 1 year of age.

A unique facet of our patient is that there was no mosaic diploid cell line. Many 'broken' metaphase spreads with a chromosome number of 80 to 90 were seen but this was felt to be an artefact of slide preparation. The two counts of 45 chromosomes (identified as diploid in Table 1) most probably represent such 'broken' spreads and not a true diploid cell line. The cell nuclei on the necropsy tissue slides were all of one size and did not fall into two size classes as seen in the mosaic case of Kohn *et al* (1967). The relation between the maternal use of spray adhesive and the chromosome abnormality is probably spurious. The original claim of karyotype irregularities secondary to use of spray adhesives has since been refuted (Seely, 1973; Cervenka and Thorn, 1974). We, as well as others, have performed chromosome studies on pregnant women exposed to spray adhesives but no increase in chromosome breaks or other abnormalities was noted (F. Conte, M. Golbus, and B. Hall, unpublished observations).

The most significant aspect of this case is not that certain anomalies were associated with the tetraploidy, but that the anomalies were not more severe. Our patient, with 46 extra chromosomes, had abnormalities comparable to those seen in patients with the single extra chromosome in trisomy 13 or trisomy 18. This suggests that the balance between chromosomes and/or the ratio between different portions of the chromatin is more important than the absolute number of chromosomes present, but does not negate the fact that even 'balanced' polyploidy is developmentally deleterious.

We thank Drs William Tibbs and Robert Carrel for their co-operation in allowing us to study this patient, and Mr Leonard Berry and Ms. Giesela Abbo-Halsbach and Judith Romanowski for their technical assistance.

MITCHELL S. GOLBUS,\* RONALD BACHMAN,  
SANDRA WILTSE, and BRYAN D. HALL

*Departments of Obstetrics and Gynecology  
and of Pediatrics  
University of California San Francisco  
San Francisco, California;  
Department of Pediatrics  
Kaiser Hospital  
Oakland, California, USA*

\*Reprint requests to  
MITCHELL S. GOLBUS,

*Department of Obstetrics and Gynecology  
University of California San Francisco  
San Francisco, California 94143, USA*

#### REFERENCES

- Atnip, R. and Summitt, R. (1971). Tetraploidy and 18-trisomy in a six-year-old triple mosaic boy. *Cytogenetics*, **10**, 305-317.
- Cervenka, J. and Thorn, H. (1974). Chromosomes and spray adhesives. *New England Journal of Medicine*, **290**, 543-545.
- DeToni, E., Massimo, L., Vianello, M., and Dagna-Bricarelli, F. (1967). Osservazione di cellule tetraploidi ed eteroploidi in culture di sangue di tre lattanti, figli di madri sottoposte prima e durante la gravidanza a terapia con farmaci anticonvulsivanti. *Minerva Pediatrica*, **20**, 2092-2096.
- Geneva Conference (1966). Standardization of Procedures for Chromosome Studies in Abortion. *Bulletin of the World Health Organization*, **34**, 765-782.
- Hamerton, J. S. (1971). *Human Cytogenetics: Clinical Cytogenetics*, Vol. 2, p. 381. Academic Press, New York.
- Hauschka, T., Hasson, J., Goldstein, M., Koepf, G., and Sandberg, A. (1962). An XYY man with progeny indicating familial tendency to non-disjunction. *American Journal of Human Genetics*, **14**, 22-30.
- Kelly, T. E. and Rary, J. M. (1974). Mosaic tetraploidy in a two-year-old female. *Clinical Genetics*, **6**, 221-224.
- Kohn, G., Mayall, B., Miller, M., and Mellman, W. (1967). Tetraploid-diploid mosaicism in a surviving infant. *Pediatric Research*, **1**, 461-469.
- Niebuhr, E. (1974). Triploidy in man. *Humangenetik*, **21**, 103-125.
- Seely, J. (1973). Letter to U.S. Consumer Product Safety Commission.
- Turner, J. and Wald, N. (1965). Endoreduplication and disease. *Lancet*, **1**, 915.

## 46,XY/46,XY,21q- mosaicism in an infant with neutropenia and properdin deficiency\*

**Summary.** An infant with neutropenia, properdin deficiency, and a 46,XY/46,XY,21q- mosaicism is described. It is not known whether these two findings are related to the missing 21q material.

\* This study was supported in part by contract C-60793 from the Birth Defects Institute, New York State Department of Health, Albany, NY, USA.