

## Severe mental retardation in a boy with partial trisomy 10q and partial monosomy 2q

JOHN A. SILLS, KARIN E. BUCKTON,\* and JOHN A. RAEBURN

*From the University Department of Child Life and Health, Royal Hospital for Sick Children; Medical Research Council, Clinical and Population Cytogenetics Unit, Western General Hospital; and the University Department of Human Genetics, Western General Hospital, Edinburgh*

**Summary.** A severely mentally subnormal child with many physical stigmata was shown to have the karyotype 46,XY,-2,+der(2),t(2;10)(q31;q24)pat. Full evaluation of this patient's karyotype depended on the family studies. It was shown that a balanced translocation t(2;10) was present in 4 normal males in 3 generations.

New cytogenetic methods have greatly extended the scope for recognition of chromosome anomalies. In the event of a patient with an unbalanced chromosome rearrangement being born to a balanced translocation carrier parent, it is now possible to identify the duplication and deficiency segments of the chromosome involved. The clinical features of such a patient can then be compared with those of patients who have similar duplications and deficiencies to identify the common phenotypic abnormalities.

In our patient the long arms of both a chromosome No. 2 and No. 10 are involved in the translocation. Patients with unbalanced translocations involving the long arm of a No. 2 chromosome (Ricci *et al*, 1968; Lozzio and Karrine, 1969; Bijlsma *et al*, 1971; Francke, 1972; Forabosco *et al*, 1973) have been described. Unbalanced translocations involving a No. 10 chromosome appear to be more frequent (Francke, 1972; De Grouchy *et al*, 1972; Laurent *et al*, 1973; Talvik *et al*, 1973; Mulcahy *et al*, 1974; Roux *et al*, 1974; Yunis and Sanchez, 1974; Kroyer and Niebuhr, 1975), which is surprising since until recently the No. 10 chromosome could not be distinguished from other C group chromosomes with conventional staining methods.

Patients with unbalanced translocations and their relatives can also be informative for gene mapping.

### Case history

The proband (III.1) was the first born of unrelated parents, after an uneventful pregnancy and spontaneous vertex delivery. The birthweight was 2.85 kg. Development was slow in all fields. From the age of 6 months he had epileptic seizures which were both *grand mal* and Jacksonian in type; his electroencephalogram showed generalized epileptic discharges but no localizing abnormalities. The seizures were partially controlled with phenytoin 50 mg b.d. At age 10, he could only walk with considerable support. He had no speech development and responded to loud sounds only, with no attempt at localization. His level of comprehension was assessed at around 4 months and his postural and manipulative development at 10 months. He was totally dependent on others for all basic needs. He was microcephalic (head circumference 48.5 cm) and he had an odd face (Fig. 1). The eyes were microphthalmic and deeply set with an antimongoloid slant to the palpebral fissures. There was an intermittent squint and bilateral ptosis. The optic fundi appeared normal. There was no nystagmus. There was a long philtrum to the upper lip, the nares were somewhat anteverted, the ears low set, and the palate was highly arched. The chest had a gross degree of pectus excavatum and bilateral cervical ribs were present. The penis was small, the scrotum normal, and there was no evidence of secondary sex characteristics. The upper limbs showed a cubitus valgus deformity and some wasting of muscles distal to the elbow. The hands showed ulnar deviation of the fingers, which were spindle shaped, with a degree of hypoplasia of the pulp of the distal phalanges. The thumbs were small and proximally placed. There were no fixed contractures of the fingers, but they adopted a flexed position (Fig. 2). The little fingers had two flexor creases. There was a radio-ulnar synostosis. In the legs there

Received 21 April 1976.

\* Reprint requests to Karin E. Buckton.

were no contractures of hips or knees, and both hips were in joint. The feet showed a valgus deformity, there were bilateral longitudinal plantar creases, and a wide gap between the hallux and second toes together with syndac-

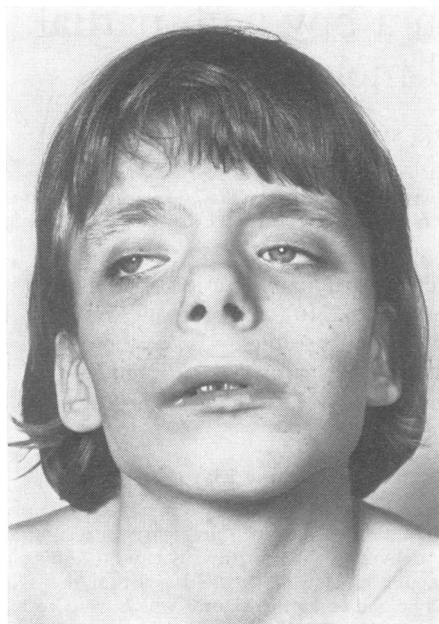

FIG. 1. Facial view of the proband at age 11. Note the ptosis and microphthalmia.

tyly of the proximal two phalanges of the fourth and fifth toes bilaterally.

At the age of 11 years 5 months he died suddenly during an epileptic fit. At necropsy the following additional findings were noted. The cardiovascular system

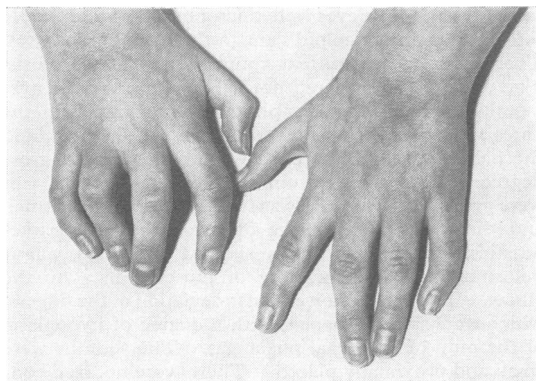


FIG. 2. Hands of the proband showing radial deviation of the little fingers and ulnar deviation of the index and middle fingers.

was normal and the lungs showed only acute congestive changes. The liver, spleen, and kidneys were also normal as were the ureters and the bladder. The left testis was absent. On the right side there was a small cystic structure containing seminiferous tubules lined by mainly immature Sertoli cells, but a few spermatogonia were detected.

The brain was swollen and the cerebral hemispheres were small. There was conspicuous dilatation of the lateral ventricles and a reduction of central white matter consistent with the degree of hydrocephalus. The aqueduct was narrowed in the middle third but there was no occlusion. There were a number of other abnormalities (further details can be supplied on request) but histologically there was no evidence of a storage disorder. The pituitary was very small (0.2 g) and congested, but was histologically normal.

The dermatoglyphs of the proband and his family will be published separately.

### Cytogenetic studies

Chromosome analysis was made on cells from a peripheral blood sample grown for 3 days by a modification of the method of Hungerford (1965). Initially the cells from the proband were examined after having been stained with aceto-orcein and one No. 2 chromosome appeared shorter than the other. G-banding by the ASG technique (Sumner *et al.*, 1971), confirmed that one No. 2 chromosome did not have the correct banding pattern on the long arm (Fig. 3a), but the exact origin of

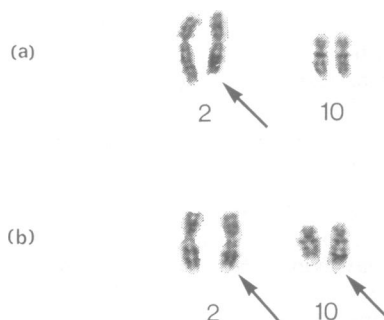


FIG. 3. G-banded partial karyotypes from (a) the proband (III.1) and (b) the proband's father (II.2).

this anomaly was not immediately obvious. Chromosome analysis of the proband's parents revealed that his father had a balanced translocation, his karyotype was 46,XY,t(2;10)(q31;q24) (Fig. 3b) (Paris Conference, 1971). The mother's karyotype was normal 46,XX. Therefore, it was now possible to say that the proband's karyotype was 46,XY,-2,+der(2),t(2;10)(q31;q24)pat; he was trisomic for 10q24→10qter and was monosomic for 2q31→2qter.

### Family studies

The pedigree is shown in Fig. 4. The proband's parents and all other members of the family were fully examined and were found to be entirely healthy. All the normal males in this family were found to carry the (2;10) translocation, whereas the females were normal 46,XX. No cytogenetic or necropsy studies could be performed on the abortuses.

### Genetic marker studies

The genetic markers were studied by the M.R.C. Human Biochemical Genetics Unit. As the assignment

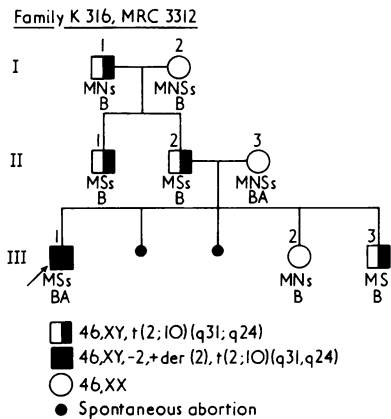


Fig. 4. Pedigree of family K316, MRC 3312, showing the cytogenetic findings in 8 family members and their MNS and ACP<sub>1</sub> status.

of ACP<sub>1</sub> and MNSs to chromosome 2 has been suggested (Mace *et al*, 1975) particular attention was paid to these markers, which are shown in Fig. 4.

### Discussion

None of the patients with unbalanced translocations previously described is monosomic for a similar length of 2q, (2q31→2qter), and it is a little surprising that the patient survived the neonatal period since he was monosomic for a large segment of chromosome material. However, several patients with unbalanced translocations involving 10q are trisomic for a similar length (10q24→10qter), and a comparison of the phenotypic features has been made by Kroyer and Niebuhr (1975). The patient described by de Grouchy *et al* (1972), who was trisomic for 10q, was stillborn at term and no necropsy was permitted, so data are scanty. Her external appearance, however, was somewhat similar to the other cases listed. In most patients with this syndrome mental retardation is accompanied by a characteristic facies (particularly ptosis and microphthalmia), microcephaly, and widespread skeletal abnormalities (Table). The other chromosome involved in the translocation has varied widely (either 1, 3, 4, 13, 15, 18, or 22) and it is of interest that partial monosomy of these has not greatly influenced the gross clinical abnormalities. There is a need for more experience of such anomalies, identified either clinically or on the basis of a demonstrable trisomy of 10q. Partial trisomy 10 is clearly compatible with life and in the association of

TABLE

PHENOTYPIC FEATURES OF THOSE PATIENTS WITH PARTIAL 10q TRISOMY WHO SURVIVED EARLY INFANCY

| Clinical Features*         | Schutt (1966) (updated) 46XX,der(4),t(4;10) | Reference and other Cytogenetic Features |   |  |  |  |   |                                  |
|----------------------------|---|--|---|--|--|--|---|----------------------------------|
|                            |   | Francke (1972) 46XX,der(15),t(10;15)     | Laurent <i>et al</i> (1973) 46XX,der(1),t(1;10) | Talvik <i>et al</i> (1973) 46XY,der(14),t(10;14) | Roux <i>et al</i> (1974) 46XY,der(22),t(10;22) | Yunis and Sanchez (1974) 46XY,der(15),t(10;15) | Kroyer and Niebuhr (1975) 46XX,der(18),t(10;18) | Present Case 46XY,der(2),t(2;10) |
| Age (alive/dead)           | 18 years (alive)                            | 4 years (dead)                           | 9 months (dead)                                 | 11 months (dead)                                 | 4 years (alive)                                | 6 years (alive)                                | 18 years (alive)                                | 11 years (dead)                  |
| Microphthalmia             | +   | +  | +   | +  | Not stated                                     | +  | +   | +                                |
| Prosis                     | +   | +  | +   | +  | +  | +  | +   | +                                |
| Micrognathia               | +   | +  | +   | +  | +  | +  | +   | +                                |
| Palatal abnormality        | Cleft palate                                | Agnesis of palate                        | Cleft palate                                    | High-arched palate                               | -  | -  | -   | High-arched palate               |
| Scoliosis                  | +   | -  | -   | +  | -  | +  | +   | +                                |
| Other skeletal abnormality | +   | -  | Osteoporosis                                    | +  | -  | +  | +   | +                                |
| Miscellaneous              | Muscle hypotonia                            | -  | Systolic murmur (no necropsy)                   | Patent foramen ovale                             | -  | Renal and cardiac lesions, muscle hypotonia    | -   | Epilepsy                         |

+ = Abnormality present. - = No abnormality present.

\* All patients had severe mental and growth retardation, low set ears, a depressed nasal bridge and, with the exception of Francke's patient, microcephaly.

mental retardation, facial, and skeletal abnormalities, it has similarities to trisomy or partial trisomy 8 (Lejeune and Rethoré, 1973).

Our family provides further information on the mapping of chromosome 2. Since the patient, monosomic for part of 2q, is a heterozygote at the red cell acid phosphatase (ACP<sub>1</sub>) and MNS loci, these loci cannot be in the chromosome region 2q31→2qter, substantiating previous reports (Mace *et al.*, 1975). The data, combined with linkage information from other families, have been presented elsewhere (Higgins *et al.*, 1975).

It is noteworthy that 4 normal males in this family carry the translocation and that the proband is also male; other families with partial trisomy 10q have had no preponderance of males. The future management of this family depends very much on the provision of facilities for antenatal diagnosis and if necessary on selective termination of pregnancy. Such measures are of special importance in families where partial trisomy 10q may arise, since patients with this chromosome abnormality have severe mental retardation plus physical deformities and may well survive into late childhood.

It is a pleasure to acknowledge Miss Heidi Boland for skilful technical assistance and Dr A. D. Forrest for referring the index patient. Dr R. Nagle kindly performed the necropsy and Dr A. F. J. Maloney provided the neuropathological reports.

#### REFERENCES

- Bijlsma, J. B., de France, H., Bleeker-Wagemakers, E. M., and Wijffels, J. C. H. M. (1971). Duplication deficiency syndrome in familial translocation (2q-;5p+). *Humangenetik*, **12**, 110-112.
- de Grouchy, J., Finaz, C., Roubin, M., and Roy, J. (1972). Deux translocations familiales survenues ensemble chez chacune de deux soeurs, l'une équilibrée, l'autre trisomique partielle 10q. *Annales de Génétique*, **15**, 85-92.
- Forabosco, A., Dutrillaux, B., Toni, G., Tamborino, G., and Cavazzuti, G. (1973). Translocation équilibrée t(2;13)(q32;q33) familiale et trisomie 2q partielle. *Annales de Génétique*, **16**, 255-258.
- Francke, U. (1972). Quinacrine Mustard fluorescence of human chromosomes: characterisation of unusual translocations. *American Journal of Human Genetics*, **24**, 189-213.
- Higgins, J. V., Wisniewski, L., Hassold, T., Hackel, E., Raeburn, J. A., Buckton, K. E., Noades, J. E., and Cook, P. J. L. (1976). Two informative translocations involving chromosome 2. In *Baltimore Conference. Third International Workshop on Human Gene Mapping. Birth Defects: Original Article Series*. The National Foundation, New York. In the press.
- Hungerford, D. A. (1965). Leukocytes cultured from small inocula of whole blood and the preparation of metaphase chromosomes by treatment with hypotonic KCl. *Stain Technology*, **40**, 333-337.
- Kroyer, S. and Niebuhr, E. (1975). Partial trisomy 10q occurring in a family with a reciprocal translocation t(10;18)(q25;q23). *Annales de Génétique*, **18**, 50-55.
- Laurent, C., Bovier-Lapierre, M., and Dutrillaux, B. (1973). Trisomie 10 partielle par translocation familiale t(1;10)(q44;q22). *Humangenetik*, **18**, 321-327.
- Lejeune, J. and Rethoré, M.-O. (1973). Trisomies of chromosome No. 8. Nobel Symposium (23). In *Chromosome Identification*, pp. 214-216. Academic Press, New York and London.
- Lozzio, C. B. and Karrine, A. A. (1969). Familial transmission of a chromosomal translocation t(2q+;Cp-). *Journal of Medical Genetics*, **6**, 174-179.
- Mace, M. A., Noades, J., Robson, E. B., Hulten, M., Lindsten, J., Polani, P. E., Jacobs, P. A., and Buckton, K. E. (1975). Segregation of ACP<sub>1</sub> and MNS<sub>S</sub> in families with structural rearrangements involving chromosome 2. *Annales de Human Genetics*, **38**, 479-484.
- Mulcahy, M. T., Jenkyn, J., and Masters, P. L. (1974). A familial 10/13 translocation: partial trisomy C in an infant associated with familial 10/13 translocation. *Clinical Genetics*, **6**, 335-340.
- Paris Conference (1971). Standardization in human cytogenetics. *Birth Defects: Original Article Series*, Vol. 8, No. 7. The National Foundation, New York 1972.
- Ricci, N., Dallapiccola, B., and Cotti, G. (1968). Translocation 2-D familiale. *Annales de Génétique*, **11**, 111-113.
- Roux, C., Taillemite, J. L., and Baheux-Morlier, G. (1974). Trisomie partielle 10q par translocation familiale t(10q-;22p+). *Annales de Génétique*, **17**, 59-62.
- Schutt, W. H. (1966). Chromosomal and single gene defects in children with clefts of lip and palate. In *The Causes and Natural History of Cleft Lip and Palate*, pp. 217-228. Ed. by C. M. Drillen, T. T. S. Ingram, and E. M. Wilkinson. E. and S. Livingstone, Edinburgh and London.
- Sumner, A. T., Evans, H. J., and Buckland, R. A. (1971). New technique for distinguishing between human chromosomes. *Nature New Biology*, **232**, 31-32.
- Talvik, T., Mikkelsaar, A.-V., Mikkelsaar, R., Kaosar, M., and Tuur, S. (1973). Inherited translocations in two families t(14q+;10q-) and t(13q-;21q+). *Humangenetik*, **19**, 215-226.
- Yunis, J. J. and Sanchez, O. (1974). A new syndrome resulting from partial trisomy for the distal third of the long arm of chromosome 10. *Journal of Pediatrics*, **84**, 567-570.