

The clinical anomalies observed in this patient were strikingly mild and included short stature, small head circumference, widely spaced nipples, and pectus excavatum. One or more of the physical anomalies have been cited by others in association with ring C chromosomes (Gacs *et al*, 1970; Moore *et al*, 1973; Zackai and Breg, 1973). However, in all instances there were additional abnormalities that were not present in our case, or the chromosome involved was not chromosome 10. Atkins *et al* (1966) and Therkelsen *et al* (1971) detected possible ring 10 chromosomes in 3 patients; however, the clinical features present in these patients appear to be more severe than those of the present case. Furthermore, identification of the ring as a modified chromosome 10 was not conclusive.

The structural locus for cytoplasmic aspartate transaminase has been localized to the long arm of chromosome 10 and specifically to the q24-qter region (Chern *et al*, 1975). Our patient lacked one structural allele for this enzyme in at least half of her cultured lymphocytes. If the same degree of mosaicism exists in other tissues, one-half normal levels of this enzyme would have been expected to be observed in her cells and in her serum; however, her serum levels fell within the normal range. This result could be explained if the structural allele was not located on the deleted segment of the long arm, and if half or more of the cells giving rise to the serum enzyme had both an intact chromosome 10 and the ring. Unfortunately, the family situation contraindicated skin biopsies to assess the degree of mosaicism in other tissues.

The authors thank Dr Chatrath for referral of this patient and Dr D. Bartlett for his assistance with the physical examination of the patient.

SUSAN LANSKY, WILLIAM DANIEL, and
KATHY FLEISZAR

*Department of Genetics and Development and
School of Basic Medical Sciences, University of
Illinois, Urbana, Illinois 61801, USA*

References

- Atkins, L., Pant, S., Hazard, G., and Ouellette, E. (1966). Two cases with a C-group ring autosome. *Annals of Human Genetics*, **30**, 1-6.
- Chern, C., Mellman, W., and Croce, C. (1975). Assignment of the structural gene for cytoplasmic glutamic-oxalacetic transaminase (GOT) to region q24-qter of human chromosome 10. *American Journal of Human Genetics*, **27**, 25a.
- Fried, K., Rosenblatt, M., Mundel, G., and Kikler, R. (1975). Mental retardation and congenital malformations associated with a ring chromosome 6. *Clinical Genetics*, **7**, 192-196.
- Gacs, G., Schuler, D., and Sellyei, M. (1970). Familial occurrence of congenital malformations and ring chromosome (46,XX,Cr). *Journal of Medical Genetics*, **7**, 177-179.

- Moore, C., Heller, R., and Thomas, G. (1973). Developmental abnormalities associated with a ring chromosome 6. *Journal of Medical Genetics*, **10**, 299-303.
- Seabright, M. (1972). The use of proteolytic enzymes for the mapping of structural rearrangements in the chromosomes of man. *Chromosoma (Berlin)*, **36**, 204-210.
- Therkelsen, A., Møller, B., and Henningsen, K. (1971). A group C ring chromosome in a mentally deficient male. *Journal of Medical Genetics*, **8**, 277-230.
- Zackai, E. and Breg, W. R. (1973). Ring chromosome 7 with variable phenotypic expression. *Cytogenetics and Cell Genetics*, **12**, 40-48.

46,XX/46,XX,r(15) mosaicism Report of a case

SUMMARY Mosaicism of cells with a normal karyotype or with a ring chromosome no. 15 was found in a girl with hypoplasia of the thumbs, club feet, mental retardation, and short stature, which seems to be a feature of this chromosomal aberration.

Duplications and deficiencies of the chromosome no. 15 in man are rare and no consistent phenotypic patterns have been deduced from the observations hitherto published. Three cases of r(15) have been reported with which our observation can be compared. It was thought that one or more features reflecting the deficiency of the long arm would be shared if only because the short arm lost by the ring formation is considered genetically inert.

Case report

The patient is the second child of healthy unrelated parents aged 32 and 26. The first child, a female, was stillborn and severely malformed (diprosopia, single ventricle of the heart with dextroposition of the aorta, omphalocele). Cytogenetic studies were not performed.

The patient was born at term after an uneventful pregnancy. The weight at birth was 2420 g, the length was 45 cm. Bilateral clubfeet were present. Her early psychomotor progress appeared normal. At the age of 16 months her weight was 7300 g, her length was 71 cm, her head circumference was 43 cm (all below the 3rd centile). Both thumbs were slender, the movements of the terminal joint being limited. X-ray films showed hypoplasia of the first metacarpal and both phalanges. The toes were irregularly inserted. Two *café-au-lait* spots on the thigh and over the xiphoid, respectively, and a mild thoracic scoliosis were noted. Dermatoglyphs

did not show any unusual patterns. The ossification was retarded.

At the age of 4.8 years her weight was 13 kg, her length was 95.5 cm, her head circumference was 46.5 cm (all below the 3rd centile). Her mental development was obviously retarded but she was very active and socially well adapted (Fig. 1).

After the diagnosis of Fanconi's syndrome was suggested, the blood has been examined at various intervals, but there has been no evidence of aplastic anaemia.

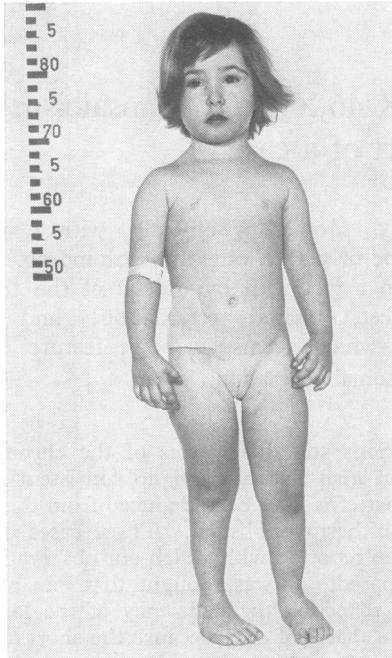


Fig. 1 Aspect and hands of the patient at the age of 3½ years.

Cytogenetic studies

Two cell lines were found with either 46,XX or 46,XX,r(15) in lymphocytes (ratio 20:30) and fibroblasts from a skin biopsy (ratio 24:26). The size of the ring chromosome varied widely. No chromosomal breaks were noted even at various occasions when by the QM, G-, and BrdU-techniques the ring chromosome was identified as no. 15 (Fig. 2).

The karyotypes of the parents were normal.

Discussion

The clinical findings of 3 cases with r(15) reported in the literature are summarized in the Table. No particular features were noted and there seems to be no craniofacial dysmorphism but—as Stoll *et al* (1975) emphasized—all cases share low birthweight and short stature. If, indeed growth failure is an effect of r(15) then it is even operating in mosaicism. However, it must be kept in mind, that the parents of the patient described by Forabosco *et al* (1972) were small and that the patient of Stoll *et al* (1975) was of Portuguese origin. An anomaly of the thumbs as seen in our case was not mentioned. Since aplasia of the thumbs is a striking feature of r(13) (Niebuhr and Ottosen (1973)) any abnormality would not have been overlooked. Forabosco *et al* (1972) noted irregular brachymesophalangy but observations on the child need to be repeated for accurate diagnosis. Mental deficiency, noted in 2 patients, may be related to a 'chronic hematoma of the left front complicated by external hydrocephalia' in the case of Stoll *et al* (1975).

The clinical features of our patient are suggestive of Fanconi's anaemia. Random association cannot be excluded since the child has not yet reached the maximum risk period of aplastic anaemia. If, however, she is heterozygous for this recessive gene and if by the terminal deficiency of the chromosome

TABLE

SUMMARY OF 3 PUBLISHED CASES WITH r(15) ANOMALY

	Age (y)	Sex	Parental Ages (y)	Height (cm)	Birthweight/Length	
Jacobsen (1966)	41	M	29/33	148	1800 g/45 cm	Narrow forehead (head circumference 47 cm), small, low set ears, short fifth fingers, small feet, cryptorchism. Intelligence at the upper limit of the imbecile level
Forabosco <i>et al</i> (1972)	1.4	F	35/31	67 (< 3 centile)	2300 g	'Phenotype almost normal' short fingers, irregular brachymesophalangy, pyloric stenosis
Stoll <i>et al</i> (1975)	2.2	F	27/25	78 (< 3 centile)	2310 g	Brachycephaly (head circumference 42 cm), external hydrocephaly, hypertelorism, abnormal ears, flat philtrum, micro-retrognathia, slow psychomotor development, amyotrophy

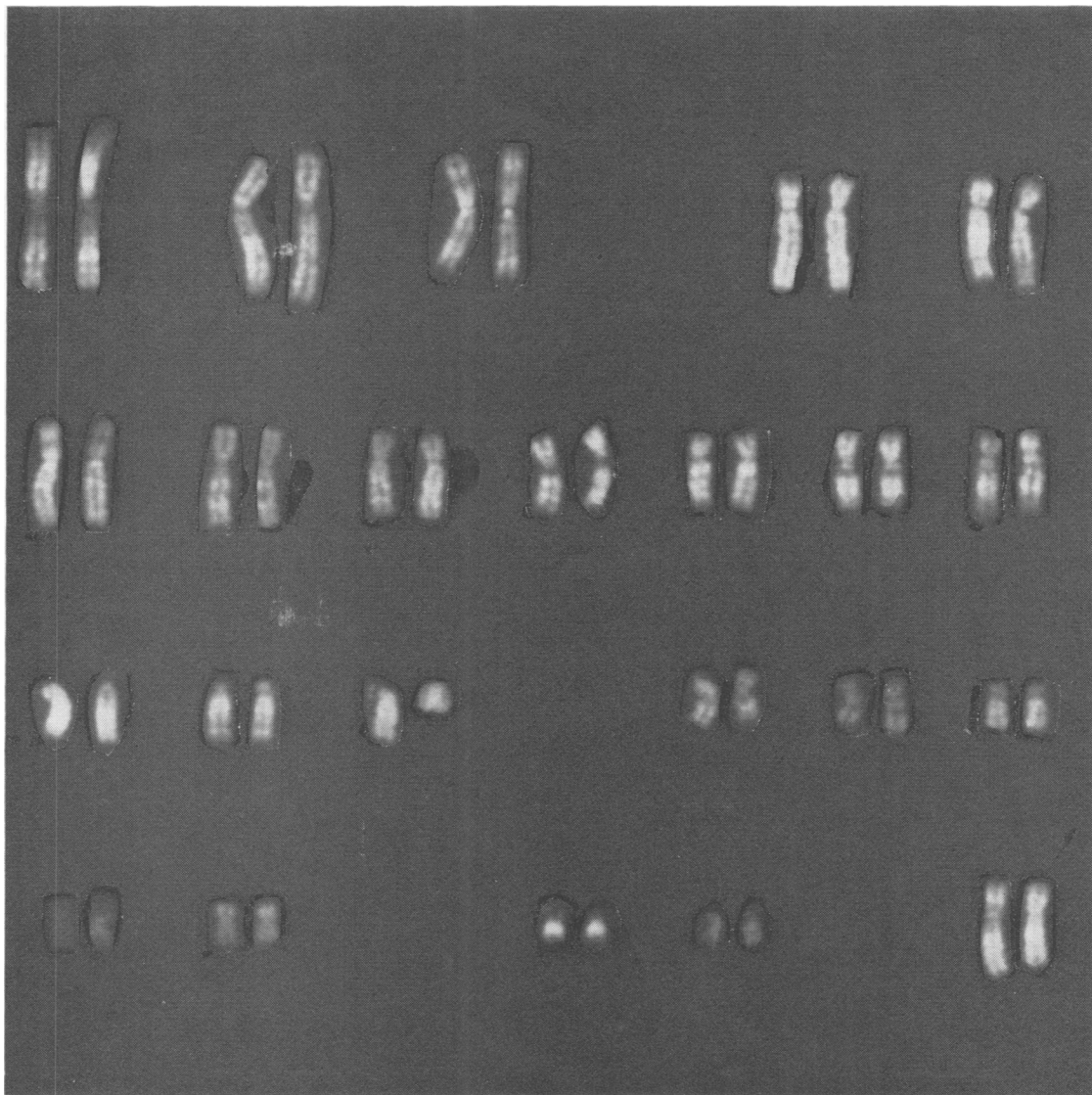


FIG. 2 Karyogram from a lymphocyte (QM-technique).

no. 15 the locus would have been lost, one could expect a mild form of this disease, particularly when in bone-marrow a selection against the abnormal cells would be operating.

R. A. PFEIFFER, R. DHADIAL, and W. LENZ
 Abteilung für Humangenetik der Medizinischen
 Hochschule D-24 Lübeck, Ratzeburger Allee 160;
 Institut für Humangenetik der Westfälischen
 Wilhelms Universität D-44 Münster, Vesaliusweg
 12-14, Germany

References

- Forabosco, A., Dutrillaux, B., Vazzoler, G., and Lejeune, J. (1972). Chromosome 15 en anneau: r(15). Identification par dénatura-tion ménagée. *Annales de Génétique*, **15**, 267-270.
- Jacobsen, P. (1966). A ring chromosome in the 13-15 group associated with microcephalic dwarfism, mental retardation and emotional immaturity. *Hereditas*, **55**, 188-191. (And personal communication, January 1974.)
- Niebuhr, E. and Ottosen, J. (1973). Ring chromosome D(13) associated with multiple congenital malformations. *Annales de Génétique*, **16**, 157-166.
- Stoll, C., Juif, J. G., Luckel, J. C., and Lausecker, C. (1975). Ring chromosome 15:r(15). Identification by R banding. *Human-genetik*, **27**, 259-262.