

100 cells studied. Trypsin banded preparations of both parents and sisters showed normal karyotypes. Blood group findings did not reveal paternity exclusion.

Discussion

Jacobs (1974) discussed the correlation between euploid structural chromosome rearrangements and mental subnormality. While in a normal newborn survey *de novo* balanced reciprocal translocation was found in at least 1/3000, in mentally subnormal individuals it was found in at least 1/1000. She suggested that more intensive study of mutant individuals might well enable us to determine not only the proportion of euploid mutations associated with a phenotype effect but also the mechanism by which the effect is produced. This was further discussed by Jenkins *et al.* (1975). At present even though our case seems to have normal mental development we cannot but join in the hesitation expressed by Laurence and Gregory (1976) about prenatal diagnosis. They state, 'When there is a balanced translocation present, the pregnancy ought to be allowed to go to term. There may be some worry when this has arisen *de novo* in the fetus, as in the process some deletion may have occurred which is not detectable even by the banding techniques, in which case the fetus may be phenotypically abnormal.' *The Paris Conference (1971), Supplement (1975)* has also dealt in some detail with examples of *de novo* structural rearrangement. It seems that more detailed reports of *de novo* balanced reciprocal translocations are needed before a rational decision on termination can be reached, if such a fetus is detected on amniocentesis. Such reports will help to establish the distribution and frequency of points of breakage and exchange in human chromosomes; and allow a determination of the effect, if any, of parental age on the occurrence of translocations.

K. FRIED, M. ROSENBLATT, and G. MUNDEL

*Departments of Genetics and Paediatrics,
Asaf Harofe Hospital, Tel-Aviv University Medical
School, Zerifin, Israel*

References

- Hamerton, J. L., Canning, N., Ray, M., and Smith, S. (1975). A cytogenetic survey of 14,069 newborn infants. I. Incidence of chromosome abnormalities. *Clinical Genetics*, **8**, 223-243.
- Jacobs, P. A. (1974). Correlation between euploid structural chromosome rearrangements and mental subnormality in humans. *Nature*, **249**, 164-165.
- Jenkins, E. C., Curcuro-Giordano, F. M., Krishna, S. G.,

and Cantrarella, J. (1975). *De novo* occurrence of 46,XX,t(4;13)(q31;q14) in a mentally retarded girl. *Annales de Génétique*, **18**, 117-120.

Laurence, K. M., and Gregory, P. (1976). Prenatal diagnosis of chromosome disorders. *British Medical Bulletin*, **32**, 9-15.

Paris Conference (1971), Supplement (1975): Standardization in Human Cytogenetics. Birth Defects: Original Article Series, XI, 9, 1975. The National Foundation, New York.

Seabright, M. (1971). A rapid banding technique for human chromosome. *Lancet*, **2**, 971-972.

Sumner, A. T., Evans, H. J., and Buckland, R. A. (1971). New technique for distinguishing between human chromosomes. *Nature (New Biology)*, **232**, 31-32.

A partial long arm deletion of chromosome 7: 46,XY,del(7)(q32)¹

SUMMARY We have identified a partial deletion of the long arm of chromosome 7 in a newborn baby boy. His major anomalies were microcephaly, synbrachydactyly, diastasis recti, hypospadias, short neck, and widely spaced nipples.

With the development of the various new banding techniques, cytogenetic diagnosis of different types of chromosome deletions as well as clinical recognition of these deletion syndromes have become possible. With G-, R-, and Q-banding methods (Paris Conference, 1972), we have identified a partial deletion of the long arm of a No. 7 chromosome in a newborn male infant with multiple congenital anomalies.

Case report

The propositus (031273), was a product of the second pregnancy of a 29-year-old class A diabetic black woman. There was no history of fetal wastage in the mother or in two previous generations. The delivery was by caesarian section because of fetal distress at 35 weeks' gestation. Apgar score was 2 at 1 minute and 5 at 5 minutes. The birthweight was 1680 g and the length was 41 cm. The following congenital anomalies were noted: microcephaly (head circumference 29.5 cm) (Fig. 1a), synbrachydactyly of the right hand with hypoplastic nails on the thumb and the 5th finger (Fig. 1b), diastasis recti, first degree hypospadias, short neck, and widely spaced nipples. Both testes were descended. There was conspicuous

¹This work was supported by Grants (GM-19443 and HD-02552) from the U.S. Public Health Service and a Medical Service Grant from the National Foundation (C-155).

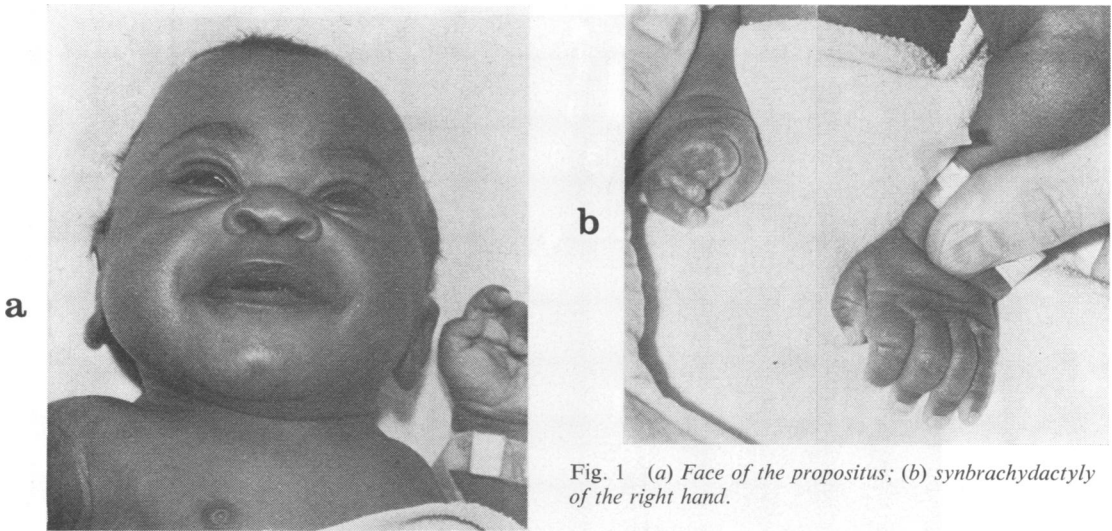


Fig. 1 (a) Face of the propositus; (b) synbrachydactyly of the right hand.

hypertonicity as well as hyperreflexia in all four extremities. The remaining physical examination was not remarkable.

The dermatoglyphs showed ulnar loop pattern on right 5th, left thumb, index, and 3rd, whorl on left 4th and 5th fingers, arch on right thumb.

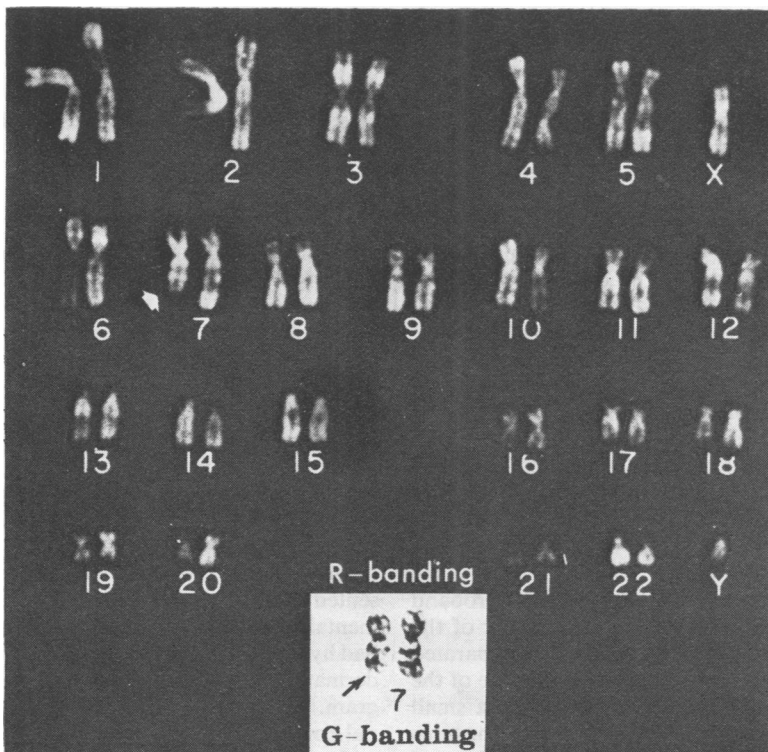


Fig. 2 R-banding karyotype and a partial G-banding karyotype of two No. 7 chromosomes.

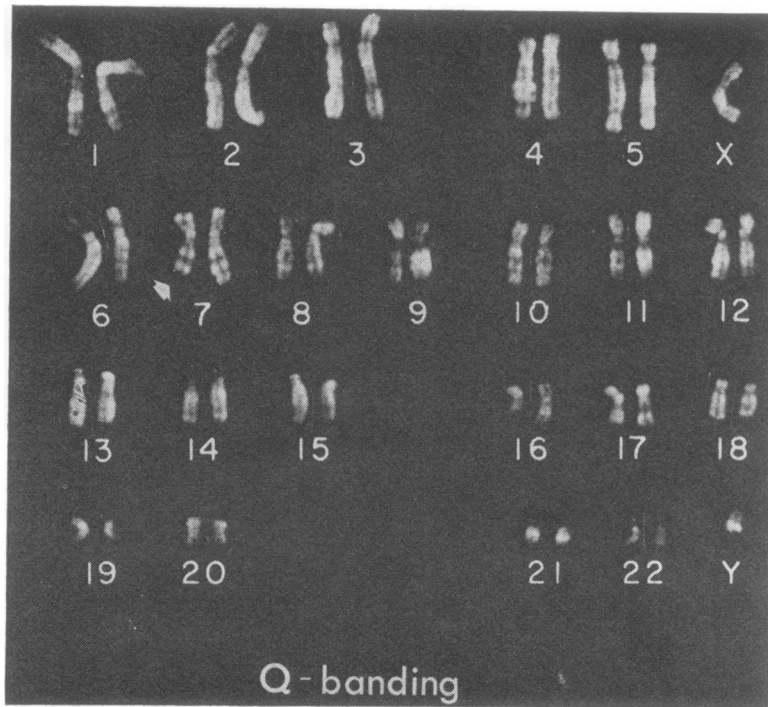


Fig. 3 *Q*-banding karyotype.

triradii were located normally at *t* position. There was a simian crease on the left palm and one single crease on the left 5th digit. The hallucal areas showed large distal loop pattern bilaterally. The remaining patterns were not remarkable.

The neonatal period was complicated by bradycardia, probably caused by the documented hypocalcaemia. The rhythm disorder disappeared promptly after treatment with exogenous calcium. The intravenous pyelogram showed no evidence of obstruction and two functioning kidneys. The skeletal survey showed no abnormalities except of the right hand in which all metacarpal bones were seen, but only the proximal phalanx of the 5th finger was identified. The other distal bones of that hand were absent.

CYTOGENETIC STUDIES

Cultures of peripheral leucocytes from the proband and his mother were carried out. The father of the patient refused to be studied and is now separated from the mother. The conventional karyotype of the patient appeared grossly normal. However, a small deletion of the long arm of one No. 7 chromosome 46,XY,del(7)(q32), was clearly seen by G-, R-, and Q-banding methods (Fig. 2 and 3). The conventional

as well as banded karyotypes of the mother were normal.

Discussion

To our knowledge, there have been two reports of patients with deletions involving chromosome 7 (Zackai and Breg, 1973; Shokeir *et al.*, 1973). Zackai and Breg reported two boys with apparently identical rings of chromosome 7 with quite different phenotypic expression: while one of them had severe growth and developmental lag together with multiple congenital anomalies, the other had normal development and intelligence and no significant physical anomalies except short stature and small head. Shokeir *et al.* (1973) reported a woman with a translocation involving No. 2 and 7 with deletion of the long arm of the latter. Clinically, this patient presented with stunted physical growth, moderate mental retardation, and renal anomalies. She also had hypertelorism, bilateral simian creases, abnormal dermatoglyphs, and abnormal electroencephalogram. W. R. Breg and R. M. Fineman (1976, personal communication) have recently studied a patient with a similar partial deletion of the long arm of one No. 7 chromosome, del(7)(q32). This patient was a

15-month-old white male. He had psychomotor retardation and severe failure to thrive. His congenital anomalies were microcephaly, bradycephaly, cleft lip and palate, and flat nose.

Thus far, patients with 7q- share only a few features in common, i.e. mental and growth retardation and microcephaly. Hopefully, when more patients with 7q- are identified, a better clinical delineation of this abnormality will be possible.

BORIS G. KOUSSEFF,² LILLIAN Y. F. HSU,

SOPHIE PACIUC, and KURT HIRSCHORN

The Department of Pediatrics, Division of Medical Genetics, Mount Sinai School of Medicine, New York, New York 10029, USA

References

- Paris Conference 1971 (1972). Standardization in Human Cytogenetics. *Birth Defects Original Article Series*, Vol. VIII, No. 7. The National Foundation.
- Shokeir, M. H. K., Ying, K. L., and Pabello, P. (1973). Deletion of the long arm of chromosome No. 7. Tentative assignment of the Kidd (JK) locus. *Clinical Genetics*, 4, 360-368.
- Zackai, E. H., and Breg, W. R. (1973). Ring chromosome 7 with variable phenotypic expression. *Cytogenetics and Cell Genetics*, 12, 40-48.

²Dr Kousseff is presently at the Department of Pediatrics, Queens Hospital Center, Jamaica, N.Y. 11432.

Down's syndrome and deletion of short arms of a G chromosome

SUMMARY A woman in a family in which a G group chromosome (No. 21) with deleted short arms (21p-) is present has passed this chromosome to an intellectually deficient son, a normal son, and a daughter with Down's syndrome. Another daughter is chromosomally and phenotypically normal. As in other reports that focus on a concurrence of Gp- chromosomes and Down's anomaly, the possibility is considered that this chromosomal variant may predispose to developmental abnormalities or to non-disjunction, or both.

There are a number of reports of heritable structural variations of the chromosomes being associated with families with both normal and abnormal phenotypes (Gardner *et al.*, 1974; Neu and Kajii, 1969), including familial variants affecting the short arms of the G group chromosomes (Neu and Kajii, 1969;

Neu *et al.*, 1966; Jagiello and Faiman, 1967; Migeon, 1965; Shaw, 1962). Distinct from this functional aspect is the question of the relation between such variants and the occurrence of non-disjunction, a relation which might be inferred to exist in families in which a minor rearrangement and aneuploidy occur together (Neu *et al.*, 1966; Shaw, 1962; Starkman and Shaw, 1967).

At present it is difficult to establish, in any particular instance where they are associated, that the presence of an abnormal phenotype in one sibling or of aneuploidy in another is due to the presence of a small chromosome variant in one of the parents. The genetic and clinical significance of such variants is likely to remain obscure until enough cases are reported for statistical inferences to be made about possible predispositions. This report describes a family in which both clinical abnormalities and aneuploidy are associated with a chromosomal variant.

Case report

A boy aged 6 years 9 months and unable to read was seen at the Child Health Clinic, Hamilton, New Zealand, in 1969. He was the second sibling of Dutch parents, delivered normally after a full-term, normal pregnancy with a birth weight of 4308 g. He was reported to cry well at birth but to suck poorly for three days after delivery. His motor, language, and toilet milestones were slow in appearing and a psychometric assessment at 6 years 4 months indicated an intelligence quotient of 50 to 60.

Investigations for thyroid function; bacterial inhibition tests for metabolic errors; urine amino-acid chromatography; fasting blood sugar; and urea, calcium, and serum proteins were normal. He had a history of normal electroencephalograms and there were no abnormal neurological signs. His hair was fair and, apart from showing mild atopic eczema, he had a normal facial appearance. There was mild clinodactyly of the fifth fingers, which also had rather underdeveloped nails.

Chromosome studies of cultured peripheral leucocytes showed that all cells carried a G chromosome with deleted short arms. Giemsa banding established this chromosome as No. 21 (karyotype 46,XY,21p-) (Fig. 1 and 2). Karyotypic analyses of the mother and older brother showed that they also carried the 21p- chromosome (Fig. 3). Like the index case, both showed mild clinodactyly of the fifth fingers. The father's karyotype was normal as was that of a younger female sibling. The mother's second pregnancy ended in a miscarriage at 11 weeks.

There were no indications of consanguinity but a