

placenta and chorionic sacs were of no help for diagnosis. The dermatoglyphs are expected to be different, even if they were monozygotic, in relation to the total finger ridge count; since according to Penrose (1967), when the number of X chromosomes increases, the TFRC decreases in about 30 per each extra X. The difference of 112 found in our case is so striking that we believe that we are facing a case of dizygosity. On the other hand, the blood groups were conclusive. All the systems studied were alike in both twins except for the Rh. In the propositus the phenotype was CCDee while in the brother it was cCDee, which rules out monozygosity.

The incidence of dizygotic twins with nonconcordant chromosomal aneuploidy appears to be low. To the best of our knowledge we think that ours is the first reported case of dizygotic twins with this specific anomaly.

As the Xg blood group was positive in the parents and the twins, it was not possible for us to know the origin of the X chromosomes.

In the wide study carried out by Race and Sanger (1969), the origin of the X chromosomes could be established only in 3 of the 29 patients with 49,XXXXY by assessing the Xg blood group. In those 3 cases, the 4 X chromosomes were of maternal origin. We are inclined to believe that the same occurs in our case, i.e. a double non-disjunction during maternal oogenesis. If this were true, the most probable origin of the 47,XXY twin was also a non-disjunction in the mother.

Ferguson-Smith (1958), Hoefnagel and Benirschke (1962), and Nielsen (1966) have described an increased incidence of twins in the sibships of patients with the Klinefelter's syndrome. Later on Soltan (1968) estimated the incidence of twins among sibs in Klinefelter's syndrome, and he found it to be higher than expected. Both Hoefnagel and Nielsen explain this major proportion of twins through an maternal age effect.

It seems evident that in the case of dizygosity, the tendency to non-disjunction and to twinning increases with the age of the mother. In our case the age of the mother was 26 years and thus it does not agree with this hypothesis. However, the ages in 2 of the 5 families described by Nielsen (1966) were between 20 and 23 years.

Tumba (1974) has shown that the incidence of 49,XXXXY patients is related to the age of the mother. In his series the mean age was 28, with two peaks corresponding to ages 29 and 35.

On the other hand, we should not underestimate the hypothetical environmental influence that may be the cause of both, the meiotic non-disjunction and the twin pregnancy, either as separate events joined by chance or as a single event.

Further cytogenetic studies in twins would be necessary to find out whether there is a relation between non-disjunction and double ovulation or whether these 2 events are independent but could occur at the same time by chance.

We want to thank Dr Maroto and Dr Rodriguez-Durantez for performing the cardiological and radiological studies; Dr A. Valls for performing the Xg blood group. We also wish to thank Mrs A. Morán and Mrs M. C. Cacituaaga for their technical assistance.

J. M. GARCÍA-SAGREDO, C. MERELLO-GODINO,
and C. SAN ROMÁN

*From the Department of Human Genetics,
Fundación Jimenez Diaz, Madrid; and
U.C.I., Hospital Infantil, C.S. Francisco Franco,
Madrid*

References

- Ferguson-Smith, M. A. (1958). Chromatin-positive Klinefelter's syndrome (primary microorchidism) in a mental-deficiency hospital. *Lancet*, **1**, 928-931.
- Hoefnagel, D., and Benirschke, K. (1962). Twinning in Klinefelter's syndrome. *Lancet*, **1**, 1282.
- Nielsen, J. (1966). Twins in sibships with Klinefelter's syndrome. *Journal of Medical Genetics*, **3**, 114-116.
- Nielsen, J. (1970). Twins in sibships with Klinefelter's syndrome and the XYY syndrome. *Acta Geneticae Medicae et Gemellologiae*, **19**, 399-403.
- Penrose, L. S. (1967). Finger-print pattern and the sex chromosomes. *Lancet*, **1**, 298-300.
- Race, R. R., and Sanger, R. (1969). Xg and sex-chromosome abnormalities. *British Medical Bulletin*, **25**, 99-103.
- Soltan, H. C. (1968). Genetic characteristics of families of XO and XXY patients, including evidence of source of X chromosomes in 7 aneuploidic patients. *Journal of Medical Genetics*, **5**, 173-180.
- Tumba, A. (1974). L'influence de l'âge parental sur la production de l'anomalie XXXXY. *Journal de Génétique Humaine*, **22**, 73-97.

Requests for reprints to Dr J. M. García Sagredo, Servicio de Genética, C. E. Ramón y Cajal, Carretera de Colmenar Km. 9 100, Madrid-34, Spain.

Ring chromosome 4

SUMMARY A mentally and physically retarded boy with a 46,XY,ring(4) (p16q35) chromosome complement is described. Chromosome banding showed that the amount of chromosome material deleted from the ring chromosome 4 was minimal, apparently no more than the telomeres. Chromo-

somal aberrations appear to be restricted to the production of double-sized dicentric rings, and aneuploidy. The mosaicism resulting from the behavioural peculiarities of ring chromosomes is described as *dynamic mosaicism*. It is suggested that the clinical features associated with this ring chromosome are more likely to be the result of the effects of a diploid/monosomy 4/polysomy 4 mosaicism than to the deficiency of the telomeric regions of the chromosome.

Ring chromosomes are deletion chromosomes from which genetic material has been lost from the ends of both arms of a chromosome. They have been reported in all chromosome groups of the human karyotype, but there are few instances in which the application of chromosome banding techniques has enabled the precise identification of the deleted chromosome segments (Nakagome *et al.*, 1973).

This report describes a mentally and physically retarded boy with a 46,XY,ring (4) karyotype in which the precise points of breakage involved in the formation of the ring chromosome 4 have been identified by chromosome banding.

Case report

The propositus is the only child of healthy unrelated parents. His birthweight at full term was 1.59 kg (3 lb 8 oz). After birth, he was found to be hypoglycaemic and was treated with intravenous glucose.

Growth and mental retardation were noted at subsequent follow-up. At 16 months he was only 6 kg and 66 cm in length (both below third centile). This was associated with developmental retardation; sitting up at 12 months, and making no attempt to stand or pull himself up at 16 months, when he had 3 or 4 words of vocabulary but was still feeding with his hands and not with a spoon. At this stage, owing to the peripatetic nature of his family, he was lost to follow-up. He was seen again at the age of 4 years (Fig. 1) when he was found to be an alert, lively, miniature boy with brown hair and blue eyes; his skin was dry and scaling over the upper trunk. His height was 86 cm; weight 9.2 kg; head circumference 43 cm (all below the third centile). His teeth were deficient in enamel, with some caries, and the canines were sharply pointed. There were no palatal anomalies, and he had normal ears. There were no abnormalities in the cardiovascular, respiratory, or alimentary systems. He had a curved terminal phalynx of the 5th digit, long slender thumbs (Fig. 2), mobile calcaneal valgus feet, and a small sacrococcygeal dimple. He could run and climb well, could hop and jump, and had good fine manipulation with a pencil. He was unable to match



Fig. 1 *Propositus at 4 years.*

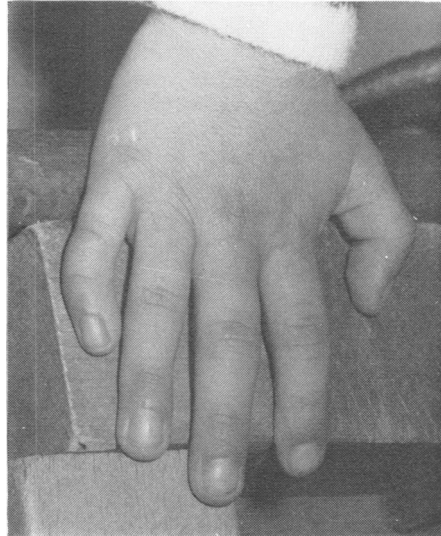

Fig. 2 *Incurved 5th digit and long, slender thumbs.*

shapes for a Stycar 5 testing, but on miniature toy matching his visual acuity was 6/6 with both eyes. Binaural responses to free field audiometry showed normal responses. He had a good comprehension of speech, including pronouns and quite complicated commands, but his expressive language was less well developed. Psychological assessment credited him with an IQ of approximately 50, with some areas of skill, such as the use of pegboards and imitative use of a pencil, above this level.

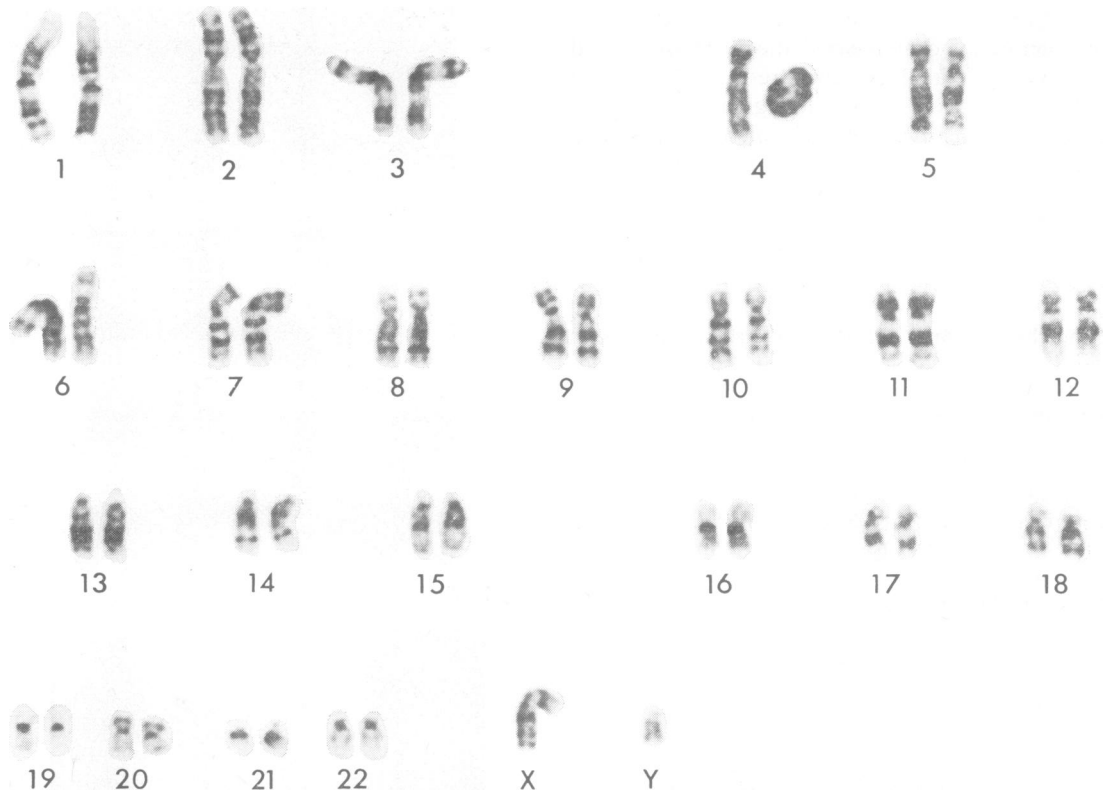


Fig. 3 Karyotype of propositus: 46,XY,ring(4)(p16q35).

OTHER INVESTIGATIONS

At 4 years he had a bone age of 2.8 years. X-ray of the pituitary fossa and chest were normal. Haematological investigations: Haemoglobin 12.3 g/dl. White blood count $\times 10^9/l$. PCV 37.0. Normal differential white blood cell count. Serum alkaline phosphatase 32 units/100 ml. Serum calcium 10.2 mg/100 ml (2.55 mmol/l). Inorganic phosphorus 4.7 mg/100 ml (1.5 mmol/l). Serum PBI 8.1 $\mu g/100$ ml (638.3 nmol/l). Urinary steroids: (17-KS/17-OS) 1 mg/24 hours, and 17-OHCS, 3 mg/24 hours.

CYTOGENETIC INVESTIGATIONS

Chromosome studies were undertaken on blood cultures. The chromosomes were banded by treating the air-dried preparations with 0.5% trypsin (2 to 5 minutes) after a pre-soak in $2 \times$ SSC for 3 hours at 60°C, and stained with Giemsa (Gurr's R66).

The consistent chromosome defect in the male karyotype was the replacement of one chromosome 4 by a ring chromosome (Fig. 3). The ring chromosome occurred in both monocentric and dicentric forms, and was seen singly or in pairs in almost all cells examined (Fig. 4). The distribution of ring types

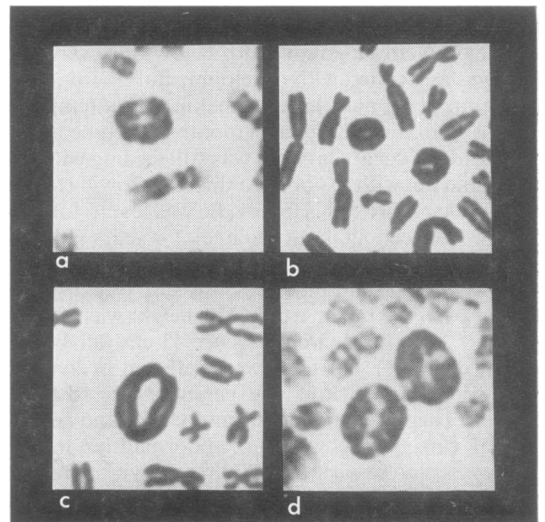


Fig. 4 Variation in number and types of rings. (a) Single monocentric; (b) two monocentrics; (c) single dicentric; (d) two dicentrics.

in 300 cells screened is shown in the Table. No cells containing a normal karyotype were found. Analysis of the banded preparations revealed that the points of breakage which preceded the formation of the ring were at the distal ends of bands p16 and q35. The banding patterns of the normal 4 and ring chromosome 4 are compared in Fig. 5. The size of the fusion band p16/q35 indicates clearly that the amount of chromosome material lost is immeasurably small, and can consist of no more than the telomeres.

The parental chromosomes were normal.

The results of investigations on blood groups (Dr R. Sanger) and biochemical markers (Dr E. B. Robson) were normal.

Discussion

The structural and behavioural instability of ring chromosomes is well known (McClintock, 1938; Kistenmacher and Punnett, 1970). Their instability is reflected in the numbers of rings present, variation in the size of the rings, variation in the number of centromeres they possess, the occurrence of interlocked rings, and the presence of chromosome fragments. These aberrations are usually the direct or indirect consequence of sister chromatid exchange. A single or uneven number of sister chromatid exchanges in a monocentric ring chromosome produces a dicentric ring which is twice the size of the original: two sister-chromatid exchanges (or an even number), however, produce an interlocked pair of

chromatid rings. In both instances, separation of the sister centromeres to opposite poles at cell division can result in irregular breakage in the ring chromosomes, producing rings or fragments of different sizes. The variation in the numbers of ring chromosomes present in a cell reflects their predisposition for non-disjunction.

Ring chromosomes vary in the extent to which they manifest these abnormalities, some rings being apparently quite stable. Analysis of the behaviour of a wide range of human ring chromosomes suggests that the structural and behavioural instability of a ring is a function of its structure and/or its genetic content rather than its initial size (Kistenmacher and Punnett, 1970).

In the present case all the bands normally associated with chromosome 4 can be identified in the ring chromosome (Fig. 5), indicating that the initial ring has lost only the telomeric regions of the chromosome. These regions are generally considered to be heterochromatic and primarily concerned with the attachment of the chromosomes to the nuclear membrane; it is unlikely, therefore, that the loss of this minute segment alone would be of any clinical significance. The only sign of structural instability observed was the occurrence of double-sized dicentric forms in approximately 6% of cells. Aneuploid cells resulting from non-disjunction of the ring were almost twice as common (Table). As far as genetic content is concerned the cells containing two monocentric rings or a single dicentric ring are identical, both being effectively trisomic for chromosome 4; those cells without a ring are monosomic, and the two cells found to contain two dicentric rings are effectively pentasomic for chromosome 4.

The consequence of the irregular but persistent generation of genetically different cells, promoted by the behavioural peculiarities of a ring chromosome, may be described as a *dynamic mosaicism*. In the present case, all the aberrant cells are genetically aneuploid, being effectively monosomic or poly-somic for chromosome 4.

In common with 7 previously reported cases, apparently involving a ring chromosome 4 (not always confirmed) (Parker *et al.*, 1974), the present patient had a low birthweight, growth retardation, mental retardation, unusual first and fifth digits, a sacral dimple, and retarded bone age, but there was no evidence of the following malformations which were found commonly in these cases: micrognathia, cleft lip/palate, cardiac malformations, hypospadias, hyperplasia of external genitalia, forearm abnormalities, and seizures. The majority of these latter features have also been associated with deletion of the short arm of chromosome 4 (4p- syndrome), an overlap which is not unexpected in cases where a

Table Distribution of rings in 300 cells from lymphocyte culture

Ring type	Monocentric	Dicentric	Ring absent from complement of 45 chromosomes
No. present in cell	1	2	1
No. of cells	249	25	16
Percentages	83	8.3	5.3
			0.7
			2.7

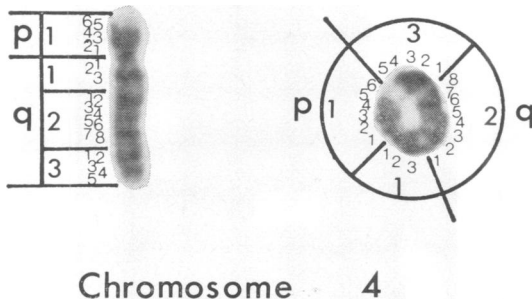


Fig. 5 G-banding indicates loss of negligible amount of chromosome material in formation of ring.

sufficiently large portion of the short arm has been deleted before ring chromosome formation. In the present case, however, it is suggested that the clinical malformations are more realistically ascribed to the effects of the diploid/monosomy 4/polysomy 4 mosaicism than to the deletion of the telomeric regions of the chromosome.

A. McDERMOTT, M. A. VOYCE, AND
D. ROMAIN

*From S. W. Regional Cytogenetics Centre,
Southmead Hospital, Westbury-on-Trym, Bristol;
and Royal Cornwall Infirmary, Truro*

References

- Kistenmacher, M. L., and Punnett, H. H. (1970). Comparative behaviour of ring chromosomes. *American Journal of Human Genetics*, **22**, 304-318.
- McClintock, B. (1938). The production of homozygous deficient tissues with mutant characteristics by means of the aberrant mitotic behaviour of ring-shaped chromosomes. *Genetics*, **23**, 315-376.
- Nakagome, Y., Iinuma, K., and Taniguchi, K. (1973). Points of exchange in a human No. 5. ring chromosome. *Cytogenetics and Cell Genetics*, **12**, 35-39.
- Parker, C. E., Alfi, O. S., Derenesenyi, A., Mavalwala, J., and Donnell, G. (1974). A child with a ring-4 chromosome (46,XX/46,XX,+4). *American Journal of Diseases of Children*, **128**, 371-374.

Requests for reprints to Dr A. McDermott, South Western Regional Cytogenetics Centre, Department of Pathology, Southmead Hospital, Westbury-on-Trym, Bristol BS10 5NB

Prenatal recognition of 4p- syndrome

SUMMARY A fetus with the rare 4p- syndrome was detected by chromosome analysis of amniotic cell culture, and the pregnancy terminated. The fetus showed a number of the physical stigmata of the syndrome.

Deletion of a portion of the short arm of chromosome number four is associated with a constellation of defects, first recognised as a distinct syndrome by Wolf and his colleagues in 1965. The most common features are severe growth retardation, profound mental deficiency, hypotonia, multiple craniofacial anomalies, cardiac defects, genital anomalies, mid-line scalp defects, and dermatoglyphic abnormalities. Despite these defects, the condition is compatible

with life, and though complications arising from the abnormalities may cause death in the first few years of life, survival into the second and third decades is not uncommon.

We report a fetus with 4p- syndrome, selectively aborted after prenatal diagnosis, and found to have many characteristics of the syndrome reported in survivors.

Case report

Mrs. S.P., aged 39 years, gravida 4, para 3, underwent diagnostic amniocentesis at 17 weeks in her fourth pregnancy because of her age. The fluid was dark brown in colour and the alpha-fetoprotein level of the supernatant was 21 µg/ml (normal range for 17 weeks 6 to 43 µg/ml). Culture of the amniotic cells was technically very difficult, as they grew extremely slowly. Chromosome preparations were eventually able to be made after 30 days in culture (the average time being 16 to 18 days). The quality was good and 62 fetal cells were analysed using G-banding. 59 had a chromosome complement of 46,XX,4p-, and 3 had a normal male complement. The pregnancy was terminated at 24 weeks by intra-amniotic infusion of hypertonic saline with 10 mg prostaglandin E₂.

The female fetus was fresh and weighed 371 g, crown-rump length 17 cm. This is small for 24 weeks (630 g and 20.7 cm, Streeter, 1921). The face (Fig.) was strikingly odd. There was ocular hypertelorism and the eyes were open and bulging. There was micrognathia, lowset ears, a high arched palate, cleft



Fig. Fetus showing characteristic facies of 4p- syndrome at 24 weeks' gestation.