

# Teaching NeuroImage: *ROBO3* Mutation Causing Horizontal Gaze Palsy and Brainstem Malformation

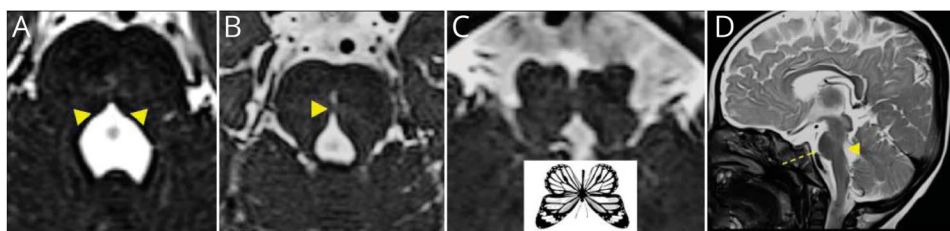
Geetha Chanda, MD Pediatrics, Nihaal Reddy, MD, Ramesh Konanki, MD, DM, Eugen Boltshauser, MD, and Lokesh Lingappa, MD, DM

## Correspondence

Dr. Chanda  
dr.geethachanda@gmail.com

*Neurology*® 2023;100:840-841. doi:10.1212/WNL.000000000206821

## Figure Imaging Findings of *ROBO3* Mutation



High-resolution heavily weighted T2 (CISS) axial images demonstrate (A) absent facial colliculi (arrowhead), (B) dorsal pontine cleft generating the split pons sign (arrowhead), and (C) butterfly configuration of medulla. T2 sagittal image demonstrates (D) pontine hypoplasia (dashed arrow), concave dorsal pontine border (arrowhead), and normal corpus callosum.

A 10-month-old boy presented with motor developmental delay, torticollis, bilateral abduction restriction (incomplete horizontal gaze palsy), and left lower motor neuron facial palsy. His brain MRI demonstrated brainstem malformations, including absent facial colliculi (Figure, A), clefting of the medulla and pons (Figure, B), butterfly configuration of the medulla (Figure, C), and concave dorsal pontine border (Figure, D). Genetic testing revealed a homozygous missense mutation (c.437G > C [p.Arg146Pro]) in exon 2 of the *ROBO3* gene. Horizontal gaze palsy with progressive scoliosis (HGPPS1) results from axonal guidance signalling defects caused by *ROBO3* mutations.<sup>1</sup> The main symptoms include congenital horizontal gaze palsy, horizontal pendular nystagmus, and progressive scoliosis after 2 years of age. The radiologic differential for this hindbrain malformation is horizontal gaze palsy with progressive scoliosis-2, caused by mutation in the *DCC* gene.<sup>2</sup> Children with HGPPS2 also demonstrate intellectual impairment and agenesis of the corpus callosum.<sup>2</sup>

## MORE ONLINE

### Teaching slides

[links.lww.com/WNL/C576](https://links.lww.com/WNL/C576)

## Author Contributions

G. Chanda: drafting/revision of the manuscript for content, including medical writing for content; major role in the acquisition of data. N. Reddy: drafting/revision of the manuscript for content, including medical writing for content; Major role in the acquisition of data. R. Konanki: drafting/revision of the manuscript for content, including medical writing for content; major role in the acquisition of data. E. Boltshauser: drafting/revision of the manuscript for content, including medical writing for content; major role in the acquisition of data. L. Lingappa: drafting/revision of the manuscript for content, including medical writing for content; major role in the acquisition of data.

From the Department of Pediatric Neurology (G.C., R.K., L.L.), Rainbow Childrens Hospital; Rainbow Childrens Hospital (N.R.), Hyderabad, India; and Eugen Boltshauser (E.B.), Department of Pediatric Neurology, University Childrens Hospital, Zurich.

Go to [Neurology.org/N](https://Neurology.org/N) for full disclosures.

## Study Funding

The authors report no targeted funding.

## Disclosure

The authors report no disclosures relevant to the manuscript. Go to [Neurology.org/N](https://www.neurology.org/N) for full disclosures.

## Publication History

Received by *Neurology* August 10, 2022. Accepted in final form December 2, 2022. Submitted and externally peer reviewed. The

handling editor was Resident and Fellow Deputy Ariel Lyons-Warren, MD, PhD.

## References

1. Pinero-Pinto E, Pérez-Cabezas V, Tous-Rivera C, et al. Mutation in ROBO3 gene in patients with horizontal gaze palsy with progressive scoliosis syndrome: a systematic review. *Int J Environ Res Public Health*. 2020;17(12):4467. doi:10.3390/ijerph17124467.
2. Marsh APL, Edwards TJ, Galea C, et al. DCC mutation update: congenital mirror movements, isolated agenesis of the corpus callosum, and developmental split brain syndrome. *Hum Mutat*. 2018;39(1):23-39. doi: 10.1002/humu.23361.

---

## Submit Your Work to *Neurology*<sup>®</sup> *Genetics*

*Neurology*<sup>®</sup> *Genetics*, edited by Stefan M. Pulst, MD, Dr med, wants to review your research for publication! This online-only, open-access journal publishes peer-reviewed reports in the area of neurogenetics that elucidate the role of genetic and epigenetic variations in diseases and biological traits of the central and peripheral nervous systems.

Learn how to prepare and submit your manuscript at: [NPub.org/NGAuthors](https://www.npub.org/NGAuthors)

---

---

## *Neurology*<sup>®</sup> Online CME Program

Earn CME while reading *Neurology*. This program is available to AAN members and to online *Neurology* subscribers. Read the articles marked CME, go to [Neurology.org](https://www.neurology.org), and click on the CME link. The American Academy of Neurology (AAN) is accredited by the Accreditation Council for Continuing Medical Education (ACCME) to sponsor continuing medical education for physicians. *Neurology* is planned and produced in accordance with the ACCME Essentials. For more information, contact AAN Member Services at 800-879-1960.


---

---

## Visit the *Neurology*<sup>®</sup> Website at [Neurology.org/N](https://www.neurology.org/N)

- More article-based content on home pages
- Streamlined menus and navigation
- Enhanced blog sections for specialty areas
- Same experience on desktop, tablet, and mobile devices
- Improved article reading experience; links more evident (pdf, analytics, social media)

 Find *Neurology*<sup>®</sup> on Facebook: <http://tinyurl.com/neurologyfan>

 Follow *Neurology*<sup>®</sup> on Twitter: <https://twitter.com/GreenJournal>

---