

Partial deletion of long arm of chromosome 11[del(11)(q23)] : Jacobsen syndrome

Two new cases and review of the clinical findings

A. SCHINZEL, P. AUF DER MAUR, AND H. MOSER

From the Division of Medical Genetics, Department of Pediatrics, University of Zurich; and Department of Pathology and Department of Pediatrics, University of Berne, Switzerland

SUMMARY Two cases, a boy and a girl, with the 11q- (Jacobsen) syndrome are reported. Findings common to both and typical for this chromosome aberration include a narrow protruding forehead, hypertelorism, non-horizontal position of the eyes, ptosis, strabismus, broad root, and short up-turned tip of the nose, carp mouth, receding chin, misshapen ears, simian creases, and severe mental retardation. In addition, one patient had pyloric stenosis and an inguinal hernia. Growth retardation and microcephaly were not found in either of them. The karyotypes revealed *de novo*-deletions of the long arm of one chromosome 11, del(11)(q23).

With the advent of chromosome banding techniques it became possible to identify at least two formerly unknown autosomal deletion syndromes in man: the 9p- and 11q- syndromes. Since the first description of the latter by Jacobsen *et al.* (1973), almost a dozen further cases of the 11q- syndrome have been reported (see Table 1), and it now seems that the clinical picture of this chromosome aberration is not less specific than that of deletions of chromosomes 4, 5, 13, and 18.

The purpose of the present report is to give a detailed clinical description of two further cases and to outline the typical clinical features of the 11q- syndrome.

Case histories

CASE 1

This male patient is the product of a second pregnancy of healthy parents of 25 (father) and 24 (mother) years of age at his birth. The family history is unremarkable except for several members who died of tumours. The older sister of the propositus was delivered by a caesarean section during the 38th week of gestation because of EPH-gestosis; her birthweight was 2970 g. So far she has developed normally both physically and mentally. The mother's second pregnancy was complicated by severe

EPH-gestosis leading to caesarean section during the 38th week of gestation. During the first week, the newborn suffered from moderate respiratory distress, hypoglycaemia, thrombocytopenia, and prolonged jaundice. Birthweight was 3090 g (50th centile), length was 47 cm (10th to 50th centile), and head circumference was 36 cm (over 90th centile). He was kept in an incubator and received oxygen and phototherapy. Periodical cyanosis during feeding was occasionally observed. After discharge on the 12th day of his life he failed to thrive. This, and increasing vomiting led to readmission at the age of 5 weeks. Pyloric stenosis and an inguinal hernia on the right side were diagnosed and subsequently operated.

On *clinical examination* at 5 weeks of age (Fig. 1 and 2a and b) he presented with multiple dysmorphic signs (see also Table 1). Weight (3420 g) and length (51 cm) were about 10th centile, head circumference (37.5 cm) was 50th to 75th centile. The skull was dolichocephalic with a keel-shaped high and protruding forehead. Dysmorphic signs of the face included hypertelorism, antimongoloid slant to palpebral fissures (more pronounced on the right side), bilateral ptosis, a broad-bridged, small nose with forward looking nostrils, a long upper lip, small, carp-shaped mouth, receding mandible, small and disproportionately broad misshapen ears with horizontally folded helices, prominent anthelices, hypoplastic antitragi, and attached lobules.

Received for publication 18 April 1977

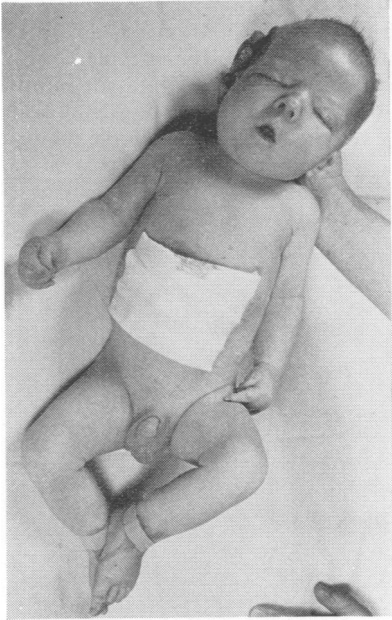


Fig. 1 Case 1 at 6 weeks of age.

On auscultation, a type II systolic murmur was heard over the third left intercostal space. Genitalia were of normal male type, with both testes palpable in the scrotum; no hypospadias was present. Position and function of the anus were normal. There was permanent clenching of hands and fingers with ulnar deviation of the index fingers which over-

crossed the thumbs and middle fingers. A simian crease was found on the right hand. He also showed bilateral talipes equinus and broad dorsiflected big toes.

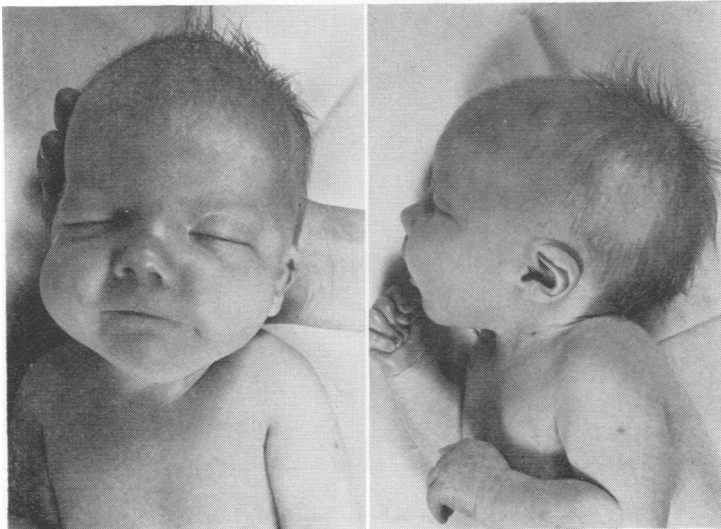
Neurological examination disclosed general muscular hypertonia with opisthotonus, increased tendon reflexes, and diminished control of head position. An electrocardiogram at age 5 weeks showed signs of right ventricular hypertrophy and delayed repolarisation, whereas at 3 months it was normal. Cardiac catheterisation was not performed. Chest and hand x-ray films were normal, and carpal bone age corresponded to the chronological age of 5 weeks.

Skull radiographs confirmed a trigonocephalic head configuration, but were otherwise normal. The following laboratory findings were normal: red and white blood count, platelet count, hepatic enzymes, T4, serum electrolytes, complement-binding reactions for foetal infections (cytomegaly, herpes simplex, rubella, toxoplasmosis, and lues), and urinary-aminoacid screening.

An ophthalmological examination about 1 year later revealed strabismus divergens concomitans o.s. of -15° and bilateral ptosis caused by lack of function of the laevator palpebrae. Both were successfully operated at age 2½ years. Ocular fundi were normal.

Development

Physiotherapy was helpful against spasticity. He was able to sit without support at the age of 11 months and to raise himself at 19 months. At 2½ years of age,



(a)

(b)

Fig. 2a, b Head of case 1 aged 6 weeks. Note high and narrow forehead, antimongoloid position of eyes, small nose with upturned tip, small carp mouth, receding chin, broad, misshapen left ear, clenching of hands and overcrossing of fingers.

his developmental score was estimated to be about 50 (Brunet-Lézine test); he walked with little support and spoke several words.

CASE 2

The female patient is the product of the fourth pregnancy of healthy parents of Southern Italian origin. The father, born in 1944, is a driver, the mother was born in 1945. Family history is unrevealing. A boy born in 1967 (birthweight: 3050 g) and a girl born in 1971 (birthweight: 2950 g) are healthy and normal. The third pregnancy, in 1971, terminated in abortion in about the 12th week. The present gestation was characterised by poor foetal movements which were first noticed by the mother in the 28th week. Birth occurred at term in September 1975, and was normal. The following measurements were obtained: weight 3310 g (50th centile), length 51.5 cm (50th-90th centile), head circumference 35 cm (50th-90th centile), chest circumference 36 cm. The obstetrician noticed 'some dysmorphic signs', namely hypertelorism, ptosis of the right eye, and downturned corners of the mouth. A hoarse and sometimes high-pitched cry was also mentioned. The baby had no respiratory difficulties, and no cyanosis was present. However, she was strikingly quiet and was a very slow drinker. She suffered from repeated upper respiratory tract infections, otitis media, and right side conjunctivitis. Her mental development was

apparently delayed. Between the age of 3 weeks and about 6 months she had Fe-resistant hypochromic anaemia and moderate thrombopenia.

Clinical examination at 1 year 5 months of age (Fig. 3-4) disclosed a physically well-developed, but mentally retarded girl with multiple minor dysmor-

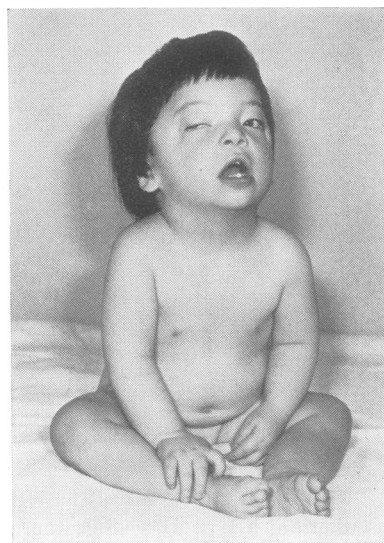


Fig. 3 Case 2 at 17/12 years of age.

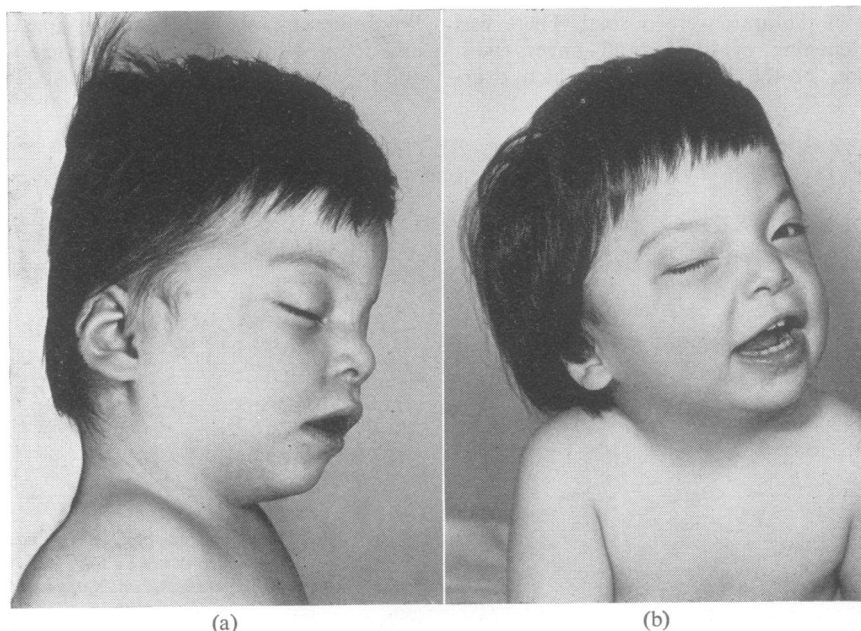


Fig. 4a, b Head of case 2 at 13/12 (a) and 17/12 (b) years of age. Note narrow, prominent forehead, ptosis of right eye, small nose with broad root and upturned tip, carp mouth, small chin, poorly formed right ear, and broad neck.

phic signs. Weight (9.8 kg) and head circumference (46 cm) were 10th to 25th centile, length (78.6 cm) was 25th to 50th centile. Skull shape was marked by a flattened occiput, depressed temples, and a narrow, protruding forehead. The face was asymmetric, with a receding left side. Ocular findings included hypoplastic orbital roots giving the impression of a protrusion of the bulbs, short eyelashes and eyebrows, circular white spots in the iridal stroma, and poor retinal pigmentation, but excluded epicanthic folds, colobomata and microphthalmia. In addition, the right eye presented upward slant of palpebral fissures, ptosis, and a small haemangioma of the upper lid, and divergent strabismus. Bulb movements were unimpaired. ICD was 3.2 cm, palpebral width was 3 cm bilaterally. There was a broad and protruding nasal root, a short bridge and a small, upturned tip. The mouth was small and carp shaped, and the lower lip was everted. The mandible receded moderately. The palate was narrow, but not cleft and the tongue appeared normal. Only the incisors were erupted, and the upper ones were irregularly set. The ears were small (ear length 4/4.2 cm), posteriorly rotated, and exhibited a dysplastic and folded helix, sharp anthelix, hypoplastic tragus, and small lobule. The neck was short and broad but not webbed, and the posterior hair line was low. There was a slight funnel chest with laterally placed nipples. On cardiac auscultation, a 3/6 systolic murmur was audible but liver and spleen were not enlarged, and peripheral pulses were good. The anal opening was anteriorly placed resulting in a very short perineum. Genitalia were unremarkable except for a very small clitoris. Abduction in both hips was moderately

reduced. Cutaneous dimples were found over the knees and over all metacarpo-phalangeal joints. Hands and feet were small, and the distal phalanges and nails of all fingers appeared broad and short without clinodactyly.

Dermatoglyphs

Proposita: bilateral simian creases; palmar configuration: right III H^r t' t^u 3(3), left III^r IV t' 4(2); a-b ridge count right 26, left 31; digital patterns: 8 ulnar loops, 2 whorls, TRC 97. Mother: right transitional simian crease, type I; palmar configuration: right III^r H^t t^u 4(4), left III T^r t t^d 4 (4); a-b ridge count right 31, left 34; digital patterns: 3 ulnar loops, 7 whorls, TRC 213. Father: palmar configuration: right III^r IV H^t t t^u 4(5), left III^r IV^u H^t t t^u 5(5); a-b ridge count: right 27, left 30; digital patterns: 9 ulnar loops, 1 whorl, TRC 100.

Neurological examination

This was normal including a normal muscle tone. She was able to sit without support since the age of 15 months, but she did not raise herself or stand even supported. At 17 months, a Brunet-Lézine test disclosed a developmental age of 7 months for motor co-ordination and of 5 to 6 months for language and social adjustment. A subtle paed-audiometric examination at 12 months disclosed bilateral moderate conductive hearing loss.

Cardiac examinations

An electrocardiogram at 2 and 4 months showed right ventricular hypertrophy which was not visible any longer at 8 months. On chest x-ray films the

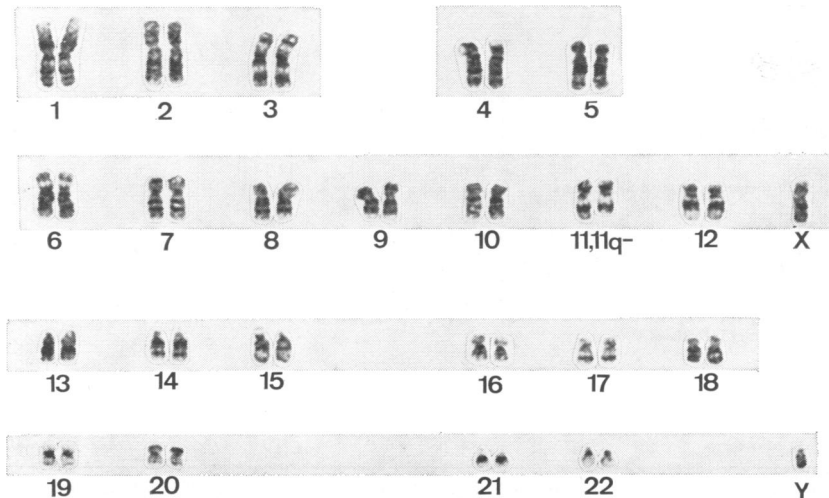


Fig. 5 G-banded karyotype of case 1. 46,XY,del(11)(q23).

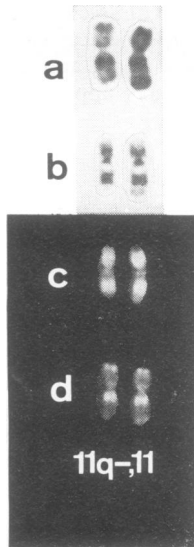


Fig. 6 Chromosomes 11 from mitosis from: (a) case 1, R-banded; (b-d) case 2, G- (b), Q- (c), and R- (d) banded.

heart was enlarged bilaterally initially after birth. With time, this enlargement gradually decreased, and

at 15 months, heart size and lung blood flow were normal. The findings are compatible with either atrial septal defect, ventricular septal defect, aortic, or subaortic stenosis without clinical significance.

Hand x-ray (11 months)

Structurally normal findings, normal bone age.

Haemoglobin electrophoresis

Patient: HbF 0.44%, HbA₂ 2.1%, G6PD 18 U; father: HbF 3.1%, HbA₂ 3.8%, G6PD 27 U; mother: HbF 7.3%, HbA₂ 3.9%, G6PD 26 U. The results indicate heterozygosity for beta-thalassaemia in the patient and her father.

CYTOGENETIC STUDIES

Chromosome analysis was made on cultured lymphocytes from cases 1 and 2 and their parents. In family 1, G-banded (Sperling and Wiesner, 1972) and R-banded (Sehested, 1974) preparations were analysed, and in family 2, G- (Seabright, 1971), Q- (Caspersson *et al.*, 1970), and R- (Dutrillaux *et al.*, 1973) banded preparations. The karyotypes of the propositi showed partial deletion of the long arm of chromosome 11 with the breakpoint at the proximal end of band 11q23: 46,del(11)(q23) (Fig. 5, 6). The parents of both cases had normal chromosomes.

Table Anamnestic and clinical findings in cases with deficiencies of long arm of chromosome 11

	Case 1	Case 2	n=14*	t(11;13)†	del(11)(q14q22)‡
(Mean) maternal age at birth of propositus (years; <i>de novo</i> deletions only)	31	30	27 (12)	22	23
Female sex	—	+	6/12	—	+
(Mean) birthweight (g)	3090	3310	2816 (12)	3350	3420
(Mean) birth length (cm)	47	51.5	—	52	53
Narrow, protruding forehead	+	+	12/12	+	+
Increased inner canthal distance	+	+	9/11	+	+
Ptosis	+	+	7/10	?	?
Epicanthic folds	—	—	5/11	+	?
Antimongoloid position of eyes	+	—	5/14	—	+
Mongoloid position of eyes	—	+	7/14	—	—
Strabismus	+	+	5/8	+	?
Broad nasal root	+	+	12/12	+	+
Short bridge and upturned tip of nose	+	+	11/12	+	+
Carp mouth	+	+	11/11	?	?
Moderately receding chin	+	+	12/14	+	+
Posteriorly rotated, poorly formed ears with prominent anhelices	+	+	10/11	+	+
Shortness of some or all fingers	—	+	5/9	—	—
Simian crease(s)	+	+	6/10	?	+
Abnormal position of feet	+	—	6/14	+	—
Hammer position of big toes	+	—	3/8	+	?
Postnatal ± prenatal growth retardation	—	—	8/13	—	—
Severe mental retardation	+	+	11/11	?	+
Repeated upper respiratory tract infections	?	+	6/8	?	?
Coloboma of iris	—	—	2/14	—	—
Congenital heart defect	?	?	4/12	—	+
Pyloric stenosis	+	—	2/12	—	—
Inguinal hernia	+	—	2/11	+	—
Hypospadias	—	0	1/3	—	0
Cryptorchidism	—	0	0/3	—	0

*Jacobsen *et al.* (1973); Linarelli *et al.* (1975); Turleau *et al.* (1975); Engel *et al.* (1976); Larson *et al.* (1976); Bresson and Noir (1977); Cassidy *et al.* (1977); Frank and Riccardi (1977); Mulcahy and Jenkyn (1977); Zabel *et al.* (1977); 2 cases of the present report.

†Fonatsch *et al.* (1975).

‡Taillemite *et al.* (1975).

Discussion

After Jacobsen *et al.* (1973) had presented the initial report, further descriptions of the 11q- syndrome followed within short periods (see Table 1) so that it now seems that this chromosome deletion syndrome might not be as rare as its late discovery would indicate. At least 2 cases were found through re-examination with banding techniques of patients whose orcein-stained karyotypes had been interpreted as normal in the prebanding area (Linarelli *et al.*, 1975; Larson *et al.*, 1976). If banded karyotypes are not of good quality, the aberration could still escape the observer.

Anamnestic and clinical findings of the 12 patients whose clinical findings were described in detail are listed in the Table. In most of the cases the breakpoint was determined at 11q23 (Jacobsen *et al.*, 1973; Turleau *et al.*, 1975; Engel *et al.*, 1976; Larson *et al.*, 1976; Bresson and Noir, 1977; Cassidy *et al.*, 1977; Frank and Riccardi, 1977; Mulcahy and Jenkyn, 1977; the two cases of the present report). In the patient of Linarelli *et al.* (1975), the breakpoint was defined at 11q22, however, the karyotype shows that at least the majority of the band 11q22 is present in the deleted chromosome, and thus the situation is similar to those of the other patients. In the case of Fonatsch *et al.* (1975) who had a *de novo* translocation between chromosome 13 and the long arm of chromosome 11, the authors were unable to determine the breakpoint in 11q; they assumed mainly a deficiency of the centromeric region of chromosome 13 with the breakpoint at 13q12. However, the clinical picture makes a deficiency of the distal segment of 11q very probable. Re-examination of this case using several banding techniques including C-banding could perhaps solve the problem. Finally, in Taillemite *et al.*'s (1975) case an interstitial deletion of the bands 11q14-11q22 was inferred from R-banded karyotypes.

The unusual combination of trigonocephaly with a prominent forehead, ptosis of the upper lids, a stubby, upturned nose with a broad, depressed root, and carp mouth in a retarded child leads one to suspect the 11q- syndrome. Subsequently, one can perform a chromosome analysis and a thorough clinical examination in order to detect minor signs apparent with this syndrome (see Table): hypertelorism, mongoloid or antimongoloid position of the eyes, small chin, and a rather consistent ear dysmorphia (small and broad, posteriorly rotated earlobes with prominent anthelices, hypoplastic helices and lobules); simian creases, hammer position of big toes, and, sometimes, hypoplastic terminal phalanges of fingers. Major malformations were comparatively rare and mainly concerned

congenital heart defects (about one-third of the cases). Of 13 cases 2 had pyloric stenosis which is otherwise very uncommon in autosomal chromosome aberrations, and of 14 cases, 3 had inguinal hernias. Further findings in single cases were iridal colobomata (Linarelli *et al.*, 1975; Zabel *et al.*, 1977), deafness (Linarelli *et al.*, 1975; Mulcahy and Jenkyn, 1977) and hypospadias (Turleau *et al.*, 1975).

Mean maternal age of cases with *de novo* deletions (27 years, $n = 12$) does not differ from the average; there is, so far, a preponderance of females (about 2/3) similar to many other autosomal chromosome aberrations, for example the 18p- and 5p- syndromes (Schinzel, 1976). As to pre- and postnatal growth, we can distinguish two subgroups: more than half of the cases have an average birthweight (over 3000 g: Engel *et al.*, 1976; Larson *et al.*, 1976; Cassidy *et al.*, 1977; Frank and Riccardi, 1977; the 2 cases of the present report), whereas the others were born moderately to severely underweight (birthweight between 1700 and 2350 g: Jacobsen *et al.*, 1973; Linarelli *et al.*, 1975; Turleau *et al.*, 1975). Mean birthweight (2816 g, $n = 12$) is clearly reduced. Postnatal growth was retarded in about half of the cases including all who were already small for date. Both cases of the present report were born more weighty than their normal sibs and showed a normal early postnatal growth and normal bone development. A tendency to upper respiratory tract infections as commonly found in autosomal chromosome aberrations was noticed in the majority of cases who survived the first year.

Mental retardation was found in all but one patient (Fonatsch *et al.*, 1975), but the latter was too young for a reliable assessment. In about half of the cases, mental retardation is of low imbecility grade, and the language is particularly impaired (Engel *et al.*, 1976; case 2 of the present report). The others, mostly those who also showed growth retardation, were in the range of idiocy. The breakpoint was similar in all those cases. The two familial cases of Jacobsen *et al.* (1973) were physically most severely affected and died early after birth. Both the clinical picture of these two patients and the breakpoints in the balanced translocation carriers allow us to exclude a duplication deficiency with a larger monosomic segment on 11q plus partial trisomy of the long arm of chromosome 21.

Faust *et al.* (1974) presented a case with a deletion at 11q21. In this 9-year-old girl, mental retardation was reported to be of a mild degree except for a severe delay in language. A description of dysmorphic signs was not given; however, it was also not stated that no dysmorphic signs were present. In the light of the 11 cases with a deletion at 11q23 it seems improbable that a larger deficiency, if it was viable at all,

would not be connected with severe mental retardation and at least some of the signs found in most of the other cases. Therefore, clinical and cytogenetic re-examination of this case would be worth while.

It is surprising that the patient described by Taillemite *et al.* (1975), whose karyotype lacked the interstitial segment 11q14-q22, showed so many features common to the cases with terminal deletions (see Table) though there is no overlap of the monosomic segments. Generally, it seems justified to assume that deficiencies of different autosomal segments cause different dysmorphic patterns and, indeed, Francke *et al.* (1977) recently described a patient with an interstitial deletion of the proximal segment of 4p(p11-p15.2) whose clinical picture was clearly different from the usual 4p- syndrome.

The haemoglobin findings in case 2 and her parents probably allow us to exclude localisation of a major structural gene for haemoglobin synthesis on the distal segment of 11q. From cases with unbalanced translocations involving the long arm of chromosome 4 there is some evidence that one such gene is located on the long arm of chromosome 4 (Gandini *et al.*, 1977).

The authors thank Dr H. König (Berne) for ophthalmological examinations of case 1. Professor Dr A. Fanconi and Dr A. Tschumi (Winterthur) for referring case 2, Professor Dr H. R. Marti (Aarau) for determination of foetal haemoglobins in family 2, and Ms Sieglinde Hajdn, Claudia Bielmann, and Regula Zellweger for their skilful technical assistance in the laboratory works.

References

- Bresson, J. L., and Noir, A. (1977). Monosomie partielle 11q. Une nouvelle observation. *Annales de Génétique*, **20**, 63-66.
- Caspersson, T., Zech, L., and Johansson, C. (1970). Analysis of the human metaphase chromosome set by aid of DNA-binding fluorescent agents. *Experimental Cell Research*, **82**, 490-492.
- Cassidy, S. B., Heller, R. M., Kilroy, A. W., McKelvey, W., and Engel, E. (1977). Trigenocephaly and the 11q-syndrome. *Annales de Génétique*, **20**, 67-69.
- Dutrillaux, B., Laurent, C., Couturier, J., and Lejeune, J. (1973). Coloration des chromosomes humains par l'acridine orange après traitement par le 5 bromodéoxyuridine. *Comptes Rendus Hebdomadaires des Séances de l'Académie des Sciences; D: Sciences Naturelles (Paris)*, **276**, 3179-3181.
- Engel, E., Hirschberg, C. S., Cassidy, S. B., and McGee, B. J. (1976). Chromosome 11 long arm partial deletion: a new syndrome. *American Journal of Mental Deficiency*, **80**, 473-475.
- Faust, J., Vogel, W., and Löning, B. (1974). A case with 46, XX, del(11)(q21). *Clinical Genetics*, **6**, 90-97.
- Fonatsch, C., Flatz, S., and Stendel, A. (1975). De novo (11; 13) translocation. *Humangenetik*, **28**, 87-91.
- Francke, U., Arias, D. E., and Nyhan, W. L. (1977). Proximal 4p- deletion. *Journal of Pediatrics*, **90**, 250-252.
- Frank, J., and Riccardi, V. M. (1977). The 11q- syndrome. *Human Genetics*, **35**, 241-246.
- Gandini, E., Dallapiccola, B., Laurent, C., Suerinc, E. F., Forabosco, A., Conconi, F., and del Senno, L. (1977). Evidence for localisation of genes for human α -globin on the long arm of chromosome 4. *Nature (London)*, **265**, 65-66.
- Jacobsen, P., Hauge, M., Henningsen, K., Hobolt, N., Mikkelsen, M., and Philip, J. (1973). An (11; 21) translocation in four generations with chromosome 11 abnormalities in the offspring. *Human Heredity*, **23**, 568-585.
- Larson, S. A., Yeatman, G. W., and Riccardi, V. M. (1976). Deletion of 11q: report of two cases and a review. *Birth Defects: Original Article Series*, Volume XII, Number 5, 125-130.
- Linarelli, L. G., Pai, K. G., Pan, S. F., and Rubin, H. M. (1975). Anomalies associated with partial deletion of long arm of chromosome 11. *Journal of Pediatrics*, **86**, 750-752.
- Mulcahy, M. T., and Jenkyn, J. (1977). The 11q- syndrome: another case report. *Human Genetics*, **36**, 239-242.
- Schinzel, A. (1976). Autosomal chromosome aberrations. A review of the clinical syndromes caused by structural chromosome aberrations, mosaic-trisomies 8 and 9, and triploidy. *Ergebnisse der inneren Medizin und Kinderheilkunde*, **38**, 37-94.
- Seabright, M. (1971). A rapid banding technique for human chromosomes. *Lancet*, **2**, 971-972.
- Sehested, J. (1974). A simple method for R-banding of human chromosomes, showing a pH-dependent connection between R and G bands. *Humangenetik*, **21**, 55-58.
- Sperling, K., and Wiesner, R. (1972). A rapid banding technique for routine use in human and comparative cytogenetics. *Humangenetik*, **15**, 349-353.
- Taillemite, J. L., Baheux-Morlier, G., and Roux, Ch. (1975). Délétion interstitielle du bras long d'un chromosome 11. *Annales de Génétique*, **18**, 61-63.
- Turleau, C., Chavin-Colin, F., Roubin, M., Thomas, D., and de Grouchy, J. (1975). Monosomie partielle 11q et trigonocephalie. Un nouveau syndrome. *Annales de Génétique*, **18**, 257-260.
- Zabel, B., Hansen, S., Hillig, U., and Gröting-Imhof, H. (1977). A girl with partial long-arm deletion of chromosome 11 and familial pericentric inversion of chromosome 9. *Human Genetics*, **36**, 117-122.

Requests for reprints to Dr A. Schinzel, Abteilung für Medizinische Genetik, Univ.-Kinderklinik Zürich, Steinwiesstr. 75, CH-8032 Zürich, Switzerland.