

Recessively inherited costovertebral segmentation defect with mesomelia and peculiar facies (Covesdem syndrome)

A new genetic entity?

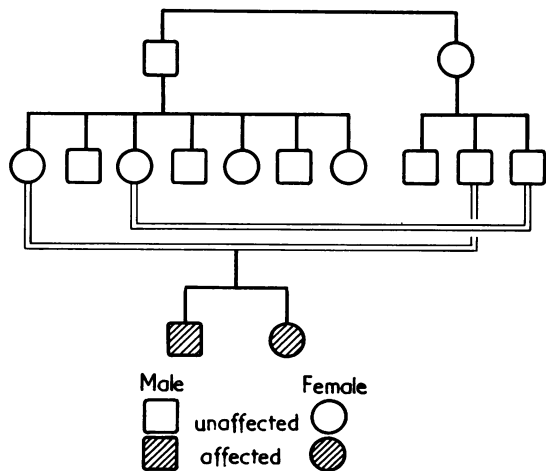
R. S. WADIA, D. B. SHIROLE, AND M. S. DIKSHIT

From the Department of Genetics and Radiology, Ruby Hall Clinic, Poona, India

SUMMARY Two sibs of a consanguineous mating are described. Both have a gross costovertebral segmentation defect affecting nearly all the thoracic vertebrae, and mesomelia of the limbs, with the upper limbs being obviously more affected than the lower. The facial appearances of the two are identical, with hypertelorism, depressed nasal bridge, large bony upper lip, constantly open mouth, and peg-like teeth. We believe this combination has not been described before and represents the effect of a 'new' recessive gene. We would like to name this combination Covesdem syndrome (costovertebral segmentation defect with mesomelia).

Defects in segmentation of vertebrae and associated rib anomalies have been described on several occasions. Rimoin *et al.* (1968) and Van Der Sar (1952) described a dominant form associated with short trunked dwarfism. A similar recessive form has also been described (Jarcho and Levin, 1938; Lavy *et al.*, 1966; Caffey, 1967). The recessive form appears more severe and most cases have died within the first year of life. In both forms the skeleton is otherwise normal. A number of other Mendelising disorders may also occasionally show mild defects in vertebral segmentation (Rimoin *et al.*, 1968). We are describing here two sibs of a consanguineous mating who showed gross costovertebral segmentation defects associated in both with mesomelic shortening of the limbs most pronounced in the upper limbs and associated with thick curved irregular radius and ulna bilaterally and a peculiar facies. We believe this combination of abnormalities has not been described before.

interest is that a paternal sib has married the mother's sister. There are no children from this mating yet.



Case reports

Fig. 1 shows the family tree. The two affected children are the product of a first cousin mating. Of

Received for publication 18 April 1977

Fig. 1 Pedigree.

Case 1

A boy aged 9 years was born of a normal delivery and pregnancy, birthweight 2947 g. The mother had not received any significant drugs in pregnancy. At age 4 months normal milestones were noted, together with abnormal facies and upper limbs. The height at 4 months was 55 cm (Indian mean at 3 months 62.7 ± 4.01 cm: Indian Council of Medical Research, 1971). The skull was 40 cm (Indian mean at 3 months 40.6). At 2 years and 8 months the height was 82 cm (25th centile) and the lower segment was 36 cm. The child attended school normally and was above average in class. His main problem was a deformity of both upper limbs and an inability to pronate the arm or fully extend the elbow. There were also problems arising from a mild abnormality of the genitalia and these are to be treated surgically.

On examination the skull circumference was 49 cm and the height 115 cm (50th centile, Indian Council of Medical Research, 1971). The span was 97 cm, and the lower segment was 59 cm.

The facies was unusual, with well-marked hyper-telorism and depressed bridge of nose, a large upper lip, constantly open mouth, and irregular peg-like teeth, with considerable caries.

The upper limbs were short with most pronounced shortness in the forearm segment where the bones appeared abnormally large and formed an irregular bulge. There was limitation of pronation and he could not fully extend the elbow. The fingers were short and stubby and there was 5th finger bilateral camptodactyly. The lower limbs appeared clinically unremarkable, and the child could run and play normally.

The genitalia were small. The penis was buried in the scrotum but could be elongated to about half an inch in length. The urethra was normally sited. The scrotum was fused to the perineum. The dermatoglyphs of the palm appear unremarkable. In the digits there are ulnar loops on both thumbs and whorls on the remaining fingers.

RADIOLOGICAL EXAMINATION

Costovertebral abnormality

X-rays of the spine disclosed hemivertebrae or butterfly vertebrae affecting T2, 3, 4, 5, and 9, 10, 11, 12th vertebra. The 9th, 10th, and 11th left ribs were fused at the vertebral ends and the 4th and 5th ribs were fused at the vertebral ends. Only 3 segments of the sacrum were seen (Fig. 2).

Limb abnormalities

At age 4 months there was distinct bowing of the lower limbs with broadening of the metaphysis at ends of femur and tibia (Fig. 3). In the upper limbs, a short

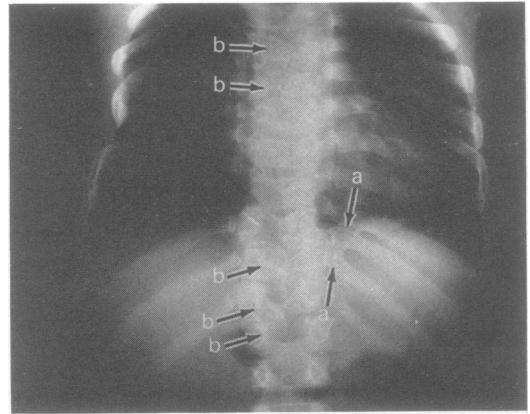


Fig. 2 X-ray film of dorsal spine and ribs of case 1. Fused 3 lower ribs on left side (a) and multiple non-fused vertebral bodies (b).

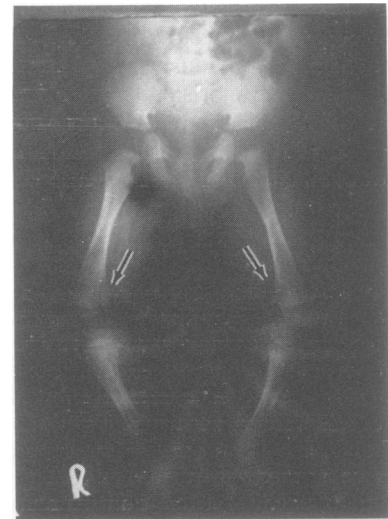

Fig. 3. X-ray film of pelvis and both lower extremities of case 1 (age 4 months), showing bowing of both legs, with broadening of distal shafts of both femora with osteoporosis (arrow).

radius and ulna with deformed upper ends of both radii were noted. The humerus appeared normal (Fig. 4a).

At age 8 years the lower limbs appeared normal. The ratio of femur to tibia on x-ray film was 30:24 cm. In the upper limbs, the ulna was short and deformed, especially at the lower ends on both sides. The radius was short with deformed upper ends. The lower end of the humerus was oblique and deformed (Fig. 4).

The skull and facial bones showed no abnormality.

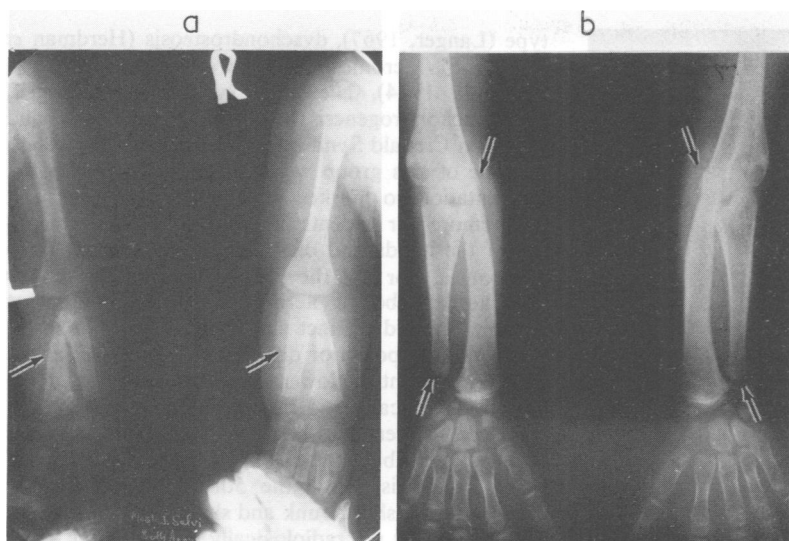


Fig. 4 (a) X-ray film of arms case 1 at age 4 months: short, stout, deformed radius and ulna on both sides. (b) Age 7 years. Deformed radius and ulna on both sides (distal ulnar ends and proximal radial ends show maximal abnormality). Distal humerus shows secondary abnormalities.

Case 2

A 5-year-old girl had been seen first just after birth with similar forearm abnormalities. Like the elder sib there was no history of any problems in pregnancy or in the perinatal period. When seen last at age 5 years she was 88 cm in height (below the 5th centile by Indian standards: Indian Council of Medical Research, 1971) and the span was 77 cm. The lower segment was 43 cm. She had identical facies, with depressed nasal bridge, large bony upper lips, constantly open mouth, and peg teeth. Less caries was noted than in her brother. The lower limbs showed talipes deformity on the right but were otherwise apparently normal. The upper limbs were noted to be identical with those of her brother, with short irregular distal segments, prominence of the ulna, and stubby fingers with bilateral 5th finger camptodactyly. Pronation was limited and extension at the elbow was incomplete.

The child's progress at school has been normal; and there are no abnormalities of the genitalia.

RADIOLOGICAL FINDINGS

Costovertebral change

X-ray film of the spine showed a butterfly vertebra at T2. T3 and T4 were fused and showed hemivertebra. There was similar fusion and hemivertebra of T7 and 8, T9 and 10, T11 and T12, with pronounced scoliosis to the right. There were only 8 clear pedicles on the left side and 10 on the right. There were only 10 ribs on the left side and 12 ribs on the right with fusion of vertebral ends of the 10th and 11th and 3rd and 4th ribs on the right side (Fig. 5).

Limb changes

The lower limbs were normal except for talipes on the right side. The upper limbs showed bilateral similar abnormalities to those in the boy, with a deformed oblique lower end of the humerus, short radius and ulna with deformities at both ends, especially distinct at the upper ends of radius and lower ends of the ulna. The hand and digits were normal. The skull and facial bones showed no abnormality.

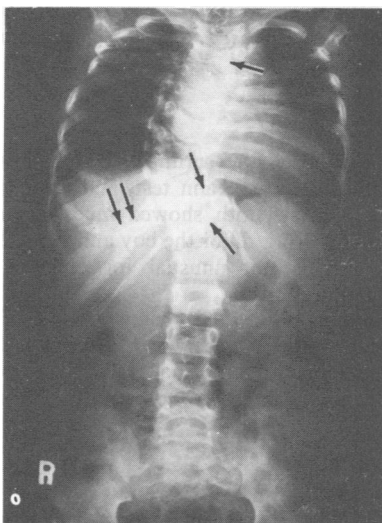


Fig. 5 X-ray film of spine of case 2. Hemivertebrae noted at 2nd and 10th thoracic (single arrows). There is pronounced scoliosis, fused right lower ribs (double arrows), and only 10 ribs on right side and anomalous vertebra.

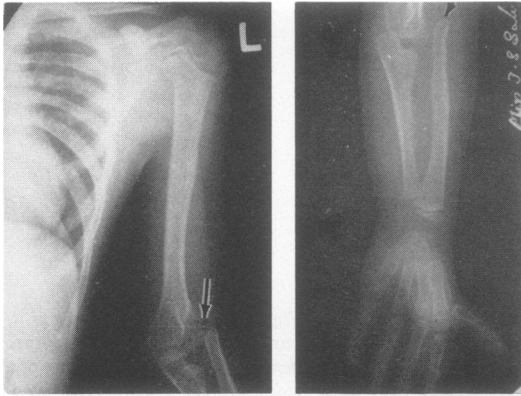


Fig. 6 X-ray films of upper limb of case 2. Deformed proximal end of radius with dislocation (a).

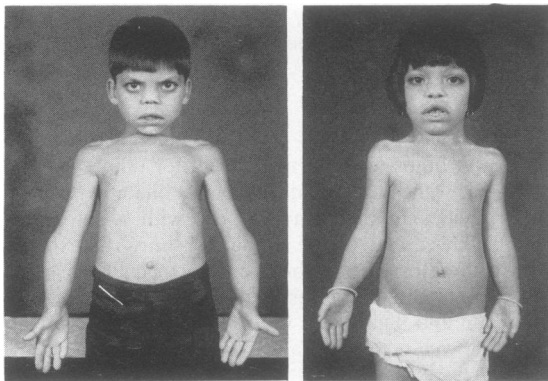

Fig. 7 Photograph of case 1, Fig. 8 Photograph of case 2. showing typical facies and arm abnormality.

In both children the serum calcium, phosphorus, alkaline phosphatase, Kahn test, and urine examination were normal. Both showed mild anaemia with haemoglobin 10.6 g/dl for the boy and 9.8 g/dl for the girl, but this is not unusual for children in this socioeconomic status.

The parents were noted clinically to be of normal height (father 160 cm, mother 150 cm). All spinal movements in both are normal. The father's vertebral x-ray films are normal. The mother refused x-rays.

Discussion

Mesomelia is a non-specific term which refers to shortening most striking in the forearms and lower legs. This feature is described in a number of disorders (Carter and Fairbank, 1974), e.g. mesomelic dwarfism of the hypoplastic ulna fibula and mandible

type (Langer, 1967), dyschondrosteosis (Herdman *et al.*, 1966), acromesomelic dwarfism (Carter and Fairbank, 1974), Nievergelt syndrome (Nievergelt, 1964), achondrogenesis (Quelle-Salgado, 1964), and Ellis Van Crevald Syndrome (McKusick *et al.*, 1964). In none of this group were defects in costovertebral segmentation so marked as those in our cases, and furthermore our patients did not have any abnormalities of the hands and digits as seen in the last three syndromes, nor did they have abnormalities of the skull as described in acromesomelic dwarfism. Our children showed distinct shortening of the forearms. There was no posterior dislocation of the ulna at the wrist. At present the lower limbs appear normal in the boy, both clinically and radiologically, but at the age of 4 months there was broadening of the metaphyses of femur and tibia. The girl has a talipes deformity of the foot and is below the 5th centile presumably because of the short trunk and shortened lower limbs. The long bones are radiologically normal in the lower limbs.

The second feature of this syndrome is the costovertebral segmentation defect which is very severe in the thoracic part of the column and involves practically all vertebrae with butterfly vertebrae, hemivertebra and vertebral fusion. Both parents are of normal height and do not show clinical abnormalities of the spine or ribs. As mentioned before, both a dominant and recessive form of spondylocostal dysplasia are described and the recessive form is in most cases rapidly fatal. Neither form shows limb anomalies. Defects in segmentation of vertebrae of the type described have also been mentioned in Goldenhar's syndrome (Gorlin and Pindborg, 1964), Larsen's syndrome (Larsen *et al.*, 1950), basal cell naevus syndrome (Berlin *et al.*, 1966), incontinentia pigmenti (Haber, 1952), oculovertebral syndrome (Weyers and Thier, 1958), and lateral facial cleft syndrome (Gorlin and Pindborg, 1964), but in all these syndromes the segmentation defect involves only scattered vertebrae and another core anomaly is present not seen in our cases. The facies is a little similar to that described in Larsen's syndrome which may rarely have the costovertebral segmentation defect but has multiple joint dislocation as a basic anomaly and no mesomelia. We believe that this constellation of signs has not been described before. It is possible that the children are both coincidentally suffering from 2 rare recessive disorders, i.e. recessive costovertebral segmentation defect (which is milder than usual) and recessive mesomelic dwarfism (which is also not typical of the form described by Langer (1967). Such a coincidence would require the almost identical facies to be separately explained, and we prefer to think of the entire constellation as being the result of a single recessive gene.

References

- Berlin, N. I., Van Scott, E. J., Clendenning, W. E., Archard, H. D. Block, J. B., Witkop, C. J., and Haynes, H. A. (1966). Basal cell nevus syndrome. *Annals of Internal medicine*, **64**, 403-421.
- Caffey, J. (1967). *Pediatric X-ray Diagnosis*, 5th ed., p. 1109. Year Book Medical Publishers, Chicago.
- Carter, C. O., and Fairbank, T. J. (1974). Localized abnormalities in limbs. In *The Genetics of Locomotor Disorders*, p. 74. Oxford University Press, London.
- Gorlin, R. J., and Pindborg, J. J. (1964). *Syndromes of the Head and Neck*. McGraw-Hill, New York.
- Haber, H. (1952). The Bloch Sulzerberger syndrome (incontinentia pigmenti). *British Journal of Dermatology*, **64**, 129-140.
- Herdman, R. C., Langer, L. O., and Good, R. A. (1966). Dyschondrosteosis. The most common cause of Madelung's deformity. *Journal of Pediatrics*, **68**, 432-441.
- Indian Council of Medical Research (1971). *Report on Growth and Physical Development of Indian Infants and Children*. ICMR Reports.
- Jarcho, S., and Levin, P. M. (1938). Hereditary malformations of the vertebral bodies. *Bulletin of the Johns Hopkins Hospital*, **62**, 216-226.
- Langer, L. O., Jr. (1967). Mesomelic dwarfism of the hypoplastic ulna, fibula, mandible type. *Radiology*, **89**, 654-660.
- Larsen, L. J., Scottstaedt, E. R., and Best, F. C. (1950). Multiple congenital dislocations associated with characteristic facial abnormality. *Journal of Pediatrics*, **37**, 574-581.
- Lavy, N. W., Palmer, C. G., and Merritt, A. D. (1966). A syndrome of bizarre vertebral anomalies. *Journal of Pediatrics*, **69**, 1121-1125.
- McKusick, V. A., Egelund, J. A., Eldridge, R., and Krusen, D. E. (1964). Dwarfism in the amish 1. The Ellis van Creveld syndrome. *Bulletin of the Johns Hopkins Hospital*, **115**, 306-336.
- Nievergelt, K. (1964). Cited by McKusick (1974).
- Quelle-Salgado, A. (1964). A new type of dwarfism with various bone aplasias and hypoplasia of the extremities. *Acta Genetica et Statistica Medica*, **14**, 63-66.
- Rimoin, D. L., Fletcher, B. D., and McKusick, V. A. (1968). Spondylocostal dysplasia. A dominantly inherited form of short trunked dwarfism. *American Journal of Medicine*, **45**, 948-953.
- Van Der Sar, A. (1952). Hereditary multiple hemivertebrae. Cited by Rimoin *et al.* (1968).
- Weyers, H., and Thier, C. V. (1958). Malformations mandibulo-faciales et delimitation d'un 'syndrome oculo-vertebral'. *Journal de Génétique Humaine*, **7**, 143. Cited by Rimoin *et al.* (1968).

Requests for reprints to Dr R. S. Wadia, Department of Medicine and Neurology, Poona Medical Foundation, Ruby Hall Clinic, 40 Sassoon Road, Poona 411001, India.