

Familial atypical multiple mole-melanoma syndrome

HENRY T. LYNCH, BERT C. FRICHOT, III, AND JANE F. LYNCH

From the Department of Preventive Medicine/Public Health, Creighton University, Omaha, Nebraska; and the Departments of Dermatology and Preventive Medicine/Public Health, Creighton and Nebraska University Health Foundation, Omaha Veterans Administration Hospital, Omaha, Nebraska, USA

SUMMARY A family is described showing concordance for malignant melanoma and a cutaneous phenotype characterised by multiple large moles of variable size and colour (reddish-brown to bright red) with pigmentary leakage. Transmission of the cutaneous phenotype in the subject family, and in several others currently under investigation, shows an inheritance pattern consistent with a simple autosomal dominant factor. This cutaneous phenotype signifying melanoma risk may now be added to an increasing body of knowledge dealing with cancer-related genodermatoses.

Cawley (1951) described cutaneous malignant melanoma (CMM) in a father and 2 of his 3 children. Since this initial report there has been a sufficient number of melanoma-prone families identified (Lynch *et al.*, 1975) to establish an hereditary aetiology for at least a small proportion (approximately 3%) (Anderson, 1971) of all occurrences of this disease. When families are extended and scrupulous consideration is given to all histological varieties of cancer, certain tumour associations, for example, carcinoma of breast, gastrointestinal tract, sarcoma, and lymphoreticular malignancies, appear in a familial context in certain melanoma-prone families (Fraser *et al.*, 1971; Lynch, 1972, 1976; Lynch *et al.*, 1975). Indeed, melanoma has also been found to be associated with Mendelian inherited disorders with cutaneous markers, including xeroderma pigmentosum (Lynch *et al.*, 1967), and von Recklinghausen's neurofibromatosis (Gartner, 1940), as well as with the congenital form of giant pigmented naevus (Lynch, 1976). These observations are consistent with genetic heterogeneity (Fraser *et al.*, 1971; Lynch, 1972, 1976; Lynch *et al.*, 1975).

The purpose of this report is to describe a newly recognised cutaneous phenotype characterised by multiple large moles of variable size and colour (reddish-brown to bright red), with pigmentary leakage, associated with familial cutaneous malignant melanoma (CMM).

Results

The proband (Fig. 1; IV.4) was a 36-year-old white man, who had a past history of 7 separate primary

CMMs. He and his melanoma-prone relatives were initially investigated by Lynch and Krush a decade ago (Lynch and Krush, 1968). The Table shows anatomical site and age of onset of CMM, in addition to the associated cutaneous phenotype in the proband and his relatives.

Physical examination of the proband in March 1977 showed a well-nourished, well-developed individual who was a former competitive high school and collegiate swimmer. He did not begin any form of protection of his skin from sunlight until about 15 years ago and this only included minimal protection with a sunscreen. He had red hair, blue eyes, and his light skin was characterised by multiple freckles and moles over all surface areas, with greatest prominence on the skin of the back and abdomen (Fig. 2). The freckling pattern was extensive in sun-exposed areas. There were approximately 300 moles of variable size (2 mm to 2 cm) and colour (brown, pink, and red). Borders of many of these moles were irregular and showed evidence of pigment leakage.

The proband's 6-year-old daughter (Fig. 1; V.1) and his 3-year-old son (Fig. 1; V.2) showed no evidence of atypical moles.

His 34-year-old sister (Fig. 1; IV.5) developed separate primary malignant melanomas (histologically verified) of the skin at ages 31, 32, and 33. Examination of her skin showed freckling and multiple moles (approximately 400), some of which were atypical, similar to her brother, the proband. During our physical examination of this patient we observed a very atypical mole (Fig. 3). The pigmented (red to brown) naevus component measured 0.4 cm. There was a red and white inflammatory portion which

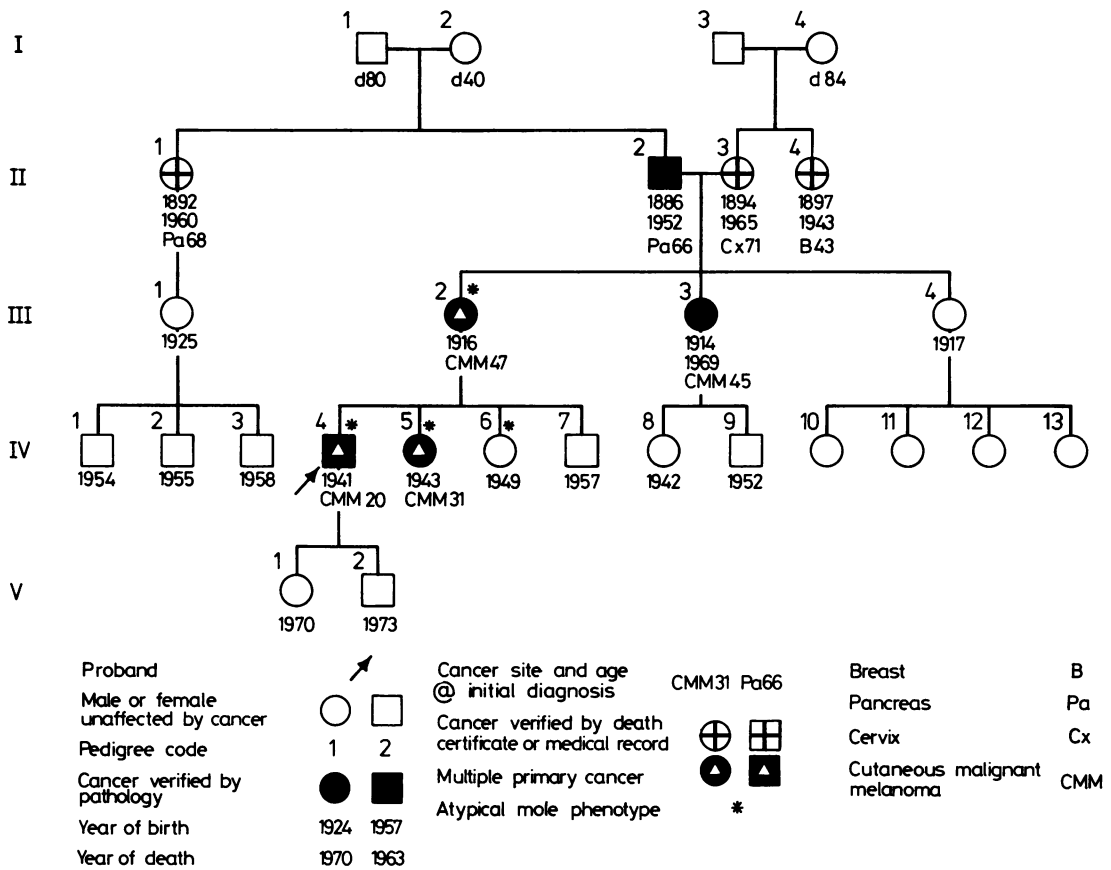


Fig. 1 Pedigree of family prone to malignant melanoma and multiple atypical moles.

Table Registry of melanoma and cutaneous phenotypes

Pedigree no.	Age	Age of onset	Anatomical site (histological verification)	Atypical moles	Excessive moles (200 or more)	Comments
III.2	60	47 56	Abdomen Back	**Yes	Yes	Good health
III.3	d 55	45	Back	**Yes	Yes	Died of CMM
IV.4	36	20 21 22 24 25 26 36	Left arm Right costal margin Left lateral malleolus Right arm Mid-back *	Yes	Yes	7 CMM Diagnosed by HTL 40 biopsies in 10 years with 2 CMM
IV.5	34	31 32 33 34	Right wrist Right elbow Leg Back	Yes	Yes	4 CMM
IV.6	28	—		**Yes	Yes	No CMM
IV.7	20	—		?	Yes	No CMM
V.1	6			?	No	
V.2	3			No	No	

* CMM—site unknown

** History from patient or relative

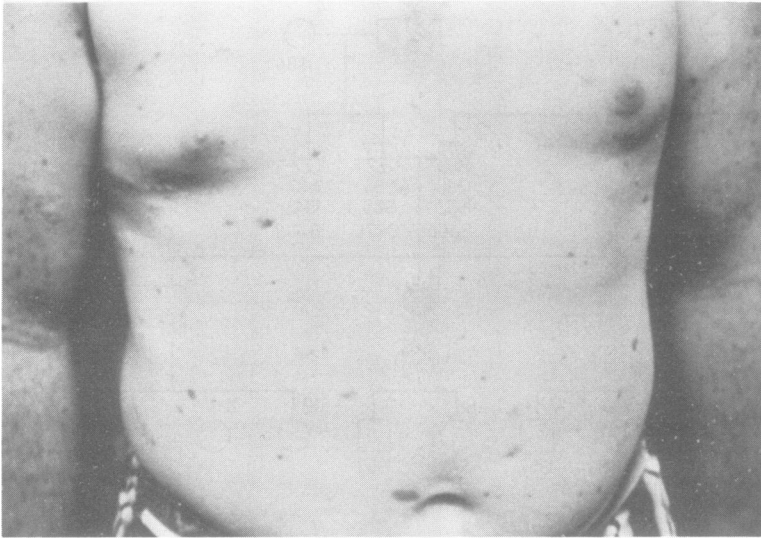


Fig. 2 Skin of abdomen of the proband showing numerous moles, several of which are atypical, particularly in the periumbilical area.

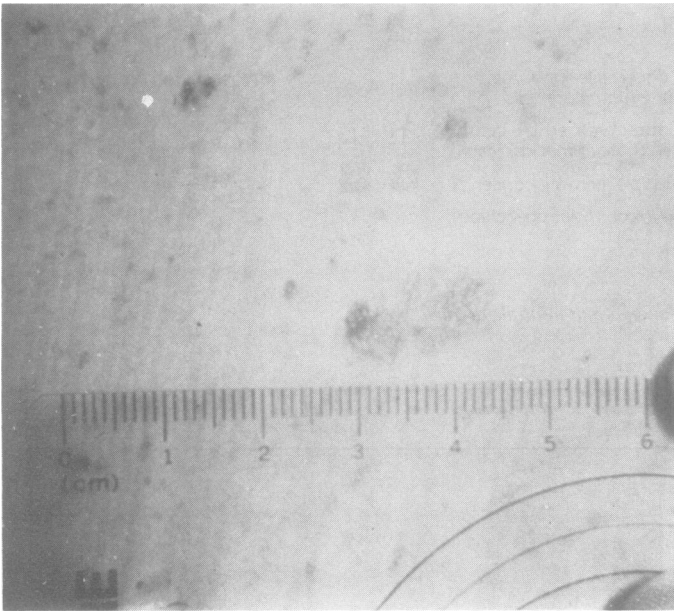


Fig. 3 An atypical mole on the skin of the back of the proband's sister. Note the pigmented area which was red to brown and an inflammatory component extending approximately 1.4 × 0.7 cm. This lesion was subsequently excised and the histological diagnosis was superficial spreading malignant melanoma.

measured approximately 1.4 × 0.7 cm. The lesion was excised by her physician and histologically was a superficial spreading malignant melanoma, her fourth separate primary malignant melanoma.

A second sister (Fig. 1; IV.6), aged 27, was not examined by us, but the history revealed her to have a skin phenotype identical to that of the proband. However, she has not yet developed malignant melanoma. A brother (Fig. 1; IV.7), aged 20, had skin showing multiple moles, none of which were atypical.

The proband's mother (Fig. 1; III.2) had malignant melanoma (histologically verified) at ages 47 and 56. She is now aged 60 and in good health. Our examination of her skin revealed multiple moles, but none were atypical. However, she has had many moles surgically excised, some of which were atypical by historical description. Her sister (Fig. 1; III.3) developed malignant melanoma at age 45 (histologically verified) and died at age 55. No description of her skin was available. It is also of

interest that the proband's maternal grandmother (Fig. 1; II.3) had cervical cancer, a maternal aunt (Fig. 1; II.4) had carcinoma of the breast, and the paternal grandfather (Fig. 1; II.2) had pancreatic cancer, as did the paternal great-aunt (Fig. 1; II.1). Characterisation of the skin of these individuals was not available to us.

Discussion

Malignant melanoma has shown a recent marked increase in incidence in several areas of the world (Doll, 1977) commensurate with changing life-patterns of man, and possibly resulting from his increased exposure to solar radiation. It is not known to what extent familial factors are contributory to the overall melanoma increase, though certainly they must play an important aetiological role as evidenced by an excess of melanoma in those patients with Celtic ancestry, fair complexion, and blue eyes (Kopf and Bart, 1977).

The observation of malignant melanoma in association with a distinguishing cutaneous phenotype characterised by multiple large moles, irregular in shape, coloured reddish-brown to pink, with evidence of pigmentary leakage, and with an apparent autosomal dominant mode of inheritance, may constitute a new familial melanoma syndrome.

This cutaneous phenotype in familial association with CMM was recently described verbally by Clark (1976). Simultaneously, we have verified this finding (Frichot *et al.*, 1977). We are also investigating an additional melanoma-prone family, where concordance of CMM and the phenotype was observed in a 36-year-old mother and her 19-year old daughter (Frichot *et al.*, 1977). Interestingly, we had biopsied a portion of a suspicious mole which was large, red, and had an irregular border with pigment leakage, located on the lower left back of this daughter at age 16. The finding was an intradermal naevus with junctional activity; this same mole underwent malignant transformation to malignant melanoma 2 years later (histologically verified, Clark's Level 4). W. H. Clark (1977, personal communication) observed similar malignant transformation in a mole on one of his patients with the syndrome.

Clark's patient, those in the subject family, and our additional mentioned family (Frichot *et al.*, 1977), each of which show direct transmission of the cutaneous phenotype and/or CMM from parent to progeny, and equal sex distribution, are consistent with a simple dominant inheritance pattern as an aetiological explanation for this syndrome. We suggest that this disorder be named the 'Familial Atypical Multiple Mole-Melanoma Syndrome', the acronym

being FAMMM syndrome. We urge that all occurrences of familial melanoma be reassessed in the light of this cutaneous phenotype, since its recognition could signify individuals at high cancer risk. Until the natural history of this syndrome is clarified more fully through additional family studies, we suggest the following management programme: (1) avoidance of sunlight; (2) examination of the entire skin at least 4 times a year; (3) biopsy of any suspicious lesions; and (4) extensive patient education as to early signs of CMM. We provide high-risk patients with a wallet-size card embedded in plastic listing early signs of melanoma, and we show them appropriate illustrations.

In conclusion, the distinguishing cutaneous phenotype in the subject family, with its genetic aetiology and cancer association, now joins a list of at least 50 cancer-associated genodermatoses such as von Recklinghausen's neurofibromatosis, tuberous sclerosis, multiple mucosal neuroma syndrome, Gardner's syndrome, xeroderma pigmentosum, and others (Lynch, 1976; Frichot *et al.*, 1977; Lynch and Frichot, 1978). Patients from families such as these provide physicians with opportunities for improvement in cancer control, as well as for the elucidation of carcinogenesis.

We gratefully acknowledge support of this investigation by the Fraternal Order of Eagles.

Addendum

Since our manuscript was submitted, Dr Wallace H. Clark, Jr. and associates have published a paper dealing with the same hereditary disease. Their paper is entitled 'Origin of Familial Malignant Melanomas from Heritable Melanocytic Lesions. The B-K Mole Syndrome' which appears in the *Archives of Dermatology*, 114, 732-738, 1978. We believe that our more descriptive term 'Familial Atypical Multiple Mole-Melanoma Syndrome', to which we have ascribed the acronym FAMMM, is a much more meaningful term than 'The B-K Syndrome'. We believe that our term will provide physicians with a better basis for recognition and comprehension of the genetic significance of this newly described syndrome.

References

- Anderson, D. E. (1971). Clinical characteristics of the genetic variety of cutaneous melanoma in man. *Cancer*, 28, 721-725.
- Cawley, E. P. (1951). Genetic aspects of malignant melanoma. *Archives of Dermatology and Syphilology*, 65, 440-450.
- Clark, W. H. (1976). Symposium. *Clinicopathologic Conference*. American Academy of Dermatology Meeting, Chicago, December, 1976.

- Doll, R. (1977). Review article. Strategy for detection of cancer hazards to man. *Nature*, **265**, 589-596.
- Fraser, D. G., Bull, J. G., Jr., and Dunphy, J. E. (1971). Malignant melanoma and coexisting malignant neoplasms. *American Journal of Surgery*, **122**, 169-174.
- Fritchot, B. C., III, Lynch, H. T., Guirgis, H. A., Harris, R. E., and Lynch, J. F. (1977). A new cutaneous phenotype in familial malignant melanoma. *Lancet*, **1**, 864-865.
- Gartner, S. (1940). Malignant melanoma of the choroid and von Recklinghausen's disease. *American Journal of Ophthalmology*, **23**, 73-78.
- Kopf, A. W., and Bart, R. S. (1977). Malignant melanoma: a review. *Dermatology, Surgery and Oncology*, **3**(1), 41-125.
- Lynch, H. T. (1972). *Skin, Heredity and Malignant Neoplasms*, p. 239. Medical Examination Publishing Co., Flushing, N.Y.
- Lynch, H. T. (1976). *Cancer Genetics*, p. 639. C. C. Thomas, Springfield, Illinois.
- Lynch, H. T., Anderson, D. E., Smith, J. L., Jr., Howell, J. B., and Krush, A. J. (1967). Xeroderma pigmentosum, malignant melanoma, and congenital ichthyosis: a family study. *Archives of Dermatology*, **96**, 625-635.
- Lynch, H. T., and Fritchot, B. C. (1978). Skin, heredity, and cancer. *Seminars in Oncology*, **5**, 67-84.
- Lynch, H. T., Fritchot, B. C., III, Lynch, P., Lynch, J., and Guirgis, H. A. (1975). Family studies of malignant melanoma and associated cancer. *Surgery*, **141**, 517-522.
- Lynch, H. T., and Krush, A. J. (1968). Heredity and malignant melanoma: implications for early cancer detection. *Canadian Medical Association Journal*, **99**, 17-21.

Requests for reprints to Professor Henry T. Lynch, Creighton University School of Medicine, Department of Preventive Medicine/Public Health, 2500 California Street, Omaha, Nebraska 68178, USA.