

Spontaneous regression of metastatic malignant melanoma in 2 sibs with xeroderma pigmentosum

HENRY T. LYNCH, BERT C. FRICHOT, III, JEFFREY FISHER, J. LESLIE SMITH, JR., AND JANE F. LYNCH

From the Department of Preventive Medicine and Public Health, Creighton University School of Medicine, Omaha; the Departments of Dermatology and Preventive Medicine, Creighton and Nebraska University Health Foundation, Omaha Veterans Administration Hospital, Omaha, Nebraska; the Pathology Department, St. Louis University School of Medicine, St. Louis, Missouri; and the M. D. Anderson Hospital and Tumor Institute, Houston, Texas, U.S.A.

SUMMARY The clinical and pathology findings in 2 sibs with xeroderma pigmentosum (XDP), complicated by metastatic malignant melanoma which underwent spontaneous regression, are described. The pathology of one of these patients showed features of possible spontaneous regression, namely foamy histiocytes, capillary proliferation, and a chronic inflammatory infiltrate which was devoid of malignant cells, suggesting the possibility that an immunological mechanism was at work. It was of interest that a recent review of 27 cases of spontaneous regression of metastatic melanoma since 1900 contained a patient with XDP. Adding our 2 cases, at least 10% of the spontaneous regressions of metastatic melanoma occurred in patients with XDP. This unusual association raised the question that the genotype for XDP may possibly foster control of metastatic malignant melanoma in some as yet unknown way.

One of the most perplexing problems in the biology of cancer concerns the relatively rare phenomenon of its spontaneous regression. In a previous review of spontaneous regression of cancer from 1900 to 1960, Everson and Cole (1966) documented 176 cases of which 19 were examples of spontaneous regression of malignant melanoma. More than half of these cases were of 4 tumour types: hypernephroma, neuroblastoma, choriocarcinoma, and malignant melanoma. Nathanson (1976) reviewed the subject of spontaneous regression of malignant melanoma since 1900. He observed 33 patients with total regression of malignant melanoma. Of these cases, 27 were well documented examples of spontaneous regression of metastatic malignant melanoma.

Our purpose is to report the findings in 2 sibs with xeroderma pigmentosum who have been followed by us for more than 10 years as part of a clinical-genetic study of their family (Lynch *et al.*, 1967). These

patients have shown spontaneous regression of histologically verified metastatic malignant melanoma.

Material and methods

Medical genetic observations on the subject family, of whom 5 of 9 sibs had xeroderma pigmentosum (XDP), have been previously reported (Lynch *et al.*, 1967). The present report will focus upon the 28-year-old proband and his 33-year-old sister, each of whom have had histological verification of metastatic malignant melanoma. Medical histories were updated and verified through the review of primary medical documents from physicians, hospitals, and pathology laboratories. The pathology was reviewed independently by our collaborating pathologists.

Family study

Figure 1 shows the most recent pedigree findings of this family. Note that 5 of 9 sibs had XDP, 2 of whom have had spontaneous regression of metastatic malignant melanoma (Fig. 1; II.2, II.4).

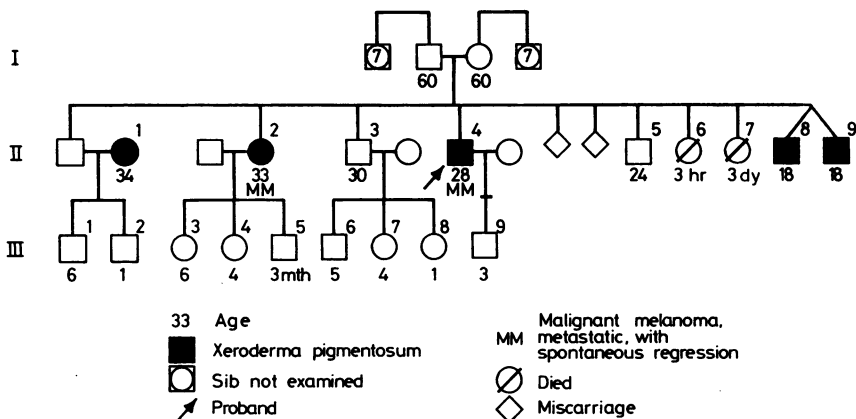


Fig. 1 Pedigree of family with xeroderma pigmentosum, showing a sibship with 5 affected individuals, 2 of whom manifested metastatic malignant melanoma and spontaneous regression (II.2, II.4).

CASE 1

The proband (Fig. 1; II.4) was a 28-year-old white male, in whom the diagnosis of XDP was established at 7 years of age when a programme of sunlight avoidance was started. He was examined by one of us (HTL) in 1966 and his past history has been reviewed previously (Lynch *et al.*, 1967). On re-examination in 1975, we observed the patient to show the typical features of XDP (hyper- and hypopigmentation, as well as multiple lentigines and ephelides) over the integument, but not over the bathing trunk area. There was evidence of ichthyosis vulgaris on the extensor surfaces of the limbs. In June 1966, at age 17, primary subcutaneous malignant melanoma was excised from the right forearm. Three months later a second surgical procedure at this same anatomical site

revealed metastatic malignant melanoma (Fig. 2 and 3). The pathology report at that time revealed 'post-surgical persistence of malignant melanoma in the skeletal muscle of the right forearm... Foci of malignant melanoma were also present within tissue coming from under the fascia'. No further surgery or other therapy was administered. The remainder of the physical examination was unremarkable; specifically, there was no visceral or cutaneous evidence of metastatic malignant melanoma.

CASE 2

This patient was the 33-year-old sister of the proband (Fig. 1; II.2). XDP was diagnosed in her at age 13, at which time a programme for avoidance of sunlight was started. She was later examined by one of us

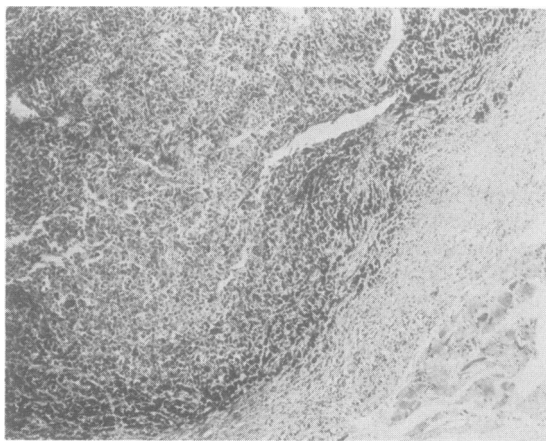


Fig. 2 Low power view of metastatic melanoma nodule (upper left) in fibrous connective tissue adjacent to skeletal muscle (lower right).

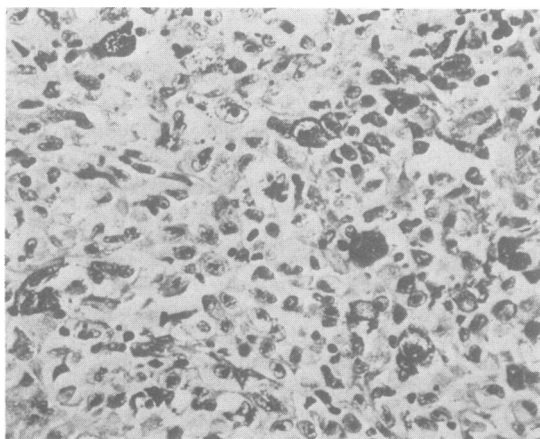


Fig. 3 Metastatic melanoma nodule composed of cytologically malignant, pleiomorphic, melanocytic cells, many heavily pigmented.

(HTL) in 1966, at age 22, as part of a family study (Lynch *et al.*, 1967). She has had at least 25 basal and squamous cell carcinomas, and a superficial malignant melanoma was excised from the right temple in 1965. There was no evidence of malignant melanoma at the time of our examination. In December 1967, at age 23, a lesion involving the skin of the left lower knee, measuring 1.6 × 0.8 × 0.4 cm deep, was excised. Histologically, this was found to be 'malignant melanoma, primary configuration; the base and margins of the resected skin were free of tumour'. No further excision of the area was done. Approximately 10 months later the patient was re-examined, at which time there was oedema of the leg and increased

pigmentation in the region of the old scar on the left knee. It is interesting that the patient gave a history of dehiscence of the wound after the previous surgery. There were 2 nodes in the left inguinal area measuring approximately 1.5 cm in diameter, and in the medial aspect of the middle third of the left thigh subcutaneous nodes were found which measured approximately 0.5 cm in diameter.

A groin dissection was performed. Superficial and deep femoral nodes were excised, with the largest measuring 3.3 cm in length, × 2.2 cm in width, × 1.4 cm in depth. These lesions grossly appeared to be involved with malignant melanoma (Fig. 4 and 5).

Microscopical examination showed that 2 of the 6

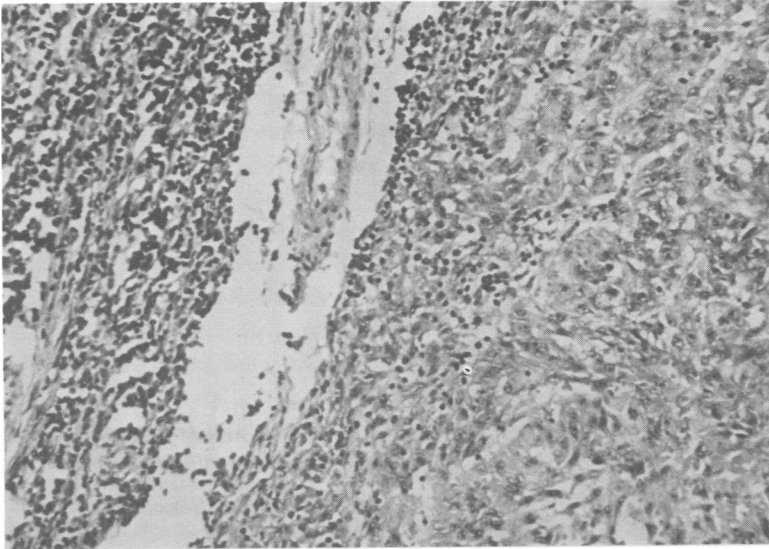


Fig. 4 Femoral lymph node involved by metastatic malignant melanoma. Normal lymph node is at right and undergoes abrupt transition to malignant melanoma. Even at this relatively low magnification, the cytological atypia can be appreciated. (Haematoxylin and eosin ×59.)

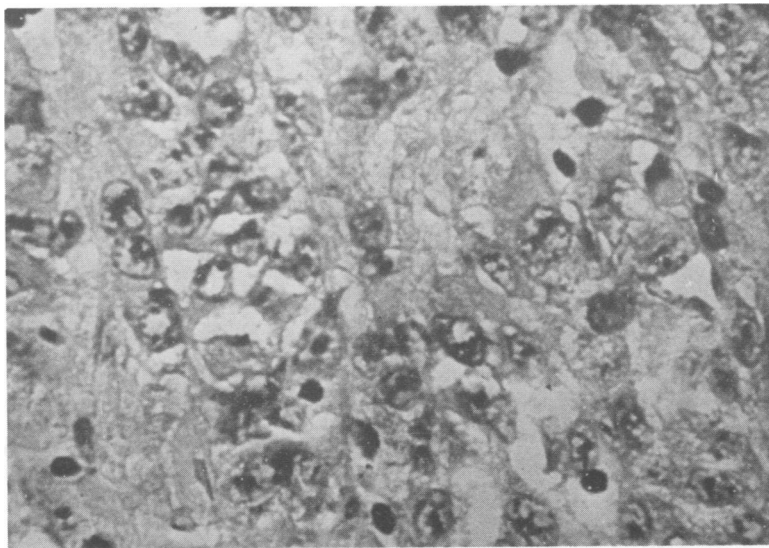


Fig. 5 High power view of the same lymph node as in Fig. 4. Note the marked cytological atypia with prominent nucleoli and nuclear hyperchromaticity. (Haematoxylin and eosin ×237.)

external iliac nodes contained metastatic malignant melanoma. Of 14 superficial and deep femoral nodes, 4 contained metastatic malignant melanoma. The accompanying skin from the left knee showed 2 small foci of junctional naevi. Each of these areas showed some cellular atypia and associated inflammatory reaction. However, these lesions did not show histological evidence of malignant melanoma. It was believed that the previous malignant melanoma removed from the skin on the left knee 10 months before the groin dissection was apparently the primary site for the multiple nodal metastases. No further treatment was given to this patient.

Two months later, during January 1969, a lesion involving the skin, measuring $2.0 \times 1.7 \times 1.0$ cm in depth, was excised from the soft tissue of the knee. This comprised a firm, dark-coloured piece of tissue which, on microscopical examination, was found to be a subcutaneous nodule formed by several circumscribed lobules largely occupied by metastatic malignant melanoma. Lymphoid tissue present within this area suggested that the nodule may originally have been a lymph node which was now largely replaced by malignant melanoma. Pathological diagnosis was metastatic malignant melanoma. Concurrent with these observations, there was histological evidence of

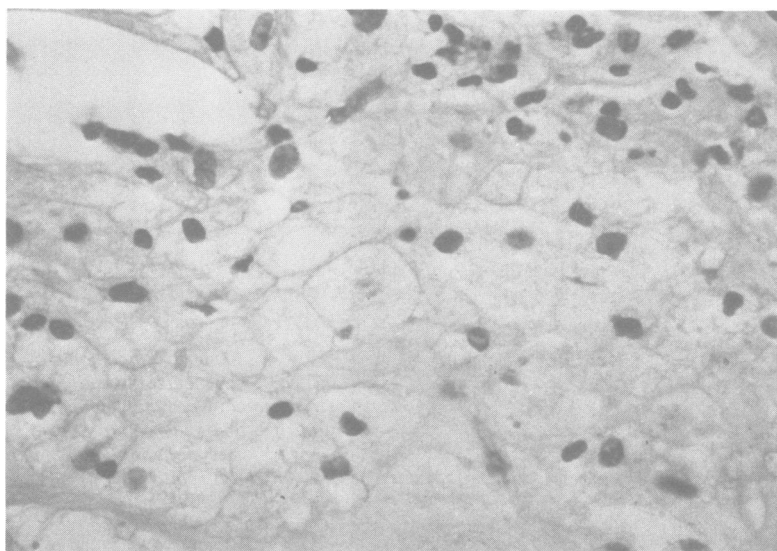


Fig. 6 Area of foamy laden histiocytes within a lymph node containing metastatic malignant melanoma. (Haematoxylin and eosin $\times 237$.)

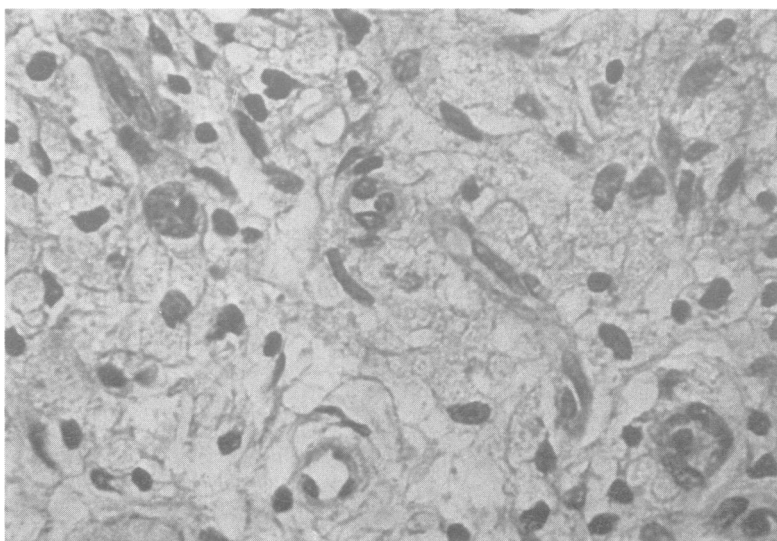


Fig. 7 View from area adjacent to that seen in Fig. 6 showing capillary proliferation and chronic inflammatory cells, chiefly lymphocytes. (Haematoxylin and eosin $\times 237$.)

foamy-laden histiocytes within a lymph node containing metastatic malignant melanoma (Fig. 6). In an adjacent area (Fig. 7), there were capillary proliferation and chronic inflammatory cells, chiefly lymphocytes. These observations could be interpreted as histological evidence of the spontaneous regression of the metastatic malignant melanoma which was apparent clinically.

After the groin dissection, the oedema of her leg began to resolve. She showed progressive improvement in her health. She has since had 3 normal pregnancies, with the most recent occurring in 1977. The patient has not been personally examined by us since our initial evaluation in 1966. However, we have been able to retrieve medical documents from physicians and from members of the family, including her parents. All of these reports indicate that the patient is apparently in an excellent state of health. The affected area of the right leg has apparently returned to normal. Unfortunately, the patient has steadfastly refused any further participation in our investigation.

Discussion

Spontaneous regression of metastatic malignant melanoma in a sister and brother affected with XDP, who have survived 7 and 11 years, respectively, in the absence of therapy, poses a challenge for interpretation of pathogenetic mechanisms contributing to this unusual phenomenon. In the study in question, one area of a lymph node containing metastatic malignant melanoma showed several features of possible spontaneous regression, namely foamy histiocytes, capillary proliferation, and a chronic inflammatory infiltrate. The lymphocytic infiltrate in this area, devoid of malignant cells, suggests that perhaps an immunological mechanism was at work. These histological features and their potential immunological significance for tumour regression have been well documented (Bodurtha *et al.*, 1976).

Nathanson's review (1976) uncovered 2 patients with XDP who underwent spontaneous regression of malignant melanoma (1 with regression of a primary, and 1 with regression of metastatic malignant melanoma). Combining Nathanson's 27 cases of spontaneous regression of metastatic malignant melanoma (one with XDP), and our 2, gives an approximate 10% frequency of spontaneous regression of metastatic melanoma in patients with XDP. The question that comes immediately to mind is: does the genotype for xeroderma pigmentosum, a known multifaceted hereditary disease with impaired DNA repair mechanisms, and with skin as the principal cancer target organ, somehow incredibly also foster a message to be learned from this experiment of nature? This question, of course, raises certain aetio-

logical considerations relevant to the survival of the species in an evolutionary sense. This reasoning is not unlike explanations given for the favourable response to *Plasmodium falciparum* in heterozygous carriers of the gene for sickle cell anaemia (Livingstone, 1967), the so-called 'thrifty genotype' for diabetes mellitus (Neel, 1962), and the heterozygous advantage for other genetic traits.

Should this reasoning be plausible, the study of XDP could have profound implications for the comprehension of control mechanisms in certain forms of carcinogenesis. Conceivably, such information could be applied to problems in carcinogenesis in the general population.

Anderson (1971) has postulated that patients with the familial variety of malignant melanoma may show a better prognosis than non-familial (sporadic) occurrences of this disease. Lynch *et al.* (1978b) have documented cases of hereditary melanoma in the Familial Atypical Multiple Mole-Melanoma syndrome (FAMMM syndrome) which shows excellent survival in the face of multiple primary malignant melanomas. For example, a 36-year-old white male had 7 histologically verified separate primary melanomas since age 20, and he continues to be in excellent health. His 34-year-old sister had the identical cutaneous phenotype for the FAMMM syndrome. She has now had 4 primary melanomas and is also in excellent health. The mother of these patients also manifested the FAMMM syndrome and had 2 primary melanomas (aged 49 and 56); she is in excellent health at age 60. Finally, unusual survival from multiple primary malignant neoplasms, primarily adenocarcinomas of the colon and endometrium in advanced stages, has been observed in patients with autosomal dominantly inherited Cancer Family syndrome (Lynch *et al.*, 1978a).

It is noteworthy that infections have been frequently observed in patients who have undergone spontaneous regression of cancer (Nathanson, 1976). This may have been important in our 33-year-old patient who experienced dehiscence of her surgical wound.

We urge investigators to probe areas such as hormonal, immunological competency, viral host interactions, bacterial infections, and others, in order to explain mechanisms of cancer toleration in patients with XDP. This knowledge might ultimately yield clues to the comprehension of certain forms of cancer in the general population.

References

- Anderson, D. E. (1971). Clinical characteristics of the genetic variety of cutaneous melanoma in man. *Cancer*, **28**, 721-725.
- Bodurtha, A. J., Berkelhammer, J., Kim, Y. H., Laucius, J. F., and Mastrangelo, M. J. (1976). A clinical, histologic, and immunologic study of a case of metastatic malignant melanoma undergoing spontaneous remission. *Cancer*, **37**, 735-742.

- Everson, T. C., and Cole, W. H. (1966). *Spontaneous Regression of Cancer*. Saunders, Philadelphia.
- Livingstone, F. B. (1967). *Abnormal Hemoglobins in Human Populations: A Summary and Interpretation*. Aldine, Chicago.
- Lynch, H. T., Anderson, D. E., Smith, J. L., Jr., Howell, J. B., and Krush, A. S. (1967). Xeroderma pigmentosum, malignant melanoma, and congenital ichthyosis. *Archives of Dermatology*, **96**, 625-635.
- Lynch, H. T., Bardawil, W. A., Harris, R. E., Lynch, P. M., Guirgis, H. A., and Lynch, J. F. (1978a). Multiple primary cancer and prolonged survival: familial colon and endometrial cancer. *Diseases of Colon and Rectum*, **21**, 165-168.
- Lynch, H. T., Frichot, B. C., III, and Lynch, J. F. (1978b) Familial atypical multiple mole-melanoma syndrome. *Journal of Medical Genetics*, **15**, 352-356.
- Nathanson, L. (1976). Spontaneous regression of malignant melanoma: a review of the literature on incidence, clinical features, and possible mechanisms. Conference of Spontaneous Regression of Cancer. *NCI Monograph*, **44**, 67-77.
- Neel, J. V. (1962). Diabetes mellitus: a thrifty genotype rendered detrimental by 'Progress'? *American Journal of Human Genetics*, **14**, 353-362.

Requests for reprints to Professor Henry T. Lynch, Department of Preventive Medicine and Public Health, School of Medicine, Creighton University, 2500 California Street, Omaha, Nebraska 68178, USA.