

# Angiokeratoma corporis diffusum (Anderson-Fabry disease) in a single large family in Nova Scotia

M. W. SPENCE, J. T. R. CLARKE, D. M. D'ENTREMONT, G. A. SAPP, E. R. SMITH, A. L. GOLDBLOOM, AND G. DAVAR

*From the Departments of Pediatrics, Medicine, Ophthalmology, and Biochemistry, Dalhousie University; and The Atlantic Research Centre for Mental Retardation, Halifax, Nova Scotia, Canada*

**SUMMARY** Eighteen males, 17 of whom were members of a single family, affected with angiokeratoma corporis diffusum were examined in detail to determine the extent of clinical variation of the expression of what was almost certainly the same X-linked mutation in each. The commonest symptom was episodic bouts of severe, painful dysaesthesia in hands and feet. This was a major complaint of 12, a minor complaint of 5, and absent in 1. In over half the subjects, the skin rash that is considered a characteristic sign of the disease was absent or inconspicuous. All exhibited mild clubbing of fingers and toes, and 15 showed variable limitation of active and passive extension of the 5th fingers bilaterally. Only 2 (aged 36 and 47) had evidence of significant renal disease. Electrocardiograms showed abnormally short PR intervals in 4, and right ventricular conduction disturbances in 5. Echocardiograms on 9 showed no evidence of myocardial dysfunction. The marked variation of the expression of some features of the disease indicates that the clinical expression of the mutation is likely to be subject to considerable genetic or environmental modification in each individual.

Angiokeratoma corporis diffusum (Anderson-Fabry disease, ACD) is an X-linked disorder of glycosphingolipid metabolism characterised by accumulation of ceramide trihexoside in vascular tissue, kidney, myocardium, and other tissues (Sweeley *et al.*, 1972). It produces cutaneous angiokeratoma, progressive renal failure, and accelerated cardiovascular disease, usually culminating in death in the fourth or fifth decades of life. The disease is a lipid storage disorder (Sweeley and Klionsky, 1963) as a result of a hereditary deficiency of the enzyme ceramide trihexosidase (Brady *et al.*, 1967), but unlike other sphingolipidoses, such as Tay-Sachs disease, the central nervous system is usually spared.

Several descriptions of the phenotypic characteristics have been reported (Sweeley *et al.*, 1972; Wallace, 1973). These have included a review of 21 cases in 8 British families with personal observations of 9 males (Wise *et al.*, 1962), a review of 108 cases in published reports and a description of a further 2 males and 9 females (Colombi *et al.*, 1967), and a

discussion of the phenotypic manifestations and genetics in 17 families (Opitz *et al.*, 1965). Cutaneous angiokeratoma was the major diagnostic feature of the disease in all patients described before the mid 1960s. With wider recognition of the condition, however, it became apparent that there was variation in the phenotypic expression within families (Johnston *et al.*, 1968). The identification of the stored glycosphingolipid (Sweeley and Klionsky, 1963), particularly in urinary sediment (Philippart *et al.*, 1969), and the development of relatively simple procedures for showing the enzyme defect (Kint, 1970) provided additional independent methods for identifying affected people. Additional patients with ACD disease were described who did not exhibit the pathognomonic skin lesions (Urbain *et al.*, 1969; Clarke *et al.*, 1971) even late in the course of the disease. This discovery, along with the observation that other manifestations of the disease were found in some, but not all, patients, suggested that environmental factors or nonallelic genetic interactions may play some role in the expression of the primary mutation.

We explored the degree of phenotypic variation in

18 patients with ACD, 17 of whom belonged to one large family in Nova Scotia. Considerable variation in the clinical expression of their disease was found. To our knowledge, this is the first study of a large group of hemizygotes from one family in which ascertainment was on the basis of demonstration of the enzyme defect.

**Methods**

The index case was a patient studied extensively in Montreal (Case 2 of Clarke *et al.*, 1971; IV.20 in the Fig.). We later found that the family included 2 patients previously described by Bethune *et al.* in Halifax in 1961. With the co-operation of many local family practitioners, we were able to locate most of the relatives of the proband still living in the Maritimes. The family was the subject of an extensive study of carrier detection in ACD (Spence *et al.*, 1977). Data collected by personal interviews, searches of the public archives, and enzyme assays provided the basis for the abbreviated pedigree shown in the Fig. (only affected males and carrier females are shown).

Blood samples were obtained and analyses of  $\alpha$ -galactosidase and  $\beta$ -galactosidase activities in leucocytes and plasma were undertaken according to methods described elsewhere (Spence *et al.*, 1976, 1977). A total of 21 males with ACD were identified on the basis of severe  $\alpha$ -galactosidase deficiency (Kint, 1970). One of the subjects (RU), whose relation to the main family is still not clear, was identified on the basis of combined clinical and biochemical studies.

**HISTORY AND PHYSICAL EXAMINATION**

History taking, functional inquiry, and physical examination were conducted following a previously developed standardised protocol. These protocols were designed to record as quantitatively as possible the different symptoms and physical features which have, from time to time, been reported in ACD. In addition, a more general functional inquiry and physical examination was included, to detect any previously unrecognised signs or symptoms of the disease. A trained nurse-co-ordinator reviewed the completed questionnaires with each subject to ensure that the questions were clearly understood and

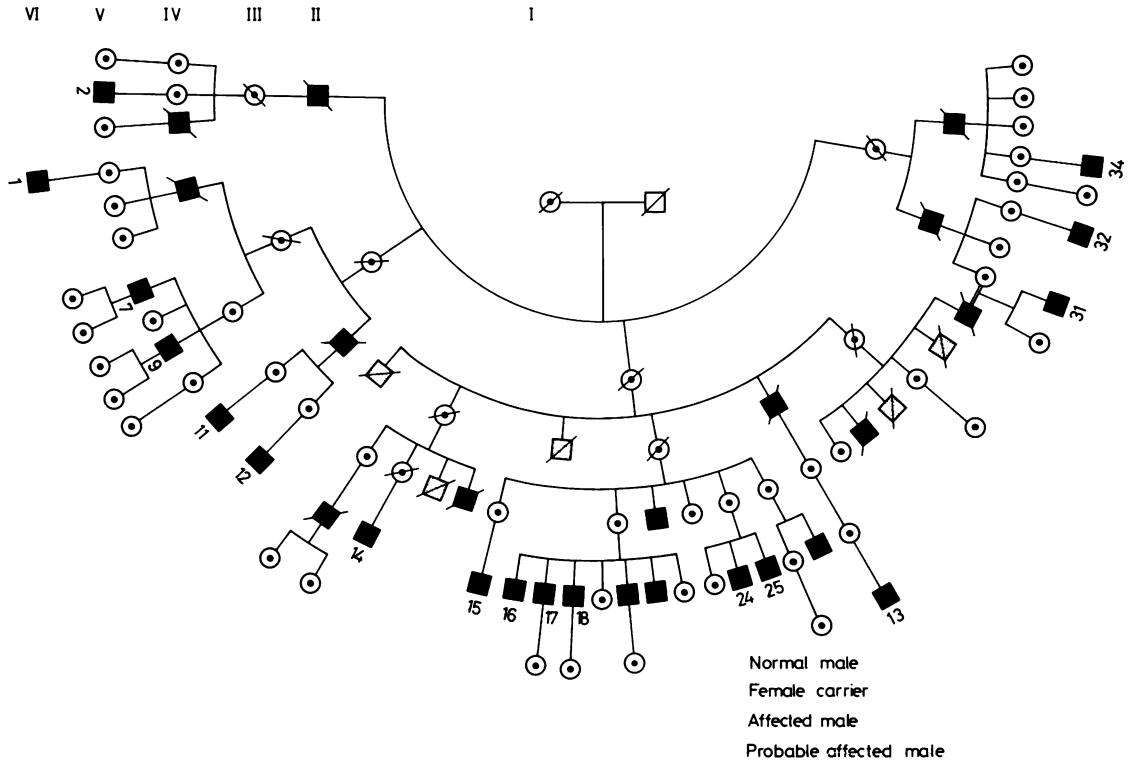


Fig. Pedigree of family with Fabry's disease showing affected males and carrier females only. There are at least 228 additional relatives of normal or uncertain status who are not shown. The status of each subject shown was established on the basis of historical information for most of the dead members of the family, and measurements of  $\alpha$ -galactosidase activities in plasma and leucocytes from all of the living and 3 of the dead (IV.4, IV.11, IV.20).

answered appropriately. The general physical examinations were performed by two of us.

The characteristic dysaesthesias were assigned a score 0 to +++ based on age of onset, frequency, severity, and duration of attacks. Symptoms resulting in a score 1+ might not warrant a visit to a physician, and unless specifically sought by direct questioning, might be overlooked in a normal medical history. This somewhat subjective evaluation was useful for internal comparisons within this study.

In an attempt to quantify the extent of the skin lesion in each patient, a Skin Rash Score (SRS) was developed. Each of 8 regions of the body (face, anterior torso, posterior torso, umbilicus, genitalia, buttocks, extremities, and buccal mucosa) was examined carefully and assigned a score ranging from 0 for no lesions to 4+ for regions in which the lesions were almost confluent. In those regions with scores of 1+, only 1 to 2 discrete but inconspicuous angio-keratomas were found. A score of 2+ was assigned to regions in which the lesions were more numerous but still inconspicuous. Regions with a fairly obvious rash were scored 3+. The SRS was the sum of the scores for all 8 regions.

All subjects underwent ocular examination, including portable slit-lamp examination, by an ophthalmologist; 9 were examined in detail by a cardiologist. All had 12-lead electrocardiograms performed at the time of clinical examination. In addition, 9 patients had time-motion echocardiograms to assess chamber size and myocardial function.

#### LABORATORY STUDIES

Besides the measurement of  $\alpha$ -galactosidase and  $\beta$ -galactosidase activities in leucocytes and plasma, a number of haematological and biochemical tests were done by standard methods. These included the determination of haemoglobin, haematocrit, erythrocyte sedimentation rate, serum creatinine, urea nitrogen, uric acid, total proteins and albumin, alkaline phosphatase, lactic dehydrogenase, glutamic-oxaloacetic transaminase, serum triglycerides, and total cholesterol. Fresh urine specimens were tested for pH, glucose, ketones, proteins, and blood with Labstix (Ames Company, Elkhart, Indiana, USA). Any showing abnormalities were submitted for full quantitative urine analysis, including microscopical examination.

#### Results

Of the 21 patients with ACD known to us, 18 were able, and agreed, to participate in the study. The eldest (V.14) in the group had had renal allotransplantation for treatment of chronic renal failure (Spence *et al.*, 1976). Apart from the 3-year-old, all but 1 were

either attending school full time or were gainfully and continuously employed, including the patient who had had renal transplantation. Only 1 of the subjects had lost significant time from work as a result of symptoms of ACD. Of the 14 subjects over 18 years of age, 7 were married and had a total of 13 children.

#### SYMPTOMS

Most of the subjects described themselves as robust rather than sickly. About a third of the group, however, felt that they tired abnormally easily.

The most outstanding and constant symptom, described by all but the apparently asymptomatic 3-year-old child (Table), was intermittent episodes of pain and numbness in the hands and feet. The pain was uniformly described as a very unpleasant burning and 'pins and needles' sensation. Usually the painful crises lasted less than 4 hours, though 1 subject described a bout lasting 3 weeks. Of the 17 subjects who gave a history of recurrent episodes of pain, 14 reported the onset occurring before 15 years of age and most before age 10. The frequency of the painful crises varied from weekly to rarely (subject V.25 experienced only 2 bouts during his whole life); most had an episode about once a month. The degree of discomfort associated with the painful episodes was usually severe. During the painful crises, 9 patients experienced fever and 3 reported an increase in the frequency of micturition immediately following the bouts of pain.

In most cases, the pain was aggravated by, and occasionally precipitated by, systemic illness (for example, influenza), exertion, and hot weather. Factors that the patients claimed ameliorated the pain included non-narcotic analgesics, counter-irritants, applications of cold, and rest. For relief, 2 used narcotic analgesics (codeine); in 2 others, nothing appeared to influence the discomfort. Eight patients were receiving phenytoin (100 to 400 mg daily) for prophylactic treatment of the pain; 7 of them experienced significant reductions in the frequency of painful crises (for example, from weekly episodes before treatment to twice-yearly on the drug).

Eleven subjects reported abnormally decreased sweating. The degree of hypohidrosis did not correlate with the frequency or severity of painful crises. Two patients reported having had seizures. In one case, the subject was in renal failure and hypertensive at the time. The other subject, later found to be uraemic, described a few widely spaced seizures of obscure aetiology.

Six complained of chronic cough, but only 2 (the only smokers in the group) smoked cigarettes. Two others described bouts of angina-like chest pain. One of these, 20 years old, had congenital aortic valvular disease (subject RU); the other (V.7), aged 31, had

Table Symptoms and signs in 18 male patients with Fabry's disease

Patient no. (see Fig.)	Age (y)	Painful episodes	Skin rash score	Corneal opacities	ECG and echocardiographic findings
VI.1	3	0	0	0	PR < 0.02 sec
V.32	7	++	0	0	RVCD
VI.13	12	+	0	0	Normal
V.34	15	++	12	0	PR < 0.02 sec
V.25	19	+	1	0	Normal
RU	20	+++	16	++	LVH (aortic valve disease)
V.12	20	++	4	++	Normal
V.24	21	+++	2	+	Normal
V.16	23	++	0	++	Normal
V.31	25	+++	2	0	Normal
V.18	27	++	4	++	Normal
V.11	28	+++	6	++	RVCD
V.7	31	+	14	ne	RVCD
V.17	33	++	15	+	1° AVB (pulmonary stenosis)
V.2	33	+	2	++	Normal
V.9	37	+	2	0	LVH; PR < 0.02 sec
V.15	40	++	10	++	RBBB; PR < 0.02 sec
V.14	47	++	21	++	LVH; LAO

RU, relationship to main family uncertain.

Painful episodes were given a 0 to +++ rating based on age of onset, frequency, and duration of attacks (see text). Symptoms rated 1+ might be overlooked during a routine history.

Skin rash score is the sum of scores (0 to 4+) assigned to describe the extent of the lesions in 8 regions of the body.

Corneal opacities: 0, none detected; +, unilateral; ++, bilateral; ne, not examined.

RVCD, right ventricular conduction defect; LVH, left ventricular hypertrophy; AVB, atrioventricular block; RBBB, right bundle branch block; LAO, left atrial overload.

evidence of a right ventricular conduction defect (abnormal QRS) but no other abnormalities.

#### SIGNS

Considering that all but one were from the same family, the subjects showed remarkable variation, not only in general physical characteristics, but also in those physical signs usually associated with ACD. As a group the subjects displayed no common, distinguishing characteristic of facial appearance, build, or stature. Only 2 appeared 'sickly' or unusually thin; several, including the patient who was later found to have significant renal disease, appeared uncommonly robust.

Special attention was directed towards determining whether each subject had any of the classical skin lesions (angiokeratomas) considered pathognomonic of ACD. One member of the family (IV.20; Fig.), not included in this study, had already been reported to have no skin lesions despite having advanced renal disease as a result of ACD (Clarke *et al.*, 1971). It should be emphasised that though the skin lesions of ACD, when they are present, are distinctly characteristic in appearance, they are very small and easily overlooked even when present in significant numbers. Of our subjects, 4 (aged 3½ to 23 years) had no discernible angiokeratomas (Table). In a further 5, only a few lesions were found, and these would have been missed had not a meticulous search been made for them. Thus, in over half the patients, the physical sign considered most characteristic of ACD was

absent, or would almost certainly have been overlooked in the course of a thorough routine physical examination. The distribution of skin lesions, when present, was typical of the disease. The umbilicus and genitalia were the most consistently positive areas. Few lesions were found on the face or extremities.

The corneal opacities, found in 10 of the 17 subjects examined, consisted of gently curved, parallel linear streaks in the lower half of the cornea, bilaterally. Slit-lamp examination was necessary to show up the lesions, and in no case did they appear to interfere with vision.

The same patients who exhibited corneal lesions also tended to have mild to moderate irregularities in the calibre and tortuosity of conjunctival and retinal blood vessels. In most cases, however, these changes were subtle and unlikely by themselves to attract attention. No lenticular abnormalities were found.

All 18 subjects had mild to moderate clubbing of fingers and toes. In 15 subjects, mild to severe limitation of active and passive extension of the 5th fingers of the hands was also found. In most, the deformity was confined to the distal interphalangeal joint (DIP); in some, the proximal interphalangeal joint was involved, alone or in addition to the deformity of the DIP. These deformities, which have been described in other patients with ACD (Sweeley *et al.*, 1972), occurred in the absence of any thickening of the palmar aponeurosis or other evidence of Dupuytren's contracture.

One patient (V.14), who had been on long term

corticosteroid immunosuppressive therapy after renal transplantation, showed moderately severe thoracic kyphosis. In 3 others, mild kyphosis was found.

Apart from the patient who had had renal transplantation, only 1 patient exhibited any clinical evidence of significant renal impairment. This patient (V.9), aged 36 years, had severe bilateral pedal oedema, mild arterial hypertension (135/95), and proteinuria. This patient was asymptomatic apart from the ankle swelling, and he looked physically robust.

Two subjects had semilunar cardiac valvular disease: congenital pulmonary valvular stenosis in one (V.17), and aortic stenosis and regurgitation in the other (RU). One subject (V.15), aged 40, had physical evidence of mild peripheral occlusive arterial disease. No other instances of clinically significant circulatory disease were found, despite the known association of ACD with premature cardiovascular and cerebrovascular complications.

#### ELECTROCARDIOGRAMS

All 18 patients were in sinus rhythm at the time of study and all had normal mean frontal plane axes. The PR intervals ranged from 0.10 to 0.21 seconds (mean 0.14), with 4 patients having abnormally short intervals (<0.02 seconds), and 3 having borderline measurements (0.12 seconds). One patient had first degree atrioventricular block (PR = 0.21 seconds); the remainder had intervals within normal limits. Despite the high incidence of short PR intervals, 5 patients had right ventricular conduction disturbance (complete right bundle branch block in 1). Three patients met criteria for left ventricular hypertrophy, which was secondary to renal hypertension in 2, and to congenital aortic valve disease in the other.

#### ECHOCARDIOGRAMS

The aortic root and left atrial dimensions were normal in all cases. One patient (V.17) had congenital pulmonary valvular stenosis and an enlarged right ventricle (end-diastolic dimension 38 mm; normal  $\leq 31$  mm). Only the patient with aortic valve disease (RU) had enlargement of the left ventricle, and all had normal systolic shortening of the end-diastolic dimension. One patient with aortic valve disease, and one with systemic hypertension, had increased left ventricular wall thickness at 13 mm.

#### LABORATORY FINDINGS

Apart from severe  $\alpha$ -galactosidase deficiency (plasma  $\alpha$ -galactosidase  $2.6 \pm 0.5$  nmol/h per ml; normal,  $31.0 \pm 10.9$ ), no consistent laboratory abnormalities were detected in the members of the study group. In particular, no abnormalities of serum total cholesterol or triglycerides were found, despite the observation

that the glycosphingolipid composition of the plasma lipoproteins in patients with ACD is abnormal (Clarke *et al.*, 1976). One subject (V.9) showed chemical evidence of renal failure: serum creatinine, 2.7 mg/100 ml (238.7  $\mu$ mol/l); urea nitrogen, 38 mg/100 ml (27.1 mmol/l); alkaline phosphatase, 147 IU/l; moderate proteinuria. He was the only subject to show proteinuria.

#### Discussion

ACD first attracted medical attention as a result of the peculiar skin rash associated with it. Indeed, the presence of the small (1 to 2 mm), discrete, slightly raised, dark red to black lesions, symmetrically distributed on the trunk and genital area, were considered a constant characteristic and virtually pathognomonic of the disease. We now recognise, however, that many patients with the disease have no skin lesions, or at the most, only a few inconspicuous spots in relatively inaccessible areas of the genital region.

In our survey, 4 subjects had no skin lesions at all; 3 of these were, however, under the age of 13. The SRS correlated with age (Table). The correlation was not close ( $r = 0.57$ ), however, indicating that the marked variability in the occurrence of skin lesions in adults with ACD is probably not merely a reflection of duration of the disease.

There was no correlation between the painful dysaesthesia and extent of the skin rash on the one hand, and the severity of the renal involvement on the other. Of the 2 patients in renal failure, 1 (V.14) had moderately severe painful episodes and many obvious skin lesions throughout his body (SRS = 21); the other (V.9) had few painful episodes and only a few inconspicuous lesions in the umbilical and genital areas (SRS = 2).

Like the skin lesions, the ocular lesions of ACD are classically considered pathognomonic of the disease. The whorled streaks in the corneas are considered especially characteristic, and their presence or absence has even been used as a test of heterozygosity for ACD disease in women (Wise *et al.*, 1962; Sweeley *et al.*, 1972). However, in our series, 6 of 17 hemizygous males had no ocular lesions whatsoever, and only 8 of 17 had clearly demonstrated whorled streaks, bilaterally. Those who had no ocular lesions also tended to have few, if any, skin lesions.

The pain described by many patients with ACD was one of the most consistent findings in our series, as it was in the patients described by Johnston *et al.* (1968). In our study, the frequency or severity of attacks did not correlate well with any other manifestation of the disease. The painful crises began in childhood in all cases and tended to lessen spontaneously in early adulthood.

One of the most constant physical findings in our series was deformity of the distal interphalangeal joint of the fingers, particularly the 5th digit, causing varied limitation of active and passive extension. This has been described in other series of patients with ACD (Sweeley *et al.*, 1972). The relation to the primary mutation is unknown; it may represent a pleiotropic effect. However, the incidence of the deformity in unaffected members of the family was not determined. Our patients also exhibited a peculiar deformity of the fingertips and toes, resembling clubbing. None showed any signs of chronic pulmonary disease, and only a few admitted to pulmonary symptoms (chronic cough in most cases). None of the subjects had cyanosis or gave histories of dyspnoea on exertion. Though detailed pulmonary functions tests were not done, no clinical evidence of significant pulmonary dysfunction was found in any of the subjects. On the basis of our own findings and results reported by others (Bartimmo *et al.*, 1972), we feel that the pulmonary involvement in ACD has been greatly exaggerated.

In the light of recent observations of electrocardiographic changes in patients with Fabry's disease (Roudebush *et al.*, 1973), our results are of some interest. Our data support the observation that patients with ACD have an increased incidence of accelerated atrioventricular conduction, but because of the total range of atrioventricular conduction times encountered, this feature is of no use in identifying involved patients. The mechanism of the short PR interval is not clear; the presence of a pathway which bypasses the junctional delay tissues, similar to that present in the Lown-Ganong-Levine syndrome, might be postulated (Lown *et al.*, 1952). However, paroxysmal tachycardias were not a feature in our patients, neither are we aware of a significant association of this in other reported series.

With the exception of right ventricular conduction disturbance in 5, the other electrocardiographic abnormalities in these patients could be explained on the basis of associated disease or complications of the process of ACD.

In view of the observation that the myocardium becomes involved in ACD (Sweeley *et al.*, 1972), the results of the echocardiographic studies showed surprisingly normal results. Excluding the 3 patients with aortic valve disease, pulmonary stenosis, and renal failure hypertension, all measurements were within normal limits. Though single-dimension echocardiography may not detect segmental contraction abnormalities (such as those seen in large vessel coronary artery disease), our results provide strong evidence against the presence of a diffuse 'myopathic' disorder in our patients with ACD. The heart failure recognised in patients with the disease may be either the result of severe hypertension and uraemia, or may

be due to the coexistence of large vessel coronary artery disease.

In summary, the results of our survey show that there is marked clinical variation in the expression of ACD, even within a genetically monoclonal population. Clearly, interallelic and/or gene environment interactions play a role in the development of the signs and symptoms of the disease. The nature of the basic defect is understood at a biochemical level, but the relation between this and many of the clinical signs, particularly the joint deformities, is not clear. Though the skin rash has been the method by which most cases of ACD have been identified, and the skin lesions are practically pathognomonic of the disease, they are absent in a significant proportion of patients, and inconspicuous enough in many others to make their absence useless in ruling out ACD in the young patient. The same applies to the ocular lesions. The peculiar paroxysmal attacks of pain appear to be a more constant feature, particularly in adolescents, but may be mild and/or infrequent and consequently overlooked. The diagnosis should be confirmed by the absence of  $\alpha$ -galactosidase activity in plasma or leucocytes. Prophylactic treatment of painful crises by the continued administration of phenytoin is often rewarding.

The generous co-operation of several Nova Scotia family practitioners is gratefully acknowledged. Without their help, this project would not have been possible. The project was supported in part by grants from the Department of National Health and Welfare, the Medical Research Council of Canada, the Nova Scotia Heart Foundation, and the Maritime provincial governments. Dr Spence is an Associate of the Medical Research Council of Canada.

#### References

- Bartimmo, E. E., Guisan, M., and Moser, K. M. (1972). Pulmonary involvement in Fabry's disease: a reappraisal. *American Journal of Medicine*, **53**, 755-764.
- Bethune, J. E., Landrigan, P. L., and Chipman, C. D. (1961). Angiokeratoma corporis diffusum (Fabry's disease) in two brothers. *New England Journal of Medicine*, **265**, 1280-1285.
- Brady, R. O., Gal, A. E., Bradley, R. M., Martensson, E., Warshaw, A. L., and Laster, L. (1967). Enzymatic defect in Fabry's disease: ceramide trihexosidase deficiency. *New England Journal of Medicine*, **276**, 1163-1167.
- Clarke, J. T. R., Knaack, J., Crawhall, J. C., and Wolfe, L. S. (1971). Ceramide trihexosidosis (Fabry's disease) without skin lesions. *New England Journal of Medicine*, **284**, 233-235.
- Clarke, J. T. R., Stoltz, J. M., and Mulcahey, M. R. (1976). Neutral glycosphingolipids of serum lipoproteins in Fabry's disease. *Biochimica et Biophysica Acta*, **431**, 317-325.
- Colombi, A., Kostyal, A., Bracher, R., Gloor, F., Mazzi, R., and Tholen, H. (1967). Angiokeratoma corporis diffusum—Fabry's disease. *Helvetica Medica Acta*, **34**, 67-83.
- Johnston, A. W., Weller, S. D. V., and Warland, B. J. (1968). Angiokeratoma corporis diffusum. Some clinical aspects. *Archives of Disease in Childhood*, **43**, 73-79.

- Kint, J. A. (1970). Fabry's disease,  $\alpha$ -galactosidase deficiency. *Science*, **167**, 1268-1269.
- Lown, B., Ganong, W. F., and Levine, S. A. (1952). The syndrome of short P-R interval, normal QRS complex and paroxysmal rapid heart action. *Circulation*, **5**, 693-706.
- Opitz, J. M., Stiles, F. C., Wise, D., Race, R. R., Sanger, R., Von Gemmingen, G. R., Kierland, R. R., Cross, E. G., and DeGroot, W. P. (1965). The genetics of angiokeratoma corporis diffusum (Fabry's disease), and its linkage with Xg(a) locus. *American Journal of Human Genetics*, **17**, 325-342.
- Philippart, M., Sarlieve, L., and Manacorda, A. (1969). Urinary glycolipids in Fabry's disease: their examination in the detection of atypical variants and the presymptomatic state. *Pediatrics*, **43**, 201-206.
- Roudebush, C. P., Foerster, J. M., and Bing, O. H. L. (1973). Abbreviated PR interval of Fabry's disease. *New England Journal of Medicine*, **289**, 357-358.
- Spence, M. W., Goldbloom, A. L., Burgess, J. K., d'Entremont, D. M., Ripley, B. A., and Weldon, K. L. (1977). Heterozygote detection in angiokeratoma corporis diffusum (Anderson-Fabry disease). *Journal of Medical Genetics*, **14**, 91-99.
- Spence, M. W., MacKinnon, K. E., Burgess, J. K., d'Entremont, D. M., Belitsky, P., Lannon, S. G., and MacDonald, A. S. (1976). Failure to correct the metabolic defect by renal allotransplantation in Fabry's disease. *Annals of Internal Medicine*, **84**, 13-16.
- Sweeley, C. C., and Kliensky, B. (1963). Fabry's disease: classification as a sphingolipidosis and partial characterization of a novel glycolipid. *Journal of Biological Chemistry*, **238**, 3148-3150.
- Sweeley, C. C., Kliensky, B., Krivit, W., and Desnick, R. J. (1972). Fabry's disease: glycosphingolipid lipidosis. In *The Metabolic Basis of Inherited Disease*, 3rd ed. pp. 663-687. Ed. by J. B. Stanbury, J. B. Wyngaarden, and D. S. Fredrickson. McGraw-Hill, New York.
- Urbain, G., Philippart, M., and Peresmans, J. (1969). Fabry's disease with hypogammaglobulinemia and without angiokeratomas. *Archives of Internal Medicine*, **124**, 72-76.
- Wallace, H. J. (1973). Anderson-Fabry disease. *British Journal of Dermatology*, **88**, 1-23.
- Wise, D., Wallace, H. J., and Jellinek, E. H. (1962). Angiokeratoma corporis diffusum: a clinical study of eight affected families. *Quarterly Journal of Medicine*, **31**, 177-205.

Requests for reprints to Dr M. W. Spence, Department of Pediatrics, Rm. C-R1, Clinical Research Centre, Dalhousie University, Halifax, Nova Scotia B3H 4H7.