

Meckel syndrome and the prenatal diagnosis of neural tube defects

MARY J. SELLER

From the Paediatric Research Unit, The Prince Philip Research Laboratories, Guy's Hospital Medical School, London SE1 9RT

SUMMARY Two fetuses, terminated after prenatal diagnosis of a neural tube defect, had Meckel syndrome. There have now been three fetuses with this syndrome in a series of 35 terminated because of open lesions of the neural tube. It is suggested that such therapeutically aborted fetuses represent a highly selected group, among which a rare condition like Meckel syndrome will be concentrated. The need for a detailed examination of all terminated fetuses is emphasised, for the identification of such an autosomal recessive condition alters the genetic counselling for a future pregnancy.

A fetus has previously been reported (Seller, 1975) which was terminated because the amniotic fluid alphafetoprotein (AFP) level was raised, and which had multiple abnormalities consistent with the stigmata of Meckel syndrome. There was an open encephalocele, which presumably accounted for the raised AFP in the amniotic fluid, large polycystic kidneys, polydactyly, micrognathia, microgenitalia, cleft palate, talipes, and flexion deformities of the arms. Meckel syndrome is attributed to an autosomal recessive gene (Mecke and Passarge, 1971), and affected infants are either stillborn or die shortly after birth. It is considered to be a rare condition, though more prevalent among Jews (Fried, 1973). However, since the first report (Seller, 1975), there have been several similar findings among fetuses selectively aborted because of a suspected neural tube defect after prenatal diagnosis (Chemke *et al.*, 1977; Kimball *et al.*, 1977; Shapiro *et al.*, 1977; W. H. Taylor, 1977, personal communication), and there have now been two further cases in this laboratory, both of which, like the first, were from non-Jewish Caucasian parents. This suggests that Meckel syndrome is perhaps more common among Gentiles than was previously thought.

Case reports

CASE 1

The mother, aged 22 years, gravida 3, para 1, was referred for genetic advice to the Paediatric Research Unit at Guy's Hospital. A diagnostic amniocentesis was indicated as her second pregnancy was said to have

resulted in an anencephalic. She was considered to be at a 1 in 25 risk of producing a second child with a neural tube defect. The parents were not blood relatives. At 17 weeks' gestation, the amniotic fluid alphafetoprotein level was 155 $\mu\text{g/ml}$ (normal range, 6 to 43 $\mu\text{g/ml}$), but the liquor was fairly heavily contaminated with fresh red blood cells, which a Kleihauer test showed to be fetal in origin. The maternal serum alphafetoprotein level was 200 ng/ml (95th centile, 115 ng/ml). At 18½ weeks' gestation the amniotic fluid AFP level was 150 $\mu\text{g/ml}$ (normal range, 6 to 25 $\mu\text{g/ml}$). The liquor was brown in colour and contained a few fresh red blood cells, of which approximately 20% were fetal. The maternal serum AFP level was 365 ng/ml (95th centile, 135 ng/ml). An open neural tube defect in the fetus was suspected, and an ultrasound examination (by Professor S. Campbell) at 20 weeks suggested there was an encephalocele. The pregnancy was terminated at 20½ weeks.

The non-macerated male fetus (Fig.) weighed 321 g and had a crown-rump length of 16 cm. He had an open occipital encephalocele, micrognathia, microphthalmia, low set ears, a cleft soft palate, and a short, thick tongue which was not developed anteriorly. The thorax was hypoplastic, the abdomen distended, and the phallus small. Both hands had six digits and a tag, the extra digit and tag being on the postaxial border. Both feet had five digits, but the left foot had an additional postaxial tag. There was a flexion deformity of both the arms and legs and bilateral talipes equinovarus. The legs were short distal to the knees because the long bones were dysmorphic. Apart from the encephalocele through the middle of the occipital

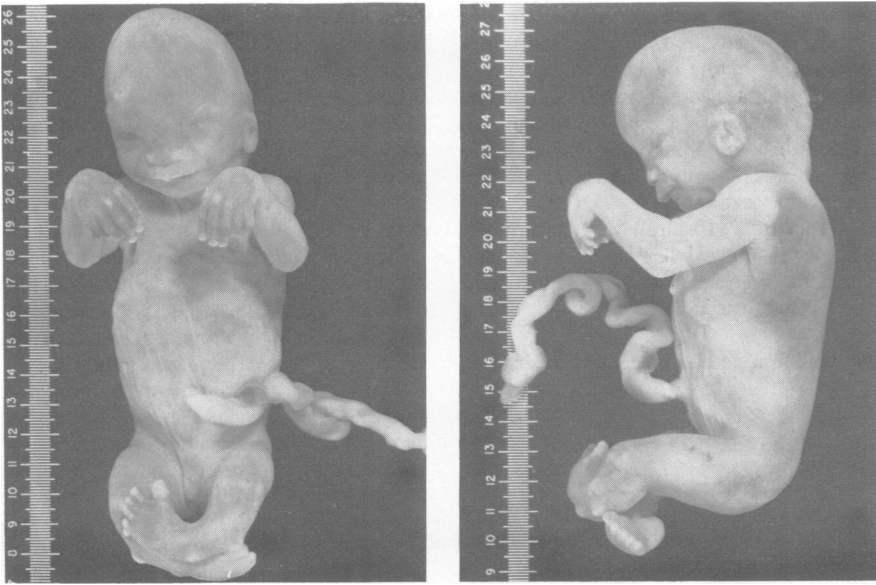


Fig. Fetus with open occipital encephalocele, microphthalmia, polydactyly, talipes equinovarus, and flexion deformities of the limbs: Meckel syndrome.

bone, there was a second subcutaneous lesion at the base of the occipital bone, which was continuous with a closed spina bifida involving the atlas, axis, C1, C2, and C3 vertebrae. The kidneys were enlarged (approximately three times the normal size) and polycystic, and there were large cysts close to the gonads. The internal genital tract was abnormal, consisting of a small, blind, bicornuate 'uterus' attached to the posterior wall of the bladder, and 'gonoducts' which ran from this sac to the gonads. The heart lay transversely in the thorax and there was a small ventricular septal defect; the right ventricle was hypoplastic and the left ventricle hyperplastic. The ascending aorta was bulbous and had thick muscular walls. There were eleven pairs of ribs. All other organs were macroscopically normal. Unfortunately, tissue culture for chromosome analysis failed. Histology of one gonad (by Dr G. A. K. Missen) showed it to be an immature testis.

The parents were healthy, non-Jewish, Caucasians.

CASE 2

This mother, aged 22 years, gravida 5, para 1, was also considered to have a 1 in 25 risk of producing a second child with a neural tube defect, since her third pregnancy was said to have resulted in a stillborn anencephalic with a meningocele. She had also had two early spontaneous abortions. Amniocentesis was performed at 18½ weeks. There was oligohydramnios and the liquor was severely contaminated

with fresh red blood cells, 99% of which were fetal in origin. The AFP level was 290 µg/ml, which was markedly raised (normal range for 18 weeks, 6 to 25 µg/ml), and was thought to indicate an open lesion of the neural tube, despite the contamination with fetal blood. In the experience of this laboratory, even the most severe blood staining in the absence of a fetal lesion is only associated with a rise of up to 120 µg/ml. An ultrasound examination at Guy's Hospital (by Ms Hilary Noakes) noted microcephaly and an encephalocele, and one at King's College Hospital (by Professor Stuart Campbell) suggested microcephaly and polycystic kidneys. At this stage more details on the first child with the neural tube defect were acquired. No necropsy had been performed, but it had been noted that the infant had polydactyly, a bifid tongue, teeth, and a cleft lip and palate. In view of this, and of the ultrasound findings in the present fetus, it was suspected that this fetus had Meckel syndrome. The pregnancy was terminated with prostaglandins at 20½ weeks.

The non-macerated male fetus weighed 270 g and had a crown-rump length of 15.5 cm. There was microcephaly and an open occipital encephalocele through which meninges were protruding. There was micrognathia, the tongue was not developed anteriorly, and the ears were simple and low set. There was ocular hypertelorism and an antimongoloid slant to the eyes. There were six fingers on each hand and six toes on each foot; in all cases the extra digit was on the post-

axial border. The fingernails were normal. There was bilateral talipes equinovarus and flexion deformities and minimal shortening of the distal segments of all limbs. The ulnae and tibiae were dysmorphic and the femora were bowed. The external genitalia were hypoplastic. The kidneys were enlarged approximately three times, they were polycystic and lacked fetal lobulation. The brain (examined by Dr J. Pryce-Davies, Queen Charlotte's Hospital) was abnormally small with malformed cerebral hemispheres showing irregular neuroblastic migration and poorly defined lateral ventricles. There was diastematomyelia of the lumbar spinal cord.

The parents were unrelated, healthy, non-Jewish, Caucasians.

Discussion

The partial limb reduction and polydactyly in these cases suggested that the Ellis-Van Creveld syndrome, which can also be diagnosed prenatally (Mahoney and Hobbins, 1977), should be considered as a differential diagnosis. However, this was rejected because the dwarfing of the distal part of the extremities was not severe, and there was no fingernail dystrophy. Furthermore, the three cardinal features of Meckel syndrome—encephalocele, polydactyly, and polycystic kidneys—were present, together with other malformations often associated with this condition, cleft palate, micrognathia, microphthalmia, and hypoplastic genitalia.

The three cases of Meckel syndrome of this laboratory were the fourth, fifteenth, and thirty-fifth abortuses, respectively, in a series of 35 fetuses which had been selectively terminated because of markedly raised AFP levels in the amniotic fluid. All other fetuses had straightforward anencephaly and/or spina bifida.

Holmes *et al.* (1976) studied 88 000 births in Boston from 1958 to 1972 and found 106 stillborn or liveborn infants with neural tube defects. Among these were five cases of Meckel syndrome, of which two were Jewish. This gives an overall incidence of 1 in 17 600 births, but this may be an artificially high estimate, for the total was derived from the hospital births of Boston and the abnormal from the whole population of the area. Fried (1973) suggested a minimum prevalence among Jews in Israel of 1 in 50 000.

The incidence of Meckel syndrome in the population studied here, which basically covers the south of England and includes relatively few Jews, could be of the order of 1 in 140 000 pregnancies. This is calculated taking into account the various recurrence risks of each of the 35 women. However, because of the very small numbers involved, the 95%

confidence limits show that the true incidence may be from 1 in 50 000 to 1 in 650 000 pregnancies. The figures also imply gene frequencies ranging from 0.0025 to 0.008, that is, 1 in 400 to 1 in 125.

This calculated incidence is relatively low, yet cases of Meckel syndrome are appearing quite frequently among fetuses therapeutically aborted for neural tube defects, whether of Jewish or Gentile parentage. This may be explained by the fact that such fetuses represent a highly selected population within which Meckel syndrome is concentrated. Further, unlike normal neural tube defects, there is no evidence to suggest that Meckel syndrome is lethal in early fetal life (Creasy and Alberman, 1976).

From their study of neonates, Holmes *et al.* (1976) suggest that 5% of neural tube defects may be examples of Meckel syndrome. While Welch (1976) considers this to be an underestimate, and Althouse and Kline (1976) think it an overestimate of the true situation, it is interesting to note that the present findings of three cases of Meckel syndrome out of 35 cases of neural tube defects (8.57%), and the findings of Kimball *et al.* (1977), where there were two cases out of 32 (6.25%), though both derived from a prenatal population, agree with the observations of Holmes *et al.* (1976).

Such figures are not negligible, and emphasise the need for a careful examination of all products of conception where there is a neural tube defect present, particularly those fetuses selectively aborted after prenatal diagnosis, to identify the lesions which form part of a syndrome, the inheritance of which is different from neural tube defects alone, and where the recurrence risk is much higher.

I am indebted to Professor Paul E. Polani, FRS, for valuable discussions concerning this manuscript. I am also grateful to Dr W. H. Taylor of the Department of Clinical Pathology, Liverpool Area Health Authority, for allowing me to quote his unpublished observations.

I thank the Spastics Society and the Department of Health and Social Security for financial support, Mrs Susan Embury and Mrs Nancy Garnham for technical assistance, and Mr Leon Kelberman for photography.

References

- Althouse, R., and Kline, J. (1976). Neural tube defects. *New England Journal of Medicine*, **294**, 1462.
- Chemke, J., Miskin, A., Rav-Acha, Z., Porath, A., Sagiv, M., and Katz, Z. (1977). Prenatal diagnosis of Meckel syndrome: alpha-fetoprotein and beta-trace protein in amniotic fluid. *Clinical Genetics*, **11**, 285-289.
- Creasy, M. R., and Alberman, E. D. (1976). Congenital malformations of the central nervous system in spontaneous abortions. *Journal of Medical Genetics*, **13**, 9-16.
- Fried, K. (1973). Relatively high prevalence of the Meckel syndrome among Jews. *Israel Journal of Medical Science*, **9**, 1399.

- Holmes, L. B., Driscoll, S. G., and Atkins, L. (1976). Etiologic heterogeneity of neural tube defects. *New England Journal of Medicine*, **294**, 365-369.
- Kimball, M. E., Milunsky, A., and Alpert, E. (1977). Prenatal diagnosis of neural tube defects. III. A re-evaluation of the alpha-fetoprotein assay. *Obstetrics and Gynecology*, **49**, 532-536.
- Mecke, S., and Passarge, E. (1971). Encephalocoele, polycystic kidneys and polydactyly as an autosomal recession trait simulating certain other disorders: the Meckel syndrome. *Annales de Génétique*, **14**, 97-103.
- Mahoney, M. J., and Hobbins, J. C. (1977). Prenatal diagnosis of chondroectodermal dysplasia (Ellis-van Creveld syndrome) with fetoscopy and ultrasound. *New England Journal of Medicine*, **297**, 258-260.
- Seller, M. J. (1975). Prenatal diagnosis of a neural tube defect: Meckel syndrome. *Journal of Medical Genetics*, **12**, 109-110.
- Shapiro, L. J., Kaback, M. M., Todmey, K. E., Sarti, D., Luther, P., and Cousins, L. (1977). Prenatal diagnosis of the Meckel syndrome: use of serial ultrasound and alpha-fetoprotein measurements. *Birth Defects: Original Article Series*, **13**, 267-272. The National Foundation—March of Dimes, New York.
- Welch, J. P. (1976). Neural tube defects. *New England Journal of Medicine*, **294**, 1461-1462.

Requests for reprints to Dr Mary J. Seller, Paediatric Research Unit, The Prince Philip Research Laboratories, Guy's Hospital Medical School, London SE1 9RT.