

Spinal blocks are a very common treatment and diagnostic procedure for spinal pain. Despite being a safe procedure, serious complications can occur, and when they do, they can be devastating. Infections after spinal blocks are rare, but should be considered by the doctor, allowing prompt action. We report a case and a literature review that will help in treatment and diagnosis of this pathology.

KEY CONCEPTS:

Epidural injections are a common procedure in daily practice. Major complications such as epidural abscess are very infrequent, especially in young and healthy people but can be devastating. This case report and literature review provide an update of the topic, highlighting the importance of a high diagnostic suspicion to avoid delays and favor adequate and timely treatment.

Recibido: 2022-04-21 Aceptado: 2022-06-11

DOI: <http://dx.doi.org/10.31053/1853.0605.v80.n1.37392>



<https://creativecommons.org/licenses/by-nc/4.0/>

©Universidad Nacional de Córdoba

Extensive spinal epidural abscess after nerve root injection in a young non-immunocompromised Patient. Case Report and Literature Review.

Fernando Holc^{1,2}; Agustín Albani¹; Gastón Camino Willhuber¹; Gonzalo Kido¹; Carlos Sola¹; Marcelo Gruenberg¹; Matías Pereira Duarte¹

- 1- Instituto de ortopedia y traumatología "Carlos E. Ottolenghi" Hospital Italiano de Buenos Aires, Argentina
- 2- mail de contacto: fernando.holc@hospitalitaliano.org.ar

RESUMEN

Introduction Epidural injections are frequent and safe procedures. Severe complications are infrequent, and they have been reported in elderly comorbid patients with predisposing factors. The objectives of this work are to present a case of an extensive epidural lumbar abscess in a young non-comorbid male patient after a therapeutic L5-S1 injection and a literature review about this subject.

Case Presentation: An otherwise healthy 24-year-old man who present a case of an extensive epidural lumbar abscess after a therapeutic nerve root block due to a disc herniation. After 7 days of fever and low back pain, he required two surgical interventions and intravenous antibiotic therapy.

We reviewed 18 patients with epidural abscess consequence of spinal injections. Their mean age was 54.5 y.o, 66.5% were male, and 66.5% had at least one predisposing risk factor. Symptoms Onset occurred at 8 days on average after the procedure, but the correct diagnosis was made at the 25th-day average. Only 22% presented the classic diagnostic triad, the most frequently isolated germ was Staphylococcus Aureus (66%) and 89% were treated surgically with a 33% rate of complete recovery, 17% mortality and 28% remained with neurological sequelae.

Conclusion: Epidural abscesses are infrequent and serious, complication after spinal diagnostic and therapeutic injections, even in young patients without comorbidities. We consider it fundamental to maintain a diagnostic suspicion, even in this subgroup of patients.

Level of evidence: V

Key words: epidural abscess; spine; infections; injections epidural.

ABSTRACT

Absceso epidural espinal posterior a bloqueo terapéutico en un paciente joven sin factores de riesgo. Reporte de caso y revisión de la Literatura.

Introducción: Los bloqueos perirradiculares son una práctica habitual y segura. Las complicaciones severas, como los abscesos epidurales, son infrecuentes y han sido reportadas en pacientes añosos con comorbilidades o factores predisponentes. El objetivo de este trabajo es presentar un paciente joven sin antecedentes con diagnóstico de absceso epidural posterior a un bloqueo terapéutico y la revisión de la literatura al respecto.

Presentación del caso: Un hombre de 24 años, previamente sano, presenta un caso de absceso epidural lumbar extenso, luego de un bloqueo perirradicular por una hernia de disco. Tras 7 días de fiebre y lumbalgia, precisó dos intervenciones quirúrgicas y antibioterapia intravenosa.

Recabamos la información de 18 casos junto al nuestro, de pacientes con diagnóstico de absceso epidural como consecuencia de una infiltración espinal. El promedio de edad de los pacientes fue de 54,5 años, 66,5% fueron de sexo masculino y 66,5% presentaba al menos un factor de riesgo predisponente. La aparición de síntomas luego del bloqueo ocurrió en promedio a los 8 días, pero el diagnóstico de absceso se realizó a los 24 días en promedio. La tríada diagnóstica clásica solo estuvo presente en el 22%, el germen más frecuentemente aislado fue el Staph. aureus (66%) y un 89% fue tratado de manera quirúrgica con una tasa del 33% de recuperación completa, 17% de mortalidad y 28% de secuela neurológica. **Conclusión:** Los abscesos epidurales son una complicación infrecuente, grave y rara de los procedimientos diagnósticos y terapéuticos espinales, incluso en pacientes jóvenes sin comorbilidades. Consideramos menester mantener la sospecha diagnóstica, incluso en este subgrupo de pacientes.

Nivel de evidencia: V

Palabras Clave: absceso epidural; columna vertebral, infecciones; inyecciones epidurales.

Abscesso epidural espinhal extenso após injeção na raiz do nervo em um paciente jovem não imunocomprometido. Relato de caso e análise literária.

Introdução: As injeções epidurais são procedimentos frequentes e seguros. Complicações graves são infrequentes e foram relatadas em pacientes idosos com comorbidades com fatores predisponentes. Os objetivos deste trabalho são apresentar um caso de abscesso lombar epidural extenso em paciente jovem não comórbido após injeção terapêutica de L5-S1 e revisão da literatura sobre o assunto.

Apresentação do caso: Um homem de 24 anos, saudável, que apresenta um caso de abscesso epidural lombar extenso após um bloqueio terapêutico de raiz nervosa devido a uma hérnia de disco. Após 7 dias de febre e lombalgia, necessitou de duas intervenções cirúrgicas e antibioticoterapia endovenosa. Revisamos 18 pacientes com consequência de abscesso epidural de injeções espinhais. A idade média deles era 54,5 anos, 66,5% eram do sexo masculino e 66,5% tinham pelo menos um fator de risco predisponente. O início dos sintomas ocorreu em média 8 dias após o procedimento, mas o diagnóstico correto foi feito em média no 25º dia. Apenas 22% apresentaram a tríade diagnóstica clássica, o germe mais isolado foi o *Staphylococcus Aureus* (66%) e 89% foram tratados cirurgicamente com 33% de recuperação completa, 17% de mortalidade e 28% permaneceram com sequelas neurológicas.

Conclusão: Os abscessos epidurais são infrequentes e graves, complicações após o diagnóstico de coluna vertebral e injeções terapêuticas, mesmo em pacientes jovens sem comorbidades. Consideramos fundamental manter a suspeita diagnóstica, mesmo neste subgrupo de pacientes.

Nível de evidência: V

Palavras-chave: abscesso epidural; coluna vertebral; infecções; injeções epidurais.

INTRODUCTION

Epidural injections (EI) have become an irreplaceable diagnostic and therapeutic tool worldwide. The complication rate of EI varies from 0 to 9.6%.⁽¹⁾ The majority are considered minor with spontaneous resolution within the first 24 hours (vasovagal syndrome, nausea, headache, transient lower limbs weakness, puncture site pain). Major complications, such as vascular injuries, permanent neurological injury, or infections are extremely rare.⁽²⁾ Epidural abscess (EA) accounts for one of the most serious and feared. The evidence available on EA as a consequence of EI is limited to case reports and small case series in elderly comorbid patients with multiple risk factors.⁽³⁾ The objective of this work is to present a case of an extensive epidural lumbar abscess after a therapeutic nerve root block (NRB), in a young patient without comorbidities. We detailed his clinical presentation, treatment, and outcomes

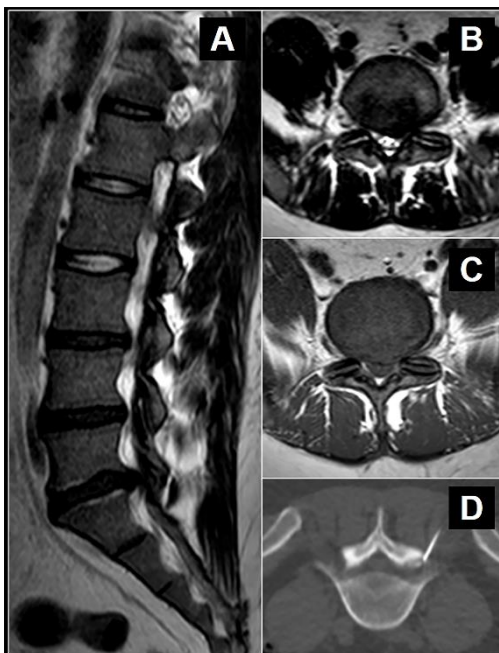
at 12 months of follow-up. This case report was prepared following the CARE Guidelines (4) and additionally, a literature review was performed.

MATERIAL AND METHODS

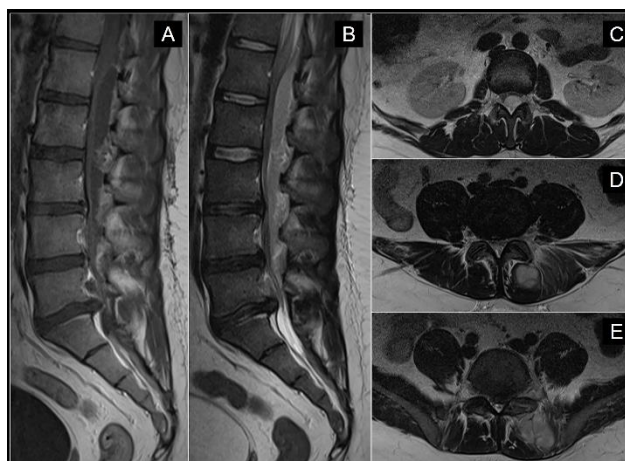
We describe the case of a patient diagnosed with an EA after a nerve root block (NRB), his clinical presentation, treatment and outcomes at 12 months of follow-up. We conducted a literature review in Medline databases for EA as a consequence of spinal diagnostic/therapeutic infiltrations. Mesh terms "spine", "epidural abscess", "Selective nerve root block" and "epidural/transforaminal injection" were used. After most relevant articles selection by title and abstract, they were analyzed completely, adding those references that fulfilled the inclusion criteria.

CASE PRESENTATION

A 24-year-old male patient was admitted at the emergency room with a 7 days history of fever, low back pain and bilateral lower limb radicular pain. Fifteen days prior to the clinical presentation, the patient underwent a L5-S1 CT-guided NRB due to a disc herniation at that level that was refractory to conservative treatment (Figure 1). Physical examination showed increased lumbar tenderness, positive bilateral Lasegue, paresthesia in the left plantar region and no motor deficit. Laboratory analysis showed a white blood cell account of 21,500 cells/dl (84% polymorphonuclear), erythrocyte sedimentation rate of 48 mm/h, and C-reactive protein of 233 mg/dl. After these findings, blood cultures were requested, which were later positive for methicillin-sensitive *Staphylococcus Aureus* (MSSA), and emergency imaging studies were requested.



Lumbosacral spine radiographs showed a narrowed L5-S1 intervertebral space. Magnetic resonance imaging (MRI) with gadolinium showed a posterior epidural collection from T12 to L5 and a left paravertebral collection related to the ipsilateral L5-S1 articular facet joint (Figure 2). Empirical antibiotic treatment (1g b.i.d. of vancomycin and 2g t.i.d. of ceftazidime) and emergency surgery were indicated.



The abscess was drained using two midline dorsal incisions, at L2-L3 and L5-S1 levels. The paravertebral collection was drained and the intracanal purulent material was debrided with a K-30 probe and saline solution, caudally and cranially until clear debit was obtained. Samples from collections were sent for culture. The left S1 root had a tense appearance as a result of the already known hernia, thus a microdiscectomy was performed. Two drains were left in place.

During the first postoperative days, the patient improved progressively. The cultures analysis resulted in positives for MSSA and antibiotic therapy was rotated to cefazolin 2g. b.i.d according to antibiogram results. On the 6th postoperative day, the patient recommenced with fever of 38.5° and chills. A new MRI showed the persistence of the epidural collection. Due to the persistence of the symptoms within antibiotic treatment, and other possible infectious locations ruled-out, a surgical re-exploration was conducted. Using the same incisions, decompression was extended at L2-L3 level. An intracanal hematoma with purulent areas was identified and drained. Antibiotic regimen was maintained, the patient evolved well and was discharged on the 5th day to complete intravenous treatment for six weeks with ceftriaxone 2g b.i.d. and rifampicin 300mg b.i.d.

At 12 months follow-up, the patient continued asymptomatic, no sequelae were found and serological parameters remained normal.

LITERATURE REVIEW

Eighteen cases of EA as a complication of spinal injections were analyzed, including the one presented here (Table 1). The average age was 54.5 years-old (21-84), 12 (66.5%) were male. Twelve patients (66.5%) had at least one risk factor for infections, 3 of them (16.5%) had more than one associated comorbidity and in 6 cases (33%) the data was not available. The most prevalent symptoms prior to the procedure were back pain (8 cases) and back pain associated with radicular pain (7 cases) (Table 2).

Table 1 - Patients Data

N	Author	Year	Gender	Age	Comorbidities	Injection Level	Abscess Level	Meningeal symptoms	Back Pain	Fever	Time from Injection till symptoms' onset	Time from injection till final diagnosis	Surgical treatment	Antibiotic treatment	Culture	Follow up (months)	Evolution
1	Shealy (16)	1966	M	58	Oncologic Disease	Lumbar	L5-S1	Yes	Yes	Yes	N/A	120	Yes - NS	Penicilin and chloramphenicol	N/A	6	Death due to cancer progression
2	Chan et al (17)	1989	M	56	DM 2	Lumbar	C3-L4	No	Yes	Yes	2	9	Laminectomy	Yes - NS	SA	3	Paraplegia
3	Goucke et al (3)	1990	F	65	DM 2, obesity, Previous spine surgery	Lumbar	T12-L5	No	Yes	No	21	28	Laminectomy	Yes - NS	SA	2	Death due to multi organ failure
4	Waldman (18)	1991	M	55	N/A	Cervical	Cervical	Yes	No	Yes	3	3	Laminectomy	Yes - NS	MSSA	6	Complete recovery
5	Parlier-Cuau et al (19)	1993	N/A	N/A	N/A	Lumbar	Lumbar	N/A	N/A	N/A	N/A	N/A	Yes - NS	N/A	N/A	N/A	N/A
6	Bromage (20)	1993	F	61	N/A	Dorsal	T3	No	Yes	Yes	7	13	Laminectomy	N/A	N/A	N/A	Quadriplegia
7	Mamourian et al (21)	1993	F	84	Oncologic Disease	Lumbar	L4-S2	Yes	Yes	No	14	14	Yes - NS	N/A	SA	N/A	Death
8	Knight et al (22)	1997	M	53	DM 2	Lumbar	Lumbar	No	Yes	Yes	21	25	Laminectomy	Yes - NS	MSSA	6	Paraplegia
9	Goris et al (15)	1998	M	44	N/A	Cervical	C3-T4	Yes	Yes	No	2	N/A	Laminectomy	Yes - NS	MRSA	N/A	N/A
10	Kluba et al (23)	1998	M	21	N/A	lumbar	Lumbar	No	Yes	No	3	N/A	Laminectomy	N/A	MRSA	N/A	Complete recovery
11	Yamaguchi et al (2)	1999	M	71	Oncologic Disease, DM 2	Lumbar	L5-S1	No	Yes	Yes	2	N/A	Percutaneous drainage	Yes - NS	Beta hemolytic <i>Streptococcus</i>	3	Paraparesis
12	Kaul et al (13)	2000	M	26	N/A	Lumbar	L3-S1	Yes	Yes	No	7	N/A	Laminectomy	Cefalosporin 3rd gen.	Negative	N/A	N/A
13	Koka et al (6)	2002	F	69	Rheumatic disease, previous spine surgery	Lumbar	L1-L3	No	Yes	Yes	4	11	No	vancomycin + nafcillin	SA	6	Complete recovery
14	Alcock et al (14)	2003	F	80	Previous spine surgery	Lumbar	L3-L5	No	Yes	No	2	10	Yes - NS	N/A	N/A	N/A	Paraparesis
15	Hooten et al (7)	2004	M	70	Rheumatic disease	Lumbar	L2-L3	Yes	Yes	No	21	25	No	Yes - NS	MSSA	5	Complete recovery / Low back pain

16	Kabbara et al (12)	2004	M	44	Previous spine surgery	Lumbar	L4-L5	No	Yes	Yes	6	21	Yes - NS	Vanco mycin	MRS A	12	Complete recovery
17	LaFave et al (11)	2019	M	45	Obesity	Lumbar	C1-C5	No	Yes	No	2	N/A	Yes - NS	Yes - NS	MRS A	N/A	Complete recovery
18	HIBA	2019	M	24	-	Lumbar	T12-L5	No	Yes	Yes	7	15	Laminectomy + Microdiscectomy	Vanco mycin + ceftazidime + ceftroxime	MSS A	12	Complete recovery

N/A: Not/Available, NS: Not Specified, DM: Diabetes Mellitus, SA: Staphylococcus aureus, MSSA: Methicillin-Sensitive *Staphylococcus aureus*, MRSA: Methicillin-Resistant *Staphylococcus aureus*.

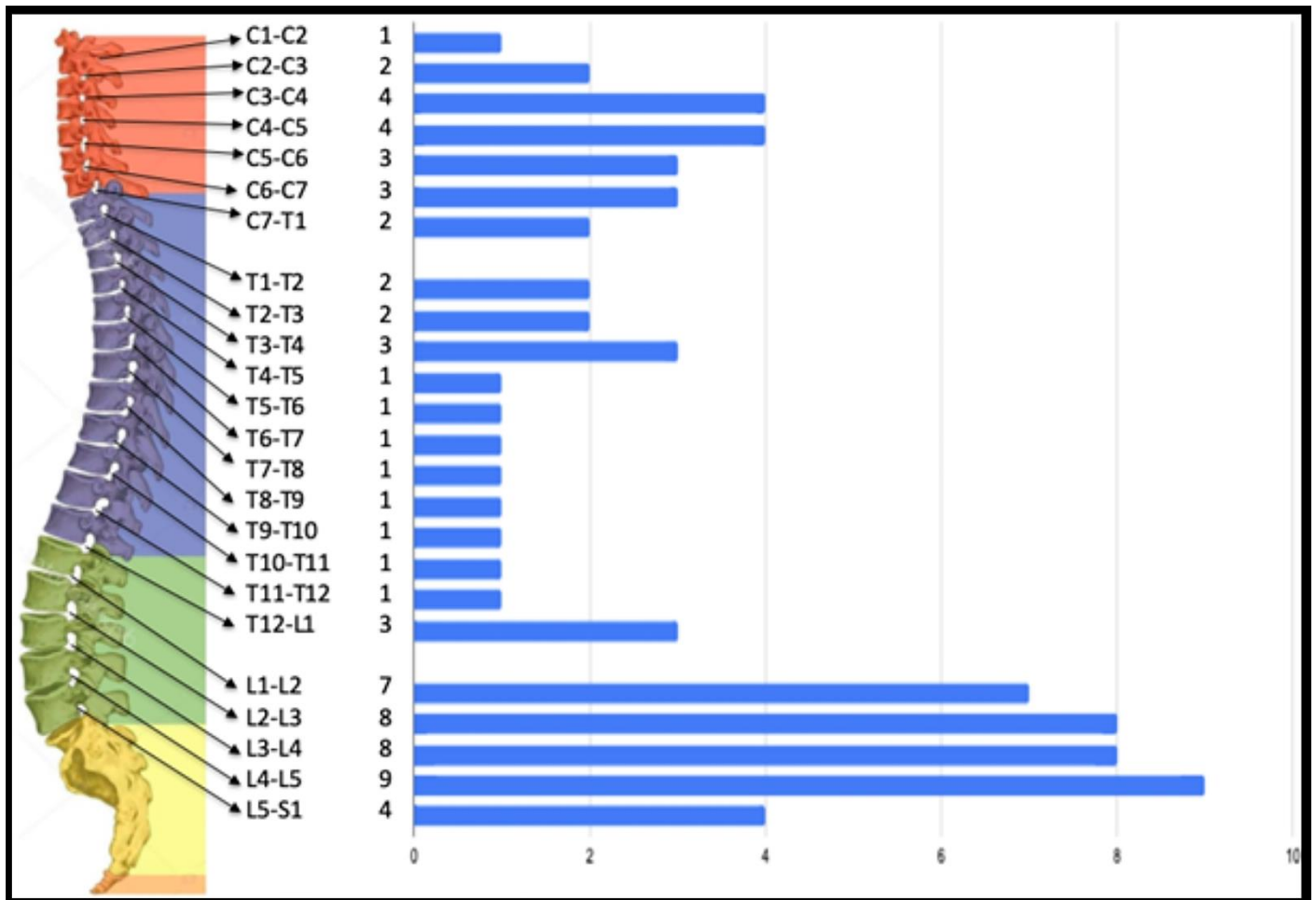
Table 1. Summary of Reported Cases of Epidural Abscess After Epidural Corticosteroid Injections

Table 2 - Demographic Data

		N	%
Age (Years)		54,5	(21-84)
Gender			
	Male	12	66,50%
	Female	5	27,50%
	N/A	1	5,50%
Comorbidities			
	Diabetes Mellitus	4	22%
	Oncologic Disease	3	17%
	Previous spine surgery	4	22%
	Obesity	3	17%
	Rheumatic disease	2	11%
	N/A	6	33%
Symptoms before NRB			
	Low back pain	8	45%
	Neck pain	1	5,50%
	Low back pain + radicular pain	7	38,40%
	Cervical radiculopathy	1	5,50%
	Dorsal radiculopathy	1	5,50%
N/A= Not/Available			

Table 2. Summary of the demographic data of patients reported in the literature with main symptoms before blockade.

94% of the cases presented with pain at the affected vertebral region as the main symptom, 50% had febrile records associated and 33% meningeal symptoms. The average time from puncture to symptoms onset was 8 days and 25 days to definitive diagnosis. In 89% of cases, surgical treatment was reported, only 2 patients were medically treated with antibiotics. The most frequently isolated germ was *Staphylococcus aureus* in 12 patients (66.5%). Six authors reported a complete recovery of the patients, 3 patients died and 5 remained with a neurological sequela. The Lumbar spine was the most affected region (83.33%, 15/18 cases) and L4-L5, the most compromised level, in accordance with the fact that 83% of the procedures were performed at this zone (Figure 3).



DISCUSSION

We present a case of an extensive epidural abscess after a therapeutic EI in a non-immunocompromised young patient and a literature review on this subject.

Twelve out of 18 cases presented at least 1 risk factor for infection, such as diabetes, advanced oncological disease, immunosuppression, chronic use of steroids and previous surgeries on the spine. The most frequent comorbidity found was Diabetes Mellitus, in 4 patients.

Early diagnosis is key for adequate treatment and reduce morbidity, mortality and potentially fatal sequela. Usually, symptoms are nonspecific and only 15% of patients present the classic diagnostic triad of epidural abscess: fever, back pain, and neurological deficit, delaying diagnosis in up to 75% of cases.(5) According to our analysis, this triad occurred in 22% and the definitive diagnosis was made on the 25th day on average (3-120) from the symptoms' onset. The most reported initial symptoms were: low back pain or pain in the abscess region (89%), fever (50%) and meningeal symptoms (33%). This demonstrates the importance of clinical suspicion, prior to more severe symptoms appearing.

The presence of red flags and risk factors such as advanced age, fever, non-traumatic pain, spinal

injections or recent procedures, reinforce the need to investigate in depth these patients at early stages.

Although available evidence supports surgical drainage and empirical antibiotic therapy as initial treatment of choice, some authors recommend medical treatment alone in very specific situations (6) such as those who refuse surgery, who have high surgical risk, those with paralysis of more than 24-36 hours of evolution, considering it irreversible, and those with entire spine involvement, where decompression is impractical and mechanically non-viable. Patients without neurological deficit could be included in this category if the germ has been identified and their clinical condition can be closely monitored. Only 2 cases of our review were non-surgically treated, corresponding to patients aged around 70 years-old, both with an underlying immunological disease.(7,8) In both, a Staphylococcus aureus was isolated and they evolved favorably at 6 and 12 months of follow-up. However, the potential risk of emerging germs must be considered in those with non-response to empiric antibiotics. (9)

Recently, Shah et al.(10) proposed an imagenological classification for the EA, however, it was developed based on the cervical location exclusively, so a classification that encompasses the entire spine and that provides a clinical and prognostic assessment would be more useful.

The microdiscectomy performed during the first surgical intervention is highly controversial. We considered the resolution of the original problem (extruded nucleus pulposus hernia) as the primary goal, in order to reduce the probability of a poor evolution due to persistent pain. We acknowledge the risks of invading a theoretically sterile space in the context of an adjacent infection which could lead to iatrogenic disc contamination and associated discitis or spondylodiscitis. Taking all of the above mentioned into consideration, and with the patient's and his family's consent, we decided to perform the microdiscectomy after a thorough debridement of the affected area. In our review, we did not find any evidence regarding this matter. We are not able to create an evidence-based statement but only a suggestion based on the authors' experience, which was satisfactory.

We recognize that this work has its limitations. First, we conducted a literature review without applying the PRISMA workflow. Although we could have lost some publications, we have included all cases reported to date, applying detailed criteria in each documented patient and obtaining all relevant information available. On the other hand, the quality of evidence gathered in the literature is directly related to the frequency of this condition. Finally, although we cannot generalize our conclusions due to the low level of evidence, we can offer a useful guide for the diagnosis, evaluation, and treatment of these patients.

CONCLUSION

Epidural abscess as a complication of a NRB is infrequent and severe. 66% of cases had at least one risk factor, 22% presented with the classical diagnostic triad and 66% were caused by *Staphylococcus aureus* sp. The mortality rate was 17% and 33% had a complete recovery with a wide range of neurologic sequelae. A high diagnostic suspicion is of utmost importance to avoid delays and favor adequate and timely treatment.

BIBLIOGRAPHY

1. El-Yahouchi CA, Plastaras CT, Maus TP, Carr CM, McCormick ZL, Geske JR, Smuck M, Pingree MJ, Kennedy DJ. Adverse Event Rates Associated with Transforaminal and Interlaminar Epidural Steroid Injections: A Multi-Institutional Study. *Pain Med.* 2016 Feb;17(2):239-49. doi: 10.1111/pme.12896.
2. Yamaguchi M, Kawakubo A, Ide R, Hara K, Sumikawa K. [Epidural abscess associated with epidural block in a patient with immunosuppressive disease]. *Masui.* 1999 May;48(5):506-8.
3. Goucke CR, Graziotti P. Extradural abscess following local anaesthetic and steroid injection for chronic low back pain. *Br J Anaesth.* 1990 Sep;65(3):427-9. doi: 10.1093/bja/65.3.427.
4. Riley DS, Barber MS, Kienle GS, Aronson JK, von Schoen-Angerer T, Tugwell P, Kiene H, Helfand M, Altman DG, Sox H, Werthmann PG, Moher D, Rison RA, Shamseer L, Koch CA, Sun GH, Hanaway P, Sudak NL, Kaszkin-Bettag M, Carpenter JE, Gagnier JJ. CARE guidelines for case reports: explanation and elaboration document. *J Clin Epidemiol.* 2017 Sep;89:218-235. doi: 10.1016/j.jclinepi.2017.04.026.
5. Babic M, Simpfendorfer CS, Berbari EF. Update on spinal epidural abscess. *Curr Opin Infect Dis.* 2019 Jun;32(3):265-271. doi: 10.1097/QCO.0000000000000544.
6. Savage K, Holtom PD, Zalavras CG. Spinal epidural abscess: early clinical outcome in patients treated medically. *Clin Orthop Relat Res.* 2005 Oct;439:56-60. doi: 10.1097/01.blo.0000183089.37768.2d.
7. Koka VK, Potti A. Spinal epidural abscess after corticosteroid injections. *South Med J.* 2002 Jul;95(7):772-4.
8. Hooten WM, Kinney MO, Huntoon MA. Epidural abscess and meningitis after epidural corticosteroid injection. *Mayo Clin Proc.* 2004 May;79(5):682-6. doi: 10.4065/79.5.682.
9. Valencia-Mesias GA, Cano-Calero IN, Castillo-Soto A. Fasciitis by *Lactococcus garvieae* on an immunosuppressed patient by Diabetes Mellitus. *Microbes Infect Chemother.* el 7 de diciembre de 2021;1:e1245-e1245.
10. Shah AA, Yang H, Harris MB, Schwab JH. A Classification System for Spinal Cord Compression and its Association With Neurological Deficit in Spinal Epidural Abscess. *Clin Spine Surg.* 2019 Apr;32(3):E126-E132. doi: 10.1097/BSD.0000000000000746.
11. LaFave J, Bramante R. Upper Cervical Epidural Abscess Resulting in Respiratory Compromise After Lumbar Steroid Injection. *J Emerg Med.* 2019 Jul;57(1):66-69. doi: 10.1016/j.jemermed.2019.02.014.
12. Kabbara A, Rosenberg SK, Untal C. Methicillin-resistant *Staphylococcus aureus* epidural abscess after transforaminal epidural steroid injection. *Pain Physician.* 2004 Apr;7(2):269-72.
13. Kaul S, Meena AK, Sundaram C, Reddy JM, Naik RT, Murthy JM. Spinal extradural abscess following local steroid injection. *Neurol India.* 2000 Jun;48(2):181-3.
14. Alcock E, Regaard A, Browne J. Facet joint injection: a rare form cause of epidural abscess formation. *Pain.* 2003 May;103(1-2):209-10. doi: 10.1016/s0304-3959(02)00326-3.
15. Goris H, Wilms G, Hermans B, Schillebeeckx J. Spinal epidural abscess complicating epidural infiltration: CT and MR findings. *Eur Radiol.* 1998;8(6):1058. doi: 10.1007/s003300050514.
16. Shealy CN. Dangers of spinal injections without proper diagnosis. *JAMA.* 1966 Sep 26;197(13):1104-6.
17. Chan ST, Leung S. Spinal epidural abscess following steroid injection for sciatica. Case report. *Spine (Phila Pa 1976).* 1989 Jan;14(1):106-8. doi: 10.1097/00007632-198901000-00021.
18. Waldman SD. Cervical epidural abscess after cervical epidural nerve block with steroids. *Anesth Analg.* 1991 May;72(5):717-8. doi: 10.1213/00000539-199105000-00033.
19. Parlier-Cuau C, Carlier RY, David P, Silva M, Doyon D. Abscess sous-dural. Complication rare d'une infiltration épidurale. A propos d'un cas et revue de la littérature [Subdural abscess. Rare complication of epidural infiltration. Apropos of a case and review of the literature]. *J Radiol.* 1993 Apr;74(4):205-9. French
20. Bromage PR. Spinal extradural abscess: pursuit of vigilance. *Br J Anaesth.* 1993 Apr;70(4):471-3. doi: 10.1093/bja/70.4.471.
21. Mamourian AC, Dickman CA, Drayer BP, Sonntag VK. Spinal epidural abscess: three cases following spinal epidural injection demonstrated with magnetic resonance imaging. *Anesthesiology.* 1993 Jan;78(1):204-7.
22. Knight JW, Cordingley JJ, Palazzo MG. Epidural abscess following epidural steroid and local anaesthetic injection. *Anaesthesia.* 1997 Jun;52(6):576-8. doi: 10.1111/j.1365-2044.1997.156-az0161.x.
23. Kluba T, Martini F. Spinaler epiduraler Abszess nach Steroid-Injektion bei Lumboischialgie. Vol. 23, Aktuelle Rheumatologie. 1998. p. 182-3.

Limitaciones de responsabilidad:

La responsabilidad del trabajo es exclusivamente de quienes colaboraron en la elaboración del mismo.

Conflicto de interés:

Ninguno.

Fuentes de apoyo:

La presente investigación no contó con fuentes de financiación

Originalidad:

Este artículo es original y no ha sido enviado para su publicación a otro medio de difusión científica en forma completa ni parcialmente.

Cesión de derechos:

Quienes participaron en la elaboración de este artículo, ceden los derechos de autor a la Universidad Nacional de Córdoba para publicar en la Revista de la Facultad de Ciencias Médicas.

Contribución de los autores:

Quienes participaron en la elaboración de este artículo, han trabajado en la concepción del diseño, recolección de la información y elaboración del manuscrito, haciéndose públicamente responsables de su contenido y aprobando su versión final.