

Familial dystonic choreoathetosis with myokymia; a sleep responsive disorder

Edward Byrne, Owen White, Mark Cook

Abstract

A family is presented with paroxysmal dystonic choreoathetosis transmitted as a dominant trait over five generations. The family is unusual in the marked responsiveness of the episodes to short periods of sleep in several members, in the very variable age of onset, and in the association with prominent myokymia in some cases. These overlap features suggest a link between paroxysmal dystonic choreoathetosis and familial paroxysmal ataxia with myokymia.

Familial disorders with paroxysmal abnormalities of motor regulation include paroxysmal kinesigenic choreoathetosis where sudden movement, the anticipation of movement or startle, may precipitate episodes of shortlived choreoathetosis,¹ and the rarer paroxysmal dystonic choreoathetosis where trigger factors are less well-defined and episodes usually more protracted.² The paroxysmal choreoathetoses are considered to be distinct from the familial periodic ataxia syndrome³ and its variant, the syndrome of familial paroxysmal ataxia and continuous myokymia.⁴ In this report we present a family with autosomal dominant paroxysmal dystonic choreoathetosis where a history of rapid alleviation of episodes by very short periods of sleep in several members suggests a link with abnormal sleep mechanisms and a finding of myokymia in several members suggest overlap with other paroxysmal syndromes.

Case histories (The family tree is shown in the figure)

Case II was born in Scotland near Edinburgh and emigrated to Australia in her early 20s and worked as a nurse maid. Her daughter (II4) remembers her mother as having the same type of attacks that she herself had. No information is available about the age of onset. Case II migrated to Australia, circa 1880. She had eight children but information is available only on II6 and her descendants.

Case II6 was the sixth of eight children. She began to get spasms of her limbs as a child and they persisted all through her life, probably getting less severe with age. She died aged 56, cause of death unknown.

Case III1 was the first child of III6, a girl, died at the age of five and had no known neurological problems. The second child, a son (III2), is alive and well at the age of 80 with no known neurological problems. The third child (III3), a boy, was asymptomatic until the age of 40. At that age, he began to notice facial tightness followed by grimacing sometimes, but not always, provoked by excitement or tension. Facial grimacing was the most prominent feature of the early attacks but from the beginning he was also aware of uncontrollable movement of his limbs affecting the arms more than the legs. In early attacks this took the form of muscle stiffening with controllable jerking movements developing in later attacks. These were of a choreoathetoid type. Both sides were equally affected. The attacks have shown no tendency to become less frequent over the years and generally they last until the patient falls asleep. He has a warning of a feeling of tightness in his muscles before the fully evolved attack begins which enables him to withdraw into his own room. He can always fall asleep almost immediately, even when an attack begins in the middle of the day, and finds that a few minutes of sleep is sufficient to abolish the attack completely. He feels he must fall asleep completely to abolish an attack. Episodes have not been provoked by alcohol, caffeine, startle or sudden movement. The patient developed maturity-onset diabetes in his late 50s and in his early 70s developed numbness in his feet. He had a stroke in his 70s which resulted in weakness of the left hand.

On examination, aged 76, he had mild global weakness of the left hand in keeping with the history of stroke. There was evidence of a distal sensory neuropathy with depression of pin-prick and vibration sense over his feet and proprioceptive impairment in the toes. Ankle

St Vincent's Hospital,
Melbourne
Department of
Neurology
E Byrne
M Cook

Monash Medical
Centre, Melbourne,
Australia
Department of
Neurology
O White

Correspondence to:
Professor Byrne, Neurology
Department, St Vincent's
Hospital, Fitzroy,
Melbourne 3065, Australia

Received 13 February 1991.
Accepted 10 April 1991

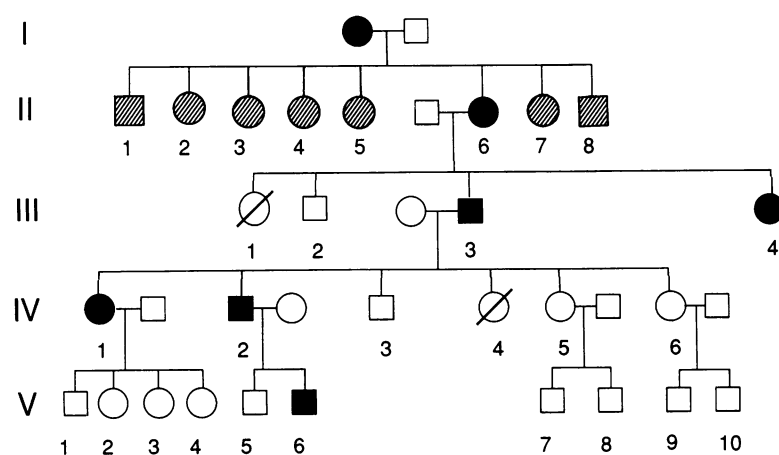


Figure Family tree showing affected cases (black) and unaffected cases (white). Information is incomplete in the second generations of the family in Australia. (Shaded cases) Cases III1 and IV4 died in childhood.

reflexes were absent. Occasional fasciculations were evident in the anterior tibial muscles and gastrocnemii bilaterally. No myokymia was evident either clinically or with electromyographic studies.

Case III4 The fourth child of II6, a girl, began to get attacks at the age of nine or 10 with uncontrollable movements of her limbs and face. She would have a feeling of apprehension before the attacks began enabling her to retire to her room and although the attacks were quite frequent other family members did not know she had them until after the birth of an affected niece when she recognised that the niece's episodes were similar to her own. The attacks were more frequent during periods of tension and are alleviated by rest. Rest on a bed for a few minutes improved the episodes. She isolates herself until the attack passes off. The episodes are associated with a feeling of discomfort and she is unable to sleep.

Case IV1 The eldest child of patient III3, a girl, had stiffening of the neck and trunk muscles as a small baby. At the age of eight months, she began to get episodes with hyperextension of the neck and trunk, flexion of the elbows, wrists and fingers. These attacks lasted some minutes and occurred on a daily basis. As she got older, her parents used to avoid telling her beforehand if the family were going out as this always precipitated attacks. The episodes with retrocollis got less severe in early adult life. Excitement, anxiety or alcohol intake triggered some attacks. She has a premonition that an attack is building up which enables her to lie down in privacy. She doesn't actually fall asleep but waits the attack out. A regular nap in the afternoon reduces the frequency of attacks. If she stands in one place for any length of time, this can both initiate and compound symptoms. She has four children, all well.

Case IV2 The index case developed muscle spasms as a boy at the age of 13 or 14 affecting the legs and arms together. When asked to describe his earlier attacks, he mimicked dystonic posturing of the hands with flexion of the elbows and wrists and splaying of the fingers and inversion and plantar flexion of the ankles. The dystonic posturing would wax and wane for several hours and was alleviated only by sleep. As he got older, he became aware that an emotional stimulus such as watching something unpleasant on television, or a movie, could precipitate attacks and that they were more likely to occur when physically tired. Stress is a potent trigger factor. The episodes were never precipitated by startle or sudden movement. The episodes became both less frequent and less severe as he entered the fourth decade.

Episodes are rapidly terminated by a short sleep, and the patient finds it easy to fall asleep when he has an attack regardless of the time of day. As he has got older, he has found that he can sometimes alleviate attacks if he achieves a state of deep relaxation without actually falling asleep. He has a craving for food when he has attacks and if he eats (usually cereal) it assists him to relax more deeply. He typically sleeps

for 30–60 minutes. In episodes where attacks are alleviated without falling asleep, he has noticed that the alleviation of symptoms is instantaneous and occurs at a point just before sleep. Attacks tend to occur in the afternoon and early evening. As a teenager, he would regularly go to sleep at 6 or 7 pm and would have recovered by 10 pm. In his early 40s, he became aware of a feeling of loss of strength and muscle flickering in his thighs.

On examination at the age of 45, he had choreoathetoid movements of the legs which were infrequent but which he said tended to follow attacks of the type described above and which could persist for several days. Post-contraction myokymia was prominent in the quadriceps, femoris muscles bilaterally. Power, deep tendon reflexes and sensation were normal and nerve conduction studies revealed no abnormalities. Muscle histology and a lysosomal enzyme battery were normal.

Case V6 A 14 year old boy, the son of IV2 developed attacks of uncontrollable limb movements similar to those described by his father in his early teenage years. He tried to ignore the mild attacks. With severe attacks, the only means of relief is to fall asleep. On examination between attacks, he had evidence of prominent myokymia of a much more severe type than that seen in his father which affected the right arm and leg predominantly throughout the period of examination without respite. He indicated that the severity of this symptom waxed and waned but that it was with him to some extent most of the time.

Discussion

The inheritance pattern in this Australian family is clearly autosomal-dominant in keeping with most published reports of familial paroxysmal choreoathetosis^{5–11} although Mount and Reback's original report suggested a recessive transmission.² Onset in infancy, as in case IV1, is well recognised with reports as early as one week¹⁰ and attacks usually beginning in childhood. The range of ages of onset in this family is striking with congenital, childhood, adolescent and adult onset cases all clearly documented. Onset as late as 40, as in case III3 has not been previously reported although Lance has reported an atypical case with onset in the early 20s.⁶ The clinical features of the attacks in the family we describe are typical with a vague prodrome often with a feeling of muscle stiffening recognised in the earliest report² and involvement of the face, arm and legs in variable combinations. Episodes lasted from a few minutes to several hours. No consistent pattern of precipitation can be identified in the few reported families but sudden movement or startle are not precipitating features distinguishing this disorder from paroxysmal kinesigenic choreoathetosis. Precipitation with alcohol, coffee and tea have been reported and the relationship with fatigue or excitement as in the index case in this study is also recognised.¹¹ Although attacks in other families have been alleviated by lying down, the rapid relief of symptoms by short periods of

sleep which characterised several of our cases has not previously been stressed. This was particularly striking with one of our subjects who found that he could instantly fall asleep in the midst of an attack, at whatever time it occurred, and that after sleeping for one to two minutes he would usually awake with the episode completely over. Failure to respond to anticonvulsant medication distinguishes paroxysmal dystonic choreoathetosis from paroxysmal kinesigenic choreoathetosis. Myokymia has not been reported previously in any family with paroxysmal dystonic choreoathetosis to our knowledge but was a prominent feature in two patients in our family.

Several families with prominent myokymia in a setting of familial paroxysmal kinesigenic ataxia have been reported.^{4, 12-14} This syndrome is characterised by attacks with unsteadiness of gait and limbs and shaking of the head and limbs often with a feeling of stiffness in the face and hands. Abrupt change of position usually provokes episodes as in paroxysmal kinesigenic choreoathetosis. The feeling of tightness that some subjects with this syndrome complain of as episodes are evolving, resembles that often complained of in paroxysmal dystonic choreoathetosis. In occasional cases, such as case III-25 in the study of Brunt *et al.*,¹⁴ attacks can last for many hours and be terminated by sleep. Myokymia in this syndrome is often not very prominent and does not affect all family members.¹⁴ The fine rippling myokymia which characterises this disorder resembles that seen in our patients.

The syndrome of periodic familial ataxia is another entity that merits consideration.^{5, 15} This syndrome resembles our cases in the long duration of attacks and the tendency for episodes to occur with tiredness but differs in the absence of nystagmus in our cases and the presence of dystonic and athetoid features rather than ataxia.

The family presented in this report exhibits paroxysmal choreoathetosis affecting face and limbs with episodes lasting from minutes to hours and in some members rapidly relieved by sleep often after a very short time. There was no precipitation by sudden movement or startle distinguishing this disorder from familial paroxysmal kinesigenic ataxia and continuous myokymia and also from paroxysmal kinesigenic choreoathetosis. The episodes were atypical for familial periodic ataxia, and nystagmus was not a feature. Features which overlap with the syndrome of paroxysmal ataxia and

myokymia included myokymia in some members, the length of the episodes, and a tendency for abolition of attacks by sleep. A previous report of paroxysmal dystonic choreoathetosis in a patient from a family with familial ataxia¹⁶ suggests some overlap between these syndromes.

Clearly, several different paroxysmal movement disorders can be distinguished on the basis of precipitating factors, clinical features and length of episodes and response to treatment. The existence of cases with overlap features, however, raises the possibility that these different clinical phenotypes may represent different expressions of a single gene defect, a situation not uncommon in neurological illness. The striking response to sleep in several of the cases reported here is the most unique characteristic of this family and may provide some clues on the pathophysiology of the disorder.

- 1 Kertesz A. Paroxysmal kinesigenic choreoathetosis, an entity within the paroxysmal choreoathetoses; description of 10 cases including 1 autopsy. *Neurology* 1967;17:680-90.
- 2 Mount LA, Reback S. Familial paroxysmal choreoathetosis: preliminary report on a hitherto undescribed clinical syndrome. *Arch Neurol* 1940;44:841-6.
- 3 Farmer TW, Mustian VM. Vestibulocerebellar ataxia; a newly defined hereditary syndrome with periodic manifestations. *Arch Neurol* 1963;8:471-80.
- 4 Van Dyke DH, Griggs RC, Murphy MJ, Goldstein MN. Hereditary myokymia and periodic ataxia. *J Neurol Sci* 1975;25:109-18.
- 5 Forssman H. Hereditary disorder characterised by attacks of muscular contractions induced by alcohol among other factors. *Acta Med Scand* 1961;170:517.
- 6 Lance JW. Familial paroxysmal dystonic choreoathetosis and its differentiation from related syndromes. *Ann Neurol* 1977;2:285-93.
- 7 Weber MB. Familial paroxysmal dystonia. *J Neur Ment Dis* 1967;145:221-6.
- 8 Richards RN, Barnett HJM. Paroxysmal dystonic choreoathetosis: a family study and review of the literature. *Neurology* 1968;18:461-9.
- 9 Tibbles JAR, Barnes SE. Paroxysmal dystonic choreoathetosis of Mount and Reback. *Pediatrics* 1980;65:149-51.
- 10 Walker ES. Familial paroxysmal dystonic choreoathetosis; a neurological disorder simulating psychiatric illness. *Johns Hopkins Med J* 1981;148:108-13.
- 11 Pruntek H, Monniger P. Therapeutic aspects of kinesigenic paroxysmal choreoathetosis and familial paroxysmal choreoathetosis of the Mount Reback type. *J Neurol* 1980;230:163-9.
- 12 Hanson PA, Martinez CB, Cassidy R. Contractures, continuous muscle discharges and titubation. *Ann Neurol* 1977;1:120-4.
- 13 Gancher ST, Nutt JG. Autosomal dominant episodic ataxia; a heterogenous syndrome. *Movement Disorders* 1986;1:239-53.
- 14 Brunt ERP, Van Weerden TW. Familial paroxysmal kinesigenic ataxia and continuous myokymia. *Brain* 1990;113:1361-82.
- 15 Griggs RC, Moxley RT, LaFrance RA, McQuillen J. Hereditary paroxysmal ataxia: response to acetazolamide. *Neurology* 1978;28:1259-64.
- 16 Mayeux R, Fahn S. Paroxysmal dystonic choreoathetosis in a patient with familial ataxia. *Neurology* 1982;32:1184-6.