

Unilateral frontal lobectomy can produce strategy application disorder

Laura H Goldstein, Sarah Bernard, Peter B C Fenwick, Paul W Burgess, Jane McNeil

Abstract

Following a 5 cm left frontal lobectomy for the removal of a mixed astrocytoma-oligodendroglioma, a 51 year old right handed man showed a marked dissociation between his performance on standard neuropsychological tests and his everyday behaviour. In contrast to his intact neuropsychological test performance, he was impaired on a test of "strategy application" which requires goal articulation, plan specification, self-monitoring, and evaluation of outcomes, as well as the establishment of mental "markers" to trigger specific behaviour. Strategy application disorder can therefore be produced by a unilateral circumscribed frontal lobe lesion.

(*J Neurol Neurosurg Psychiatry* 1993;56:274-276)

Changes in behaviour, cognitive function, emotion or personality may follow damage to frontal lobe structures, (for example see reference^{1,2}), with resultant disruption to everyday behaviour. For instance, following the removal of a bilateral orbitofrontal meningioma, Eslinger and Damasio's³ patient, a man of premorbidly superior intelligence, was unable to organise his personal life or maintain employment, despite at least average performance on many standardised neuropsychological tests, including those typically sensitive to frontal lobe dysfunction. This dissociation between neuropsychological test performance and everyday behaviour in patients with prefrontal damage and high intelligence has recently been discussed by Shallice and Burgess.⁴ Three patients, who had sustained head injuries affecting predominantly prefrontal structures (bilaterally in two cases), performed well and similarly to premorbid levels on a range of cognitive, language and perceptual tests. Two had memory deficits (one of a "frontal" type) but only one showed consistent deficits on "frontal lobe" tests. All three, however, displayed severe organisational difficulties in daily life. In addition they demonstrated pronounced impairments on two "real-life" analogue tests. The planning, monitoring and evaluative deficits exhibited on these tasks were said to be characteristic of strategy application disorder.

Despite the abundant evidence of neuropsychological impairment following unilateral frontal lobe damage,² the issue of marked dissociation between neuropsychological test performance, personality change and every-

day behaviour has not been raised for individuals undergoing unilateral frontal lobectomy. Our patient, who had a 5 cm left frontal lobectomy, highlights the personal problems faced by an intelligent man following surgery and the difficulties in identifying the resulting neuropsychological impairment. His case provides a more specific example of Shallice and Burgess'⁴ strategy application disorder, because unlike their patients with head injury, the lesion did not extend beyond the left frontal lobe.

Case report

A 51 year old right handed man was admitted for the assessment of increasing lethargy, worsening anger control and reassessment of cognitive functioning. He had undergone a left frontal lobectomy two and a half years earlier following the diagnosis of a frontal lobe tumour. He had developed epilepsy in 1981, but seizures were poorly controlled with anticonvulsant medication. MRI in 1988 indicated that the lesion was probably neoplastic. A 5 cm resection of left frontal lobe from the pole was undertaken (figure). Histological examination revealed the mass to be a low grade mixed astrocytoma-oligodendroglioma; this had been completely removed. Since surgery he had been seizure free, maintained on carbamazepine 700 mg daily. There was no family history of psychiatric disorder.

The patient had held a senior management position in an international company. His premorbid personality was energetic but quick tempered. Two years after surgery he took medical retirement because of increasing lethargy, but worked from home as a freelance management consultant. He had difficulty making decisions, culminating in his taking two weeks to decide which slides to use for a work presentation; the decision was never finally reached. His anger control had worsened since surgery, with increasingly frequent outbursts. His marriage had always been stormy, but had deteriorated considerably in the months preceding admission; his children were afraid of him.

On admission no focal neurological abnormality was detected. He was a casually dressed man whose manner was overfamiliar. He invaded one's personal space. His speech was circumstantial and overinclusive. His mood was labile; he was moved easily to tears and laughter within a short period. There were no biological features of depression, nor any psychotic beliefs or experiences. He

**Neuropsychiatry Unit,
Maudsley Hospital,
London**
L H Goldstein
S Bernard
P B C Fenwick

**Psychology
Department, Institute
of Psychiatry, London**
J McNeil

**Psychology
Department,
University College
London**
P W Burgess

Correspondence to:
Dr Laura Goldstein,
Department of Psychology,
Institute of Psychiatry, De
Crespigny Park, London,
SE5 8AF.

Received 3 March 1992
and in final revised form
17 July 1992.
Accepted 29 July 1992

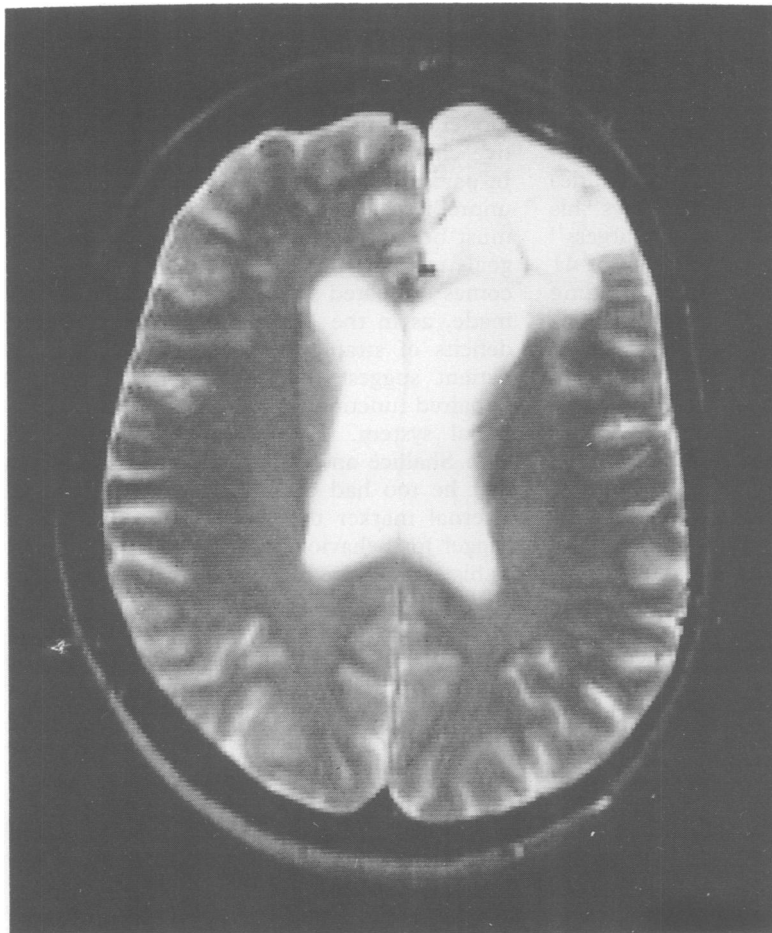


Figure T2-weighted MRI scan (SE TR 3.2 s TE 80 ms) showing extent of left frontal lobectomy.

showed some insight but tended to underestimate the severity of his problems.

During a two month admission there was no evidence of depression and a previously started trial of fluvoxamine was stopped. He continued to be overfamiliar, particularly with women, showing little recognition of social cues. He talked at length and was unaware of others' intolerance of this. He was able to control his temper on the ward, but while on leave had arguments with his wife, and once assaulted her.

Physical investigations were normal and

serum carbamazepine levels were within the therapeutic range.

NEUROPSYCHOLOGICAL FINDINGS

Pre- and post-operative standardised neuropsychological assessments indicated that there were no significant changes in the patient's IQ or memory functions as a result of surgery.

Present assessment revealed a superior WAIS-R Verbal IQ (129) and a high average Performance IQ (111).

Memory tests revealed no impairments. He demonstrated good immediate recall (75-90th percentile) and average delayed recall (50-70th percentile) of a short story.⁵ Auditory verbal list learning, subsequent recall of a second, distraction list and recall of the initially learnt list⁹ were all efficient. Immediate recall of visuospatial material⁶ was intact and delayed recall of the Rey-Osterreith figure was at the 80-90th percentile.

Perceptual functions were intact.^{7,8} Confrontation naming ability⁹ was superior (27/30).

On traditional tests of frontal lobe function his performance was good (table). In addition, on a test of self ordered memory¹⁴ he performed within the average range.⁴ Completion times on parts A and B of the Trail Making Test were at the 70th and 75th percentiles respectively. On a new test involving spatial sequence learning and shifting set (Burgess and Shallice, in preparation), his performance was within the normal range. On the Hayling Sentence Completion task (Burgess and Shallice, in preparation), he showed normal verbal latency (score 17.03 s; control mean 14.8, SD 12.5) and verbal inhibitory ability (score 29.1 s; control mean 35.2, SD 31.2), despite the proposed role of left frontal cortex in suppressing habitual verbal responses.¹⁵ He did, however, give concrete interpretations to six out of 10 proverbs.

ADDITIONAL TESTS

To examine the patient's planning ability, he was administered Shallice and Burgess¹⁴ Six Element Test. He was required to carry out six open-ended tasks in a fixed time period to maximise the overall score obtained. The six tasks are subdivided into two sets of three: dictating details of a journey into a tape recorder, computing arithmetic problems of increasing difficulty and writing down the name of approximately 100 pictures. His performance (table) was well within normal limits, although he broke one test rule by completing two subtests of the same task one after the other. However, he recognised this rule violation as it occurred.

He then undertook the more complex Multiple Errands task.⁴ He had to complete a number of tasks, principally involving shopping in an unfamiliar pedestrian precinct, according to a prelearnt set of rules. The tasks varied in complexity and included buying specified items; some required ingenuity and social judgement, for example sending

Table Standardised neuropsychological tests of frontal lobe function and strategy application test results.

	Patient	Controls (mean (SD))
Standardized tests of frontal lobe dysfunction		
Short Wisconsin Card Sort ¹⁰		
Categories achieved	6	5 (1.6)
Number of errors	2	9.2 (8.5)
Verbal fluency: ¹¹ total number of words	59	58.7 (25.6)
Cognitive Estimates: ¹² Error Score	0	3 (2.6)
Money's Road-Map Test: ¹³ Error Score	1	1.7
Strategy Applications Tests ⁴		
Six Element Test		
No of tasks attempted	6	5.7 (0.6)
Maximum time on any one task	2 minutes 50 s	5 minutes 35 s (53 s)
Multiple Errands Test		
Inefficiencies	6	1.4 (1.1)
Rule breaks	7	1.6 (1.3)
Interpretation failures	1	0.4 (0.7)
Task failures	3	1.1 (1.4)
Total	17	4.6 (2.1)

one of us (PWB) an appropriate postcard on which had to be written four items of pre-specified information which included the name of the coldest place in Britain on the previous day.

It was on this Multiple Errands task that the full extent of his everyday difficulties became apparent. The table displays his scores compared to Shallice and Burgess⁴ control subjects (who had a mean age of 41 years, and a mean National Adult Reading Test IQ equivalent¹⁶ of 120.2). He made considerably more errors than did the controls, being less efficient, for example, having to return to more than one shop in which he had already bought an item to purchase further goods; breaking task rules, such as leaving the confines of the precinct to complete a task, not reporting his purchases to the experimenters and using a stamp that another shop customer had given him; misinterpreting tasks (initially sticking the stamp on the wrong card) and failing to complete some tasks altogether. The test also elicited quite disinhibited behaviour; he had omitted to find out the price of tomatoes while earlier in the greengrocers and, realising that he should not re-enter this shop, very conspicuously climbed onto the fruit display outside it and peered in through the shop window. He offered *post hoc* rationalisations of his actions, but could remember without prompting all the rules of the Multiple Errands test after its completion.

Discussion

Our patient continued to function at a high intellectual level following recovery from his left frontal lobectomy. Despite initial nominal dysphasia, language functions were at an average-to-superior level and he performed well on standard tests of frontal lobe function. In contrast to this high level of performance in structured testing situations he was unable to maintain his level of employment and faced increasing personal difficulties within his family.

In the present case the lesion included both orbitofrontal and dorsolateral prefrontal cortex, areas associated with a range of personality, cognitive and behavioural changes following surgery. He reported loss of energy and initiative, akin to pseudodepression.¹ His inappropriate social behaviour was not dissimilar to that of Eslinger and Damasio's³ patient. An exacerbation of premorbid personality characteristics was certainly present.

The absence of deficits on standardised neuropsychological tests administered to our patient is likely to derive from the specific nature of such tests. The structured nature of these often removes the need for the subject to employ higher order, "executive" functions. Only specific cognitive processes are required, and for a short time period. Unpredictability rarely features in neuropsychological tasks and only within limited parameters. Of particular relevance to the present case, such tests also do not require such

processes as prospective memory, priority setting and the interleaving of competing tasks of similar priority.

The Supervisory Attentional System¹⁷ is a model used to explain behavioural and cognitive changes seen after frontal lobe damage. In particular the system operates in relatively unpredictable situations, where social cues must be responded to, and where a range of goals must be defined, actions planned, outcomes evaluated and appropriate adaptations made, as in the Multiple Errands task. The deficits of strategy application⁴ seen in our patient suggest that surgery had produced impaired functioning of his supervisory attentional system. Comparison of our patient with Shallice and Burgess⁴ patients suggests that he too had difficulty in establishing an internal marker that acts prospectively as a trigger for behaviour change or reassessment, as his errors were mainly rule breaks or inefficiencies. These deficits cannot be ascribed solely to personality or motivational deficits.⁴ The planning difficulties elicited by the Multiple Errands task mirrored those our patient experienced on a daily basis.

The extent of behavioural impairment seen in our patient after unilateral frontal lobectomy, despite his relatively preserved intellectual functioning, heightens the need for adequate counselling and support for such patients and their families before and following surgery. The absence of formal neuropsychological test decrement cannot be taken as definitive evidence of the absence of deficit *per se* and it may be necessary in such cases to go beyond the clinician's office to elicit the true picture of the neuropsychological impairment.

- 1 Blumer D, Benson DF. Personality changes with frontal and temporal lobe lesions. In: Benson DF, Blumer D Eds. *Psychiatric aspects of neurological disease*. New York: Grune & Stratton, 1975:151-70.
- 2 Stuss DT, Benson DF. *The frontal lobes*. New York: Raven Press, 1986.
- 3 Eslinger PJ, Damasio AR. Severe disturbance of higher cognition after bilateral frontal lobe ablation: Patient EVR. *Neurology* 1985;35:1731-41.
- 4 Shallice T, Burgess PW. Deficits in strategy application following frontal lobe damage in man. *Brain* 1991; 114:727-41.
- 5 Coughlan AK, Hollows SE. *The adult memory and information processing battery (AMIPB)*. Leeds: St. James' University Hospital, 1985.
- 6 Benton A. *Revised visual retention test*, 4th edn. New York: Psychological Corporation, 1974.
- 7 Warrington EK, Taylor AM. The contribution of the right parietal lobe to object recognition. *Cortex* 1973;9: 152-64.
- 8 Warrington EK, James M. Disorders of visual perception in patients with localized cerebral lesions. *Neuropsychologia* 1967;5:253-66.
- 9 McKenna P, Warrington EK. *Graded naming test*. Windsor: NFER-Nelson, 1983.
- 10 Nelson HE. A modified card sorting test sensitive to frontal lobe defects. *Cortex* 1976;12:313-24.
- 11 Milner B. Some effects of frontal lobectomy in man. In: Warren JM, Akert K, eds. *The frontal granular cortex and behaviour*. New York: McGraw Hill, 1964:313-31.
- 12 Shallice T, Evans ME. The involvement of the frontal lobes in cognitive estimation. *Cortex* 1978;14:294-303.
- 13 Semmes J, Weinstein S, Ghent L, Teuber H-L. Correlates of impaired orientation in personal and extra personal space. *Brain* 1963;86:747-72.
- 14 Petrides M, Milner B. Deficits in subject ordered tasks after frontal and temporal lobe lesions in man. *Neuropsychologia* 1982;20:249-62.
- 15 Perret E. The left frontal lobe of man and the suppression of habitual responses in verbal categorical behaviour. *Neuropsychologia* 1974;12:323-30.
- 16 Nelson HE. *National adult reading test (NART)* Windsor: NFER-Nelson, 1982.
- 17 Shallice, T. *From neuropsychology to mental structure*. New York: Cambridge University Press, 1988.