

disorder.<sup>4,5</sup> The combination of HLA types in these patients may be a marker for a predisposition to the Guillain-Barré syndrome.

DLW DAVIDSON  
AF O'SULLIVAN  
KD MORLEY

Ninewells Hospital and Medical School,  
Dundee DD1 9SY, UK

- 1 Saunders M, Rake M. Familial Guillain-Barré syndrome. *Lancet* 1965;2:1106-7.
- 2 MacGregor GA. Familial Guillain-Barré syndrome. *Lancet* 1965;2:1296.
- 3 Kaslow RA, Sullivan-Bolyai JZ, Hafkin B, et al. HLA antigens in Guillain-Barré syndrome. *Neurology* 1984;34:685-8.
- 4 Gorodezky C, Varela B, Castro-Escobar LE, Chavez-Negrete A, Escobar-Gutierrez LE, Martinez-Mata J. HLA-DR antigens in Mexican patients with Guillain-Barré syndrome. *J Neuroimmunology* 1983;4:1-7.
- 5 Winer JB, Briggs D, Welsch K, Hughes RAC. HLA antigens in the Guillain-Barré syndrome. *J Neuroimmunology* 1988;18:13-6.

#### Adult onset acid maltase deficiency associated with epilepsy and dementia: a case report

Adult onset acid maltase deficiency (AMD) (glycogenosis type II b) characteristically presents after the age of 20 years with a slowly progressive limb-girdle muscle weakness.<sup>1</sup> Respiratory muscle involvement occurs in a third of cases and may be the presenting feature.<sup>2</sup> Although CNS involvement is seen in the more severe infantile form of AMD (Glycogenosis type IIa), it has not been described in adults. We report a case of adult onset AMD associated with epilepsy and dementia.

A 65 year old woman was referred with intractable epilepsy, the onset of which was at 20 years with a generalised tonic-clonic seizure. Seizures had continued without remission despite treatment with phenobarbitone, phenytoin, and sodium valproate. The current seizure pattern consisted of a secondarily generalised tonic-clonic seizure twice a month and a complex partial seizure approximately monthly. At the age of 29 years she required psychiatric admission because of attempted suicide and hysterical behaviour. She was thought to have an immature personality and to lack foresight and judgement. From the age of 52 years she had been in residential care, and anti-social behaviour, incontinence of urine and impaired cognition had been noted. From the age of 57 years she developed progressive limb weakness.

She had five siblings. One was reported to have epilepsy but the details were not available. Three of the other siblings had adult onset AMD and their histories have been published previously.<sup>1</sup> The parents had no history of any neurological disorder and there was no consanguinity.

On examination cooperation was limited. She was unable to stand. Fundoscopy and eye movements were normal. There was a mild weakness of neck flexion. Wasting of the shoulder girdle muscles and small muscles of the hand was present bilaterally. Wasting was difficult to assess in the legs because of obesity and oedema. There was a grade 4 weakness proximally in the arms, grade 4+ distally, and a grade 2-3 weakness in the legs, more marked proximally. Coordination was

normal. Bilateral grasp reflexes were elicited. Upper limb tendon reflexes were normal but knee and ankle jerks were absent bilaterally. Plantar responses were flexor. No sensory deficit was found. General examination was unremarkable except for obesity.

The following investigations were normal or negative: full blood count, electrolytes, renal function, liver function, thyroid function, serum electrophoresis, autoimmune profile, blood film for acanthocytes, syphilis serology, plasma and urinary amino acids, white cell lysosomal enzymes and nerve conduction studies. The ESR was 45 mm in 1 hour and the creatine kinase was raised at 405 IU/L (0-243 IU/L). Initially serum lactate was slightly elevated at 1.83 mmol/l (0.5-1.65 mmol/l), but was normal on two subsequent occasions. Serum pyruvate was normal. An electrocardiogram showed poor R wave progression but was otherwise normal. Chest radiography revealed a raised right diaphragm. Lying and standing vital capacity were 1.05 l and 1.5 l respectively. Arterial blood gases were normal. During a sleep study lasting 9-18 hours oxygen saturation was 70-80% for 2-3 minutes, 80-90% for 35 minutes and > 90% for the remainder of the study. Electromyographic findings were moderately myopathic without any specific features. Histological appearances of a quadriceps muscle biopsy were indicative of AMD, with a high proportion of the muscle fibres containing multiple vacuoles packed with glycogen. Acid maltase activity in the muscle was reduced at 0.01 (0.07-0.29)  $\mu$ mol maltose hydrolysed per gram of muscle (wet weight) per minute. Oxidative enzymes, phosphorylase, and adenylate deaminase were normal. The diagnosis was supported by finding a significant number of lymphocytes containing several small discrete glycogen filled vacuoles.<sup>3</sup>

CT brain scan showed cerebellar atrophy but the patient was unable to comply with an MRI scan. An electroencephalogram showed an irregular dominant rhythm of 8 Hz, widespread theta and delta activity and superimposed bilateral spike and spike wave discharges. Neuropsychological assessment revealed a full scale IQ of 67 (WAIS-R) with evidence of deterioration and most marked impairment of frontal lobe function.

The progressive weakness with evidence of respiratory muscle involvement, muscle histology, and lymphocyte appearances in this patient were all typical of adult onset AMD. Serum lactate was raised on one out of three measurements, which although not a usual feature of AMD may have been secondary to hypoventilation. Additional features in this case were epilepsy, psychiatric disturbance and impaired cognition, for which no other aetiology was identified. Her three siblings with AMD showed a spectrum of clinical and pathological findings,<sup>2</sup> but did not have epilepsy or dementia, and an elder sister with no history of muscle weakness, had epilepsy. It is possible that, in this family there is a tendency to epilepsy independent of the AMD. An alternative explanation is that the epilepsy, psychiatric disturbance and impaired cognitive function seen in this patient are a manifestation of central AMD.

Although in previous cases of adult onset AMD clinical involvement has been restricted to the skeletal muscles, necropsy studies have revealed more widespread disease,<sup>4,5</sup> with microscopic abnormalities in all skeletal muscles, whether weak or not, and variable involvement of smooth muscle, cardiac muscle, the tongue and the spleen. In these two

studies of adult onset AMD no microscopic abnormalities were found in the brain.<sup>4,5</sup> Acid maltase activity is lowest in skeletal muscle, but also reduced in the liver, heart and brain. Cerebral acid maltase activity has been recorded as 6.5% of normal.<sup>4</sup> There is variation in the degree to which various organs are affected. For example in one post mortem study the level of acid maltase activity in the myocardium was as low as that in skeletal muscle and this was reflected by a vacuolar cardiomyopathy.<sup>5</sup>

In cases of infantile AMD there is more marked reduction of acid maltase activity. Both cardiac and central nervous system manifestations are more prominent, with abnormal glycogen storage in most cells of the brain and spinal cord.

In the few adult onset cases that have been studied, acid maltase activity in the brain has been low.<sup>4</sup> It is possible that this patient with adult onset AMD has very low levels of cerebral acid maltase activity and that this is the cause of her disturbance of cerebral function. The association of adult onset AMD with epilepsy, cognitive impairment and psychiatric disturbance, however, may be fortuitous and no definite conclusion can be drawn from a single patient. We draw attention to the association in case similar patients have been seen by others.

M PREVETT  
TP ENEVOLDSON  
JS DUNCAN

National Hospital for Neurology and Neurosurgery,  
Queen Square, London WC1 3BG, UK

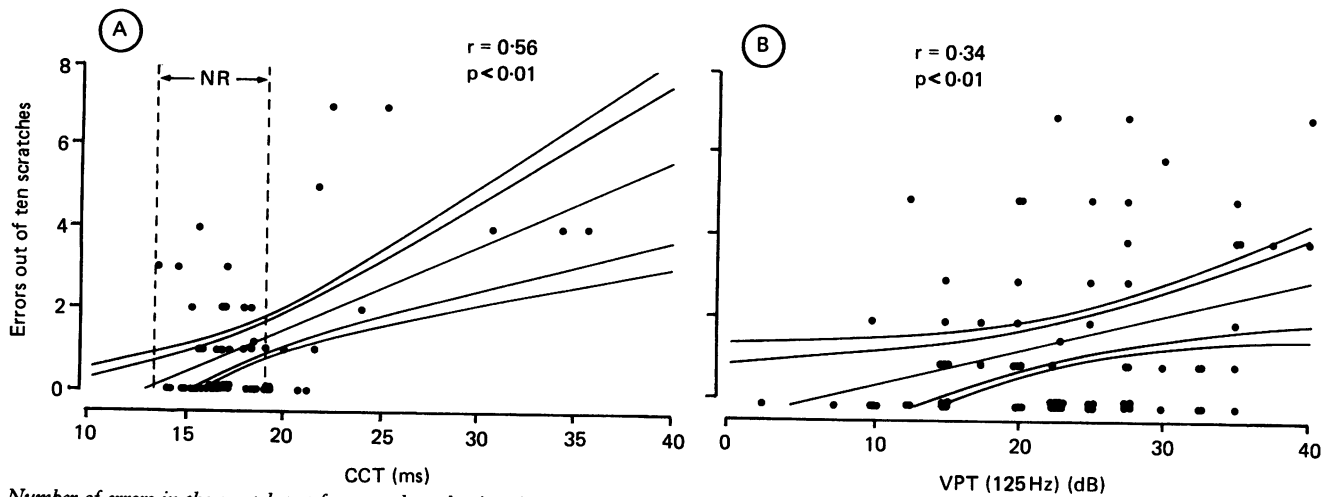
Correspondence to: Dr Duncan

- 1 Engel AG. Acid maltase deficiency in adults—studies in four cases of a syndrome which may mimic muscular dystrophy or other myopathies. *Brain* 1970;91:435-68.
- 2 Swash M, Schwartz MS, Apps MCP. Adult onset acid maltase deficiency: Distribution and progression of clinical and pathological abnormality in a family. *J Neurol Sci* 1985; 68:61-74.
- 3 Trend P St J, Wiles CM, Spencer GT, et al. Acid maltase deficiency in adults. Diagnosis and management in five cases. *Brain* 1985; 108:845-60.
- 4 DiMauro S, Stern LZ, Mehler M, et al. Adult onset acid maltase deficiency: a post mortem study. *Muscle Nerve* 1978;1:27-36.
- 5 van der Walt JD, Swash M, Leake J, et al. The pattern of involvement of acid maltase deficiency at autopsy. *Muscle Nerve* 1987;10: 272-81.

#### A reappraisal of "direction of scratch" test: using somatosensory evoked potentials and vibration perception

We would like to comment on the article by Hankney and Edis<sup>1</sup> which proposed "direction of scratch" test for the clinical examination of posterior column function. Their method is easy to perform, and the errors in the detection of direction of scratch on the skin were reported to be correlated with impaired position and/or vibration sense tested using a 128 Hz tuning fork. Since somatosensory evoked potential (SEP) and vibration sense was thought to be mediated through the posterior column and lemniscal system, we intended to evaluate the usefulness of their test together with SEPs and quantitative vibration sense.

Fifty six patients, mean age 43.5, were studied. They consisted of 43 patients with



Number of errors in the scratch test for central conduction time (CCT) (a) and vibration perception threshold (VPT) (b). Normal range (NR) indicates the mean 3SD of the normal value. The straight line shows the regression line, and the inner and outer curves represent the 99% and 95% confidence limits, respectively.

multiple sclerosis, six with spinocerebellar degeneration, two with hereditary spastic paraplegias, two with ossifications of the posterior longitudinal ligament, two with cerebrovascular diseases and one patient with thoracic spinal cord tumour. None were complicated by peripheral neuropathy. A uniform random binary number sequence of 10 vertical 2 cm scratches was performed over the anterior aspect of the shin with the sharp margin of a paper clip. The subjects were asked to state whether the direction of the scratch was "up or down", and the number of errors was assessed. Scalp N/P 37 and N19 over the T12 spinous process to electric stimulation of the posterior tibial nerve were recorded by means of a Medelec MS-20 (UK), and the central conduction

time (CCT; N/P37-N19) was evaluated. Vibration perception of the big toe was measured at 63 Hz, 125 Hz and 250 Hz by a Rion vibrometer (Japan). The subjects were "blind" to the changes being made in stimulus intensity, which was increased stepwise every three seconds from -10 dB at 2.5 dB intervals until it was noticed by the subject. The vibration perception threshold (VPT) was defined as the lowest stimulus intensity to be noted.

The number of errors in the scratch test was found to be significantly correlated not only with the CCT ( $p < 0.01$ ,  $r = 0.56$ , figure a) but also with the VPTs at 63 Hz ( $p < 0.01$ ,  $r = 0.34$ ), 125 Hz ( $p < 0.01$ ,  $r = 0.34$ , figure b) and 250 Hz ( $p < 0.05$ ,  $r = 0.27$ ). These results agree that the scratch

test, SEP and VPT are examinations commonly reflecting posterior column function.

The scratch test is recommended as a simple and yet reliable clinical neurological examination for detecting posterior column dysfunction.

YUMIKO MOTOI  
HIROYUKI MATSUMOTO  
YUH KANESHIGE  
SUSUMU CHIBA  
Department of Rehabilitation and Neurology,  
Sapporo Medical College,  
South 1 West 16, Chuou-Ku,  
Sapporo 060, Japan.

Correspondence to: Dr Motoi

1 Hankney GJ, Edis R. The utility of testing tactile perception of direction of scratch as a sensitive clinical sign of posterior column dysfunction in spinal cord disorders. *J Neurol Neurosurg Psychiatry* 1989;52:395-8.

### Seventh nerve palsy as a false localising sign

Benign intracranial hypertension (BIH) usually produces a clinical picture of headache, visual disturbances and bilateral papilloedema. Abducens nerve palsies have been reported in between 10-30% of cases. Other cranial nerve palsies have rarely been reported in this condition<sup>1-5</sup> and those that have occurred were nearly always in children. One case of facial diplegia occurring in an adult with this condition has been documented.<sup>6</sup> We report a patient with BIH who presented with bilateral sixth nerve palsies and a right sided seventh nerve palsy all of which resolved after a lumbar puncture.

A twenty five year old obese woman on the contraceptive pill presented with a three week history of bifrontal headaches, nausea and vomiting. The headache was not made worse by coughing or stooping and neither was it relieved by analgesics. One week before admission the patient developed diplopia on horizontal gaze and visual obscuration. Examination revealed mild bilateral sixth nerve palsies and a right sided facial nerve palsy of lower motor neuron type with a reduced blink reflex. The visual acuity was 6/6-2 on the right and 6/5-1 on the left. The blind spots were enlarged but the visual fields were otherwise normal. Marked bilateral papilloedema was observed. An otological

examination was normal. A CT head scan, including a contrast examination, was normal. Lumbar puncture revealed clear and colourless CSF with an opening pressure of 300 mm CSF. The fluid was acellular with a protein of 230 mg/l and a glucose of 4.0 mmol/l (plasma glucose 5.2 mmol/l), Gram stain and cytology for malignant cells were both negative. The following investigations were normal: CXR, FBC, ESR, ANF, VDRL, clotting studies, lupus anti-coagulant, fibrinogen level, immunoglobulins, C3, C4, serum oestriol, androstenedione, serum DHA - sulphate, LH and FSH. On the day following lumbar puncture, the diplopia had resolved and facial weakness improved. By the second day, the cranial nerves examination was normal except for papilloedema. The patient was started on a weight reducing diet and has required no further treatment. On review six weeks after discharge, the visual acuity was 6/4 bilaterally and mild papilloedema was present.

Identifying a neurological sign as being falsely localising rests on two important considerations. Firstly, that an accurate knowledge of the anatomy is attained and secondly, that the sign itself must arise in an anatomical area that is remote from the site of the original pathology. A sixth nerve palsy is a classic example in patients with raised intracranial pressure from a brain tumour distant from the course of the nerve. The long

intracranial course of the abducens nerve is thought to be responsible for its predilection compared to other cranial nerves. However, Collier favours an alternative explanation based on the direction in which the nerve emerges from the brainstem. The abducens nerve emerges in a straight forward direction, whilst all other cranial nerves emerge transversely or obliquely. Therefore, backward displacement of the brainstem by an intracranial space occupying lesion would exert its maximum effect on the sixth nerve.<sup>7</sup> Either way the patho-physiological mechanism is thought to involve displacement of the brain by enlarging intracranial mass and traction upon cranial nerves. False localisation from other cranial nerve palsies have also been described.<sup>7,8</sup> BIH offers a very good model to study the effect of raised pressure without focal mass effect suggesting that the cranial nerve palsies could be the result of general pressure related effect without implying a specific directional intracranial pressure forces. BIH was first described by Quincke in 1893.<sup>9</sup> At that time otitis media was thought to be the most common aetiology and there has been renewed interest in sinus occlusion in the genesis of BIH.<sup>10</sup> Many other mechanisms have been implicated including obesity<sup>11</sup> and the contraceptive pill<sup>12</sup> both of which were involved in our patient.

Whilst abducens nerve palsies are not uncommonly seen as a false localising sign of