

# Ocular and neurological Behçet's disease without orogenital ulceration?

C J Lueck, M Pires, A C E McCartney, E M Graham

## Abstract

**A 28 year old West Indian patient is described who had a relapsing and remitting steroid-sensitive illness for 3 years. The clinical features included uveitis and widespread CNS involvement. The patient was treated as though he had neurosarcoidosis. Post mortem examination revealed histological changes compatible with a diagnosis of Behçet's disease, but at no time did he suffer from oral or genital ulceration or arthritis. The authors suggest a new term to encompass such an entity: the "Behçet's MINUS" syndrome (multifocal intermittent neurological and uveitic syndrome).**

(*J Neurol Neurosurg Psychiatry* 1993;56:505-508)

Sarcoidosis is the most commonly diagnosed cause of anterior uveitis in the West Indian population, and is well documented to involve the nervous system in 5-16% of all cases.<sup>1</sup> Behçet's disease is a vasculitic illness comprising recurrent oral ulceration plus any two of recurrent genital ulceration, eye lesions, skin lesions, and a positive pathergy test, in addition to various other features such as thrombophlebitis and arthritis.<sup>2</sup> It involves the nervous system in 4-29%.<sup>3</sup> Behçet's disease typically occurs in patients from Turkey, the Middle East, and the Far East, and is very uncommon in patients from the West Indies.

## Case history

A 28 year old West Indian hospital night porter, who had come to Britain from Jamaica ten years previously, presented in September 1988 with blurred vision, and was found to have bilateral vitreous haemorrhages, keratic precipitates, cells in the vitreous, and new vessel formation in both fundi. A fluorescein angiogram showed no evidence of vessel closure, but several areas of perivascular leakage. He had no past medical or family history of note, and was systemically quite well. A chest x ray, Kveim test and Mantoux test were normal or negative. This uveitic picture was presumed to be due to sarcoidosis, and treated with topical steroids. His vision improved, and he was not troubled again until August 1989 when he was admitted with a two-week history of intermittent headaches, vomiting, a tendency to fall to the right, right-sided incoordination, and urinary incontinence. He was febrile (temperature

37.4°), but his visual acuity was 6/9 on the left and 6/12 on the right, with bilateral uveitis, new vessel formation at the posterior poles, but no papilloedema. His left pupil was larger than the right, and there was a mild left ptosis. He had a right upper motor neuron facial weakness, and a mild right hemiparesis. There was truncal and limb ataxia, more marked on the right. Reflexes were brisk, more so on the right, and both plantar responses were equivocal. Sensory examination was normal.

The full blood count, urea, electrolytes, glucose and liver function tests were normal but the ESR was raised at 46 and later 62 mm/hr. Serum angiotensin converting enzyme was normal (31 units/l), as were his immunoglobulins, chest and sinus x rays. A Mantoux test at 1 in 10 000 was negative. An initial CSF contained 143 red cells, and 16 white cells (mostly neutrophils)/mL, protein 0.3 g/l, and glucose of 2.9 mMol/l (blood 5.6). Viral and fungal screens were negative, as were oligoclonal bands. A second CSF showed 5 red cells and 45 white cells (75% lymphocytes)/mL, protein 0.2 g/l, and normal glucose.

Whilst in hospital, he became drowsy and dysarthric. He developed a complete left third nerve palsy, a depressed gag reflex and slowed tongue movements. Two CT scans were performed four days apart, and both were normal. The differential diagnosis of sarcoidosis and tuberculosis could not be settled, and he was treated for both with 80 mg prednisolone/day, and triple anti-tuberculous therapy.

On this medication he improved and was discharged. In outpatients his steroids were reduced to 40 mg/day, and his uveitis was quiescent in September 1989. In October 1989, however, he developed increasing somnolence. Rather than increase his steroids, he was started on azathioprine, 150 mg/day. A MRI scan was performed which showed a lesion deep in the right hemisphere at the posterior end of the internal capsule and adjacent thalamus.

He remained stable until January 1990 when he developed increasing drowsiness and blurred vision. Examination at this point showed that his mild right-sided facial weakness and right hemiparesis had returned. A lumbar puncture showed 12 red cells, 1 white cell/ml and a protein 0.2 g/l. A repeat MRI scan again showed the lesion in the right thalamus and internal capsule extending down to the midbrain, but it had clearly enlarged since

**Departments of  
Neurology,  
Neuropathology, and  
Neuro-Ophthalmology  
National Hospital for  
Neurology and  
Neurosurgery London,  
UK**

C J Lueck  
M Pires  
E M Graham

**Department of  
Pathology Institute of  
Ophthalmology,  
London, UK**

A C E McCartney

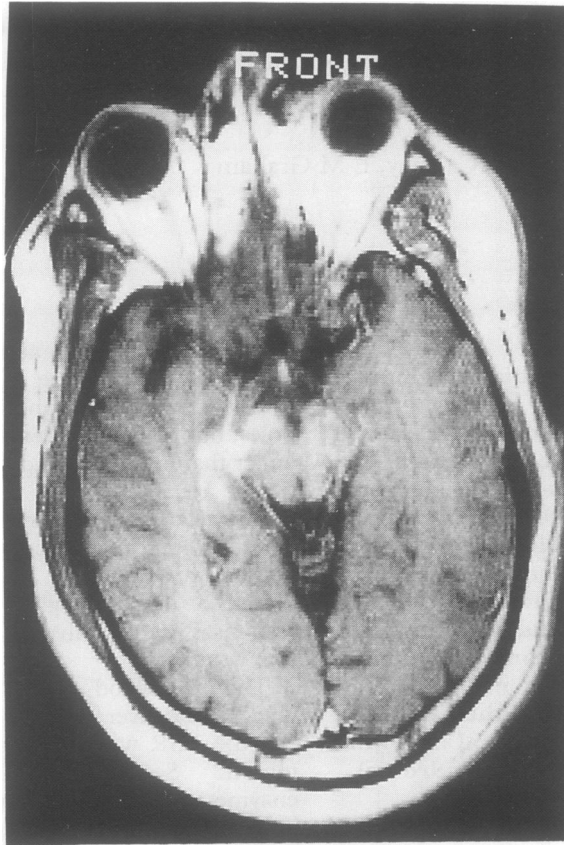
**Department of  
Medical  
Ophthalmology St  
Thomas's Hospital,  
London, UK**  
E M Graham

Correspondence to:  
Dr Graham, Department of  
Neuro-Ophthalmology,  
The National Hospital for  
Neurology and  
Neurosurgery, Queen  
Square, London  
WC1N 3BG, UK

Received 26 April 1992  
and is revised from  
13 August 1992.

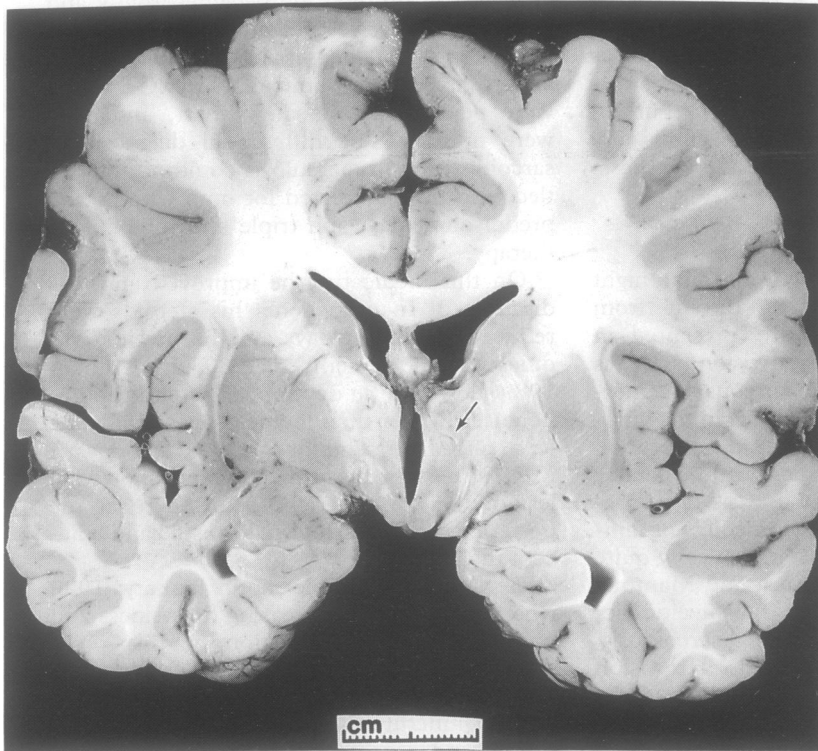
Accepted 25 August 1992

*Figure 1 Axial T1-weighted MRI scan following gadolinium enhancement at the level of the midbrain. An area of increased signal is visible in the right mesial temporal lobe and cerebral peduncle. The patient's right is on the left of the scan.*



the earlier scan. His anti-tuberculous therapy was stopped, and his steroids increased to 120 mg/day of prednisolone. His azathioprine was also increased to 225 mg/day.

Once again he improved. During the course of 1990 he had several relapses and



*Figure 2 Coronal brain slice through mammillary bodies showing discoloured areas in the internal capsules and thalami. There is a small cavitated area in the right thalamus (arrow).*

remissions dependent on his steroid dose. When the prednisolone dose was lowered to below 25 mg/day (deliberately, or, on one occasion, due to non-compliance), his symptoms would relapse. On increasing the steroids to approximately 100 mg/day, they would once again remit.

He was readmitted on 9 April 1991, with a two week history of dysarthria, somnolence, urinary incontinence, and chest pain. The latter was worse on sitting up. Examination at this point revealed him to be severely Cushingoid with gross obesity, striae and acne. He was somnolent, which limited testing of his higher mental function. Visual acuities were 6/12 bilaterally, pupils equal and reactive, and his fundi showed some perivascular sheathing. Extraocular movements were full. He had a brisk jaw jerk, a right upper motor neuron facial weakness, poor gag reflex, and a mild right hemiparesis. Both plantar responses were extensor, but sensory testing was normal.

Pericarditis was suggested by his ECG showing. Repeat MRI scan showed that the lesion had all but disappeared, and there remained only a tiny area of signal change in the right thalamus.

He developed a severe bilateral aspiration pneumonia, was ventilated, treated with broad spectrum antibiotics, but died on 2 June 1991.

### **Pathological examination**

#### **MACROSCOPIC FINDINGS**

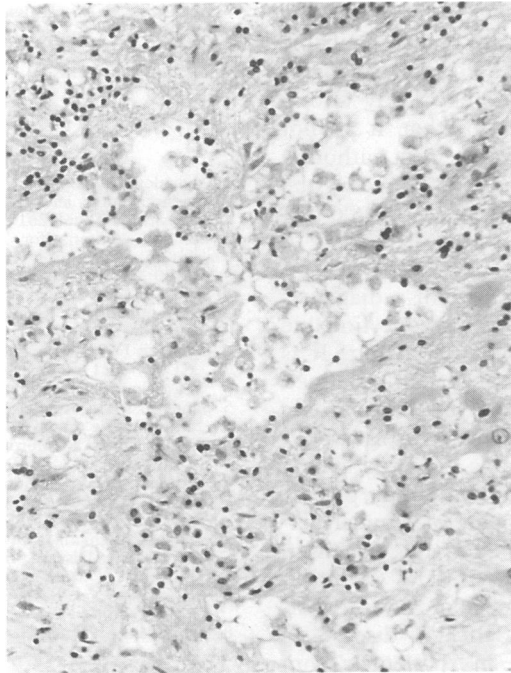
Post mortem examination showed severe bilateral bronchopneumonia. The fixed brain weight was 1270 g. Coronal slices showed small symmetrical lateral ventricles with a slightly dilated third ventricle. There were areas of dark discoloration affecting both thalami and basal ganglia, mainly the putamina (fig 2). Both internal capsules showed irregular, discoloured lesions, and there were also mottled areas in the midbrain and pons. The cerebellum and spinal cord were macroscopically normal.

#### **MICROSCOPIC FINDINGS**

The main histological feature was the presence of multiple small, necrotic lesions affecting both grey and white matter (fig 3). These were more prominent in the deep grey nuclei and brain stem. Both right and left thalami, pallida and putamina were affected. The lesion in the right thalamus extended to the internal capsule and pallidum, and was to some extent cavitated with severe astrocytic gliosis and macrophages replacing the neuropil. There were cuffs of inflammatory cells, mainly lymphocytes, around blood vessels. There was no vessel wall necrosis or evidence of inflammatory cells invading it. No granulomas were present. The lesion involving the left internal capsule and adjacent grey nuclei was less prominent but included some small necrotic areas (see fig 3).

The lesions extended to the midbrain where the inflammatory changes around

**Figure 3** Photomicrograph showing a necrotic lesion in the thalamus. There is total replacement of the neuropil by macrophages and reactive astrocytes. Haematoxylin and eosin  $\times 120$ .



blood vessels were marked. Lesions were seen in the substantia nigra which showed gliosis and moderate loss of pigmented cells. Both superior cerebellar peduncles showed myelin pallor, and both optic tracts showed patchy loss of myelin. The corticospinal tracts were severely damaged showing loss of axons and of myelin.

The pons was affected by several necrotic lesions containing macrophages with severe gliosis and small inflammatory infiltrates. Microglial nodules were common. The medulla and spinal cord were better preserved but showed pallor of the pyramids and corticospinal tracts. The cerebellar vermis and the cerebellar hemispheres, other than some myelin pallor and astrocytosis, did not show the necrotic lesions. There was mild meningitis mainly affecting the basal regions and both Gasserian ganglia showed thickened meninges where some vessels had prominent inflammatory cuffs. In the cerebral hemispheres the cortex was well preserved, but there was some astrocytic gliosis in the subcortical white matter.

Histological examination of both eyes showed a chronic uveitic picture confined predominantly to the anterior uvea, the iris and ciliary body, with a lesser involvement of the choroid. There were ill defined granulomas in the choroid, but the bulk of the chronic inflammation was in the form of lymphocytes, predominantly T cells. No microabscesses were present, a feature described in some cases of ocular Behçet's, although not a common finding in a recent series of five cases.<sup>4</sup> In that study, the predominant T cell subset was CD4+. We were unable to define the T cell subsets in this case as the material had been formalin fixed and paraffin embedded.

Besides the presence of chronic inflammatory changes in the lungs, histological examination of other organs was normal.

## Discussion

This 28 year old patient had a three year history of a relapsing and remitting steroid-sensitive illness. The features of this illness included anterior uveitis with retinal new vessel formation and periphlebitis, and relapsing and remitting cranial nerve palsies, long tract and cerebellar signs. All clinical investigations were normal or negative apart from a mildly raised ESR, a raised CSF lymphocyte count, and an abnormality in the right hemisphere on MRI which had all but disappeared immediately before death. There were no systemic signs of vasculitis, and, in particular, no evidence of oral or genital ulceration, and no arthritis.

While uveitis, retinal new vessels and periphlebitis may all be features of Behçet's disease,<sup>5,6</sup> the most likely ophthalmological diagnosis was considered to be sarcoidosis, mainly because of the patient's ethnic origin and lack of systemic involvement. Similarly, the neurological disease was consistent with neurosarcoidosis,<sup>1</sup> although the radiological appearances at the time of his most recent presentation with pericarditis were atypical and more suggestive of a vasculitic illness of some sort. Possible vasculitides included those of infective aetiology (for example, syphilis, Lyme disease), connective tissue diseases (such as, systemic lupus erythematosus, mixed connective tissue disease, Sjögren's syndrome), or necrotising vasculitides (such as, polyarteritis nodosa, Wegener's). However, the clinical features, laboratory tests, and histology were not supportive of any of these diagnoses.

The neuropathology of Behçet's is that of a disseminated meningo-encephalo-myelitis. Histologically, there are circumscribed foci of necrosis with a marked inflammatory cell reaction in both grey and white matter, particularly in the brainstem, deep grey nuclei, and spinal cord. There is perivascular cuffing, predominantly with mononuclear cells, and gliosis. Degenerative changes in nerve cells are not obvious, and intranuclear inclusion bodies are absent. The blood vessels are usually normal, though minor changes have been reported.<sup>3,7-11</sup>

The histological appearances in our case were entirely compatible with previous reports, suggesting that the most likely pathology was that of Behçet's syndrome. The clinical and CSF features would be consistent with such a diagnosis,<sup>3,12</sup> and the MRI findings were also compatible.<sup>13,14</sup> However, in the absence of a specific test for the condition, a diagnosis of Behçet's disease is currently untenable in the absence of oral ulceration.<sup>2,15</sup>

Sigal<sup>3</sup> mentions that Behçet's disease may present with neurological symptoms before the ulceration becomes apparent. Alema and Bignami<sup>7</sup> suggested that "it is possible that in some cases of Behçet's disease with involvement of the nervous system the disease is not recognised because of the lack of mucocutaneous and ocular lesions". They went on to say that "in one case where only ocular and

neurological symptoms were present, the diagnosis of Behçet's disease seems justifiable on the basis of neuropathological findings." Furthermore, the International Study Group for Behçet's disease admits that it is not impossible for the condition to exist without a history of oral ulceration.<sup>2</sup> Nevertheless, the latter group points out that such cases constitute at most 3% of all those diagnosed to have Behçet's disease.

We suggest that in our patient a diagnosis of Behçet's disease would be unquestionable if the patient had had oral ulceration. It is possible that the condition currently defined as Behçet's disease (see above) may be only one end of a spectrum of this type of vasculitis. Perhaps a new term is required which embraces a "Behçet's-like" vasculitic picture without the full complement of clinical features. A possible term to encompass such an entity would be "Behçet's-MINUS" (multifocal, intermittent neurological and uveitic syndrome). Interestingly, Behçet's disease is much more common in patients from Turkey, the Middle East, and Asia (the "silk route"), and uncommon in patients of West Indian extraction. It may be that the underlying vasculitic process manifests itself differently in different races.

The important aspect of suggesting a new term to include patients who would fulfil the criteria for Behçet's disease but who do not exhibit oral ulceration, is that of management. The treatment of neurosarcoidosis is generally accepted to include corticosteroids and azathioprine, as were used in our case. Although azathioprine is a reasonable treatment for Behçet's,<sup>16</sup> had the patient been diagnosed as either Behçet's, or Behçet's-MINUS, stronger immunosuppressive agents such as cyclosporine or colchicine would have been considered.<sup>17</sup>

We thank Dr R Ross Russell for helpful comments on the manuscript.

- 1 Chapelon C, Ziza JM, Piette JC, *et al.* Neurosarcoidosis: signs, course and treatment in 35 confirmed cases. *Medicine* 1990;60:261-76.
- 2 Editorial. Criteria for Diagnosis of Behçet's Disease. International Study Group for Behçet's Disease. *Lancet* 1990;335:1078-80.
- 3 Sigal LH. The Neurologic Presentation of Vasculitic and Rheumatologic Syndromes. A Review. *Medicine* 1987;66:157-80.
- 4 Charteris DG, Barton K, McCartney ACE, Lightman SL. CD4 + T Lymphocyte Involvement in Ocular Behçet's Disease. *Autoimmunity*, (in press).
- 5 Sanders MD. Retinal arteritis, retinal vasculitis and autoimmune retinal vasculitis. *Eye* 1987;1:441-65.
- 6 Graham EM, Stanford MR, Sanders MD, Kasp E, Dumonde DC. A Point Prevalence Study of 150 Patients with Idiopathic Retinal Vasculitis: 1. Diagnostic Value of Ophthalmological Features. *Br J Ophthalmol* 1989;73:714-21.
- 7 Alema G, Bignami A. Involvement of the Nervous System in Behçet's Disease. In: Monacelli M, Nazzao P, eds. *Behçet's Disease: proceedings of an International Symposium on Behçet's disease, Rome*. Basel: Karger, 1966: 52-66.
- 8 Rubinstein LJ, Urich H. Meningo-encephalitis of Behçet's disease: Case report with pathological findings. *Brain* 1963;86:151-60.
- 9 Wolf SM, Schotland DL, Phillips LL. Involvement of nervous system in Behçet's syndrome. *Arch Neurol* 1965;12:315-25.
- 10 Inaba G. Behçet's Disease. In: McKendall RR, ed. *Handbook of clinical neurology, vol 12 (56): Viral Diseases*. Amsterdam: Elsevier, 1989: 593-610.
- 11 Esiri MM, Kennedy PGE. Virus Diseases. In: Adams JH, Duchon LW, eds. *Greenfield's Neuropathology, 5th ed.* London: Arnold, 1992: 335-99.
- 12 Serdaroglu P, Yazici H, Ozdemir C, Yurdakul S, Bahar S, Aktin E. Neurologic Involvement in Behçet's Syndrome. A Prospective Study. *Arch Neurol* 1989;46:265-9.
- 13 Besana C *et al.* Electrophysiological and MRI evaluation of neurological involvement in Behçet's disease. *J Neurol Neurosurg Psychiatry* 1989;52:749-54.
- 14 Al Kawi MZ, Bohlega S, Banna M. MRI findings in neuro-Behçet's disease. *Neurology* 1991;41:405-8.
- 15 O'Duffy JD. Behçet's syndrome. *New Engl J Med* 1990;322:326-7.
- 16 Yazici H, Pazarli H, Barnes CG, *et al.* A Controlled Trial of Azathioprine in Behçet's Syndrome. *New Engl J Med* 1990;322:281-5.
- 17 Masuda K, Nakajima A, Urayama A, *et al.* Double masked trial of cyclosporin versus colchicine and long-term open study of cyclosporin in Behçet's disease. *Lancet* 1989;1:1093-6.