

## LETTERS TO THE EDITOR

### 'Pinocchio syndrome': a peculiar form of reflex epilepsy?

Reflex epilepsies can be defined as epilepsies in which all or a significant part of the seizures can be regularly provoked by a given triggering factor, most often a sensory stimulus. Sometimes it may be unexpected, such as, reading or decision-making.<sup>1</sup> We report a very unusual epilepsy in which seizures occurred when the patient lied.

A 51 year old patient had recently experienced three attacks with loss of consciousness and generalised convulsions. Afterwards he was confused for a few minutes. These attacks started with sensations the patient had regularly felt several times each day, in clusters of one or two weeks for five years. They consisted of epigastric constriction, a sensation of hot flush rising from his stomach to his head, and then auditory and visual illusions, for instance sensation of hearing in echo or metamorphopsia, with intense anxiety. More than a third of the attacks occurred while the patient was lying, for business reasons. The other episodes occurred without any obvious triggering factor. An EEG showed a right anterior and temporal slowing but no epileptogenic activity. Cerebral MRI showed a meningioma, 30 mm in diameter, located on the right cavernous sinus wall and the anterior clinoid process, near the sella turcica (fig). It compressed the medial part of the right temporal lobe with a mass effect. No further attack has been reported since the introduction of carbamazepine therapy and then meningioma ablation.

The attacks described fit with the diagnosis of partial vegetative seizures and the type of epilepsy fulfils the criteria of reflex epilepsy. Lying has not previously been described as a triggering factor of seizures but, according to certain authors, in some very rare cases seizures have been regularly provoked by emotion.<sup>1,2</sup> Emotions are said

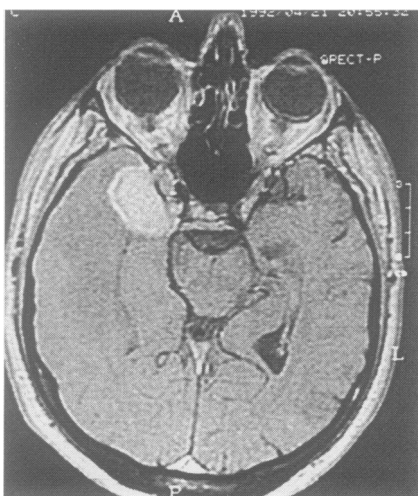


Figure T1 weighted MRI scan after gadolinium injection, showing the meningioma and its effect on temporal lobe.

to be linked to the limbic lobe, whose excitability was probably enhanced by its compression by the meningioma. When the patient was lying he probably felt a particular emotion and this limbic stimulation may have triggered epileptic discharges in the amygdala. As in Collodi's tale, in which lies made Pinocchio's nose grow, our patient's lies became obvious for his interlocutors. As he was an "eurocrat", using lies to evoke the truth in adversarial EEC negotiations, it is thanks to carbamazepine that he has been able to work again.

F SELLAL  
Y CHEVALIER  
M COLLARD  
Neurology Service I,  
Hôpitaux Universitaires de Strasbourg,  
1 place de l'Hôpital,  
67091 Strasbourg Cedex, France

- 1 Beaumanoir A, Gastaut H, Naquet R. *Reflex seizures and reflex epilepsies*. Geneva: Editions Médecine et Hygiène, 1989:555.
- 2 Gastaut H, Tassinari CA. Triggering mechanisms in epilepsy. The electroclinical point of view. *Epilepsia* 1966;7:85-138.

### Acute non-lymphoblast leukaemia presenting as a Guillain-Barré syndrome

Peripheral nerve complications of acute leukaemia are uncommon. The neuropathy in these cases is frequently related to haemorrhage, into a nerve infarction or leukaemic infiltration.<sup>1</sup> Symmetrical peripheral neuropathy in acute leukaemia is much less common and other pathogenic factors could be involved.<sup>2,3</sup> We report a very unusual case of acute non-lymphoblastic leukaemia presented initially as Guillain-Barré syndrome.

This 69 year old man developed symmetrical paresthesiae and painful dysesthesiae of acute onset in the distal lower limbs. In the following days these symptoms increased in severity and he developed generalised progressive weakness, with greater involvement in the legs than in the arms. Four weeks after the appearance of the symptoms he went to a local hospital because he was unable to walk. Routine blood tests revealed severe abnormalities and the patient was immediately admitted to the haematological unit of a central hospital. On admission he was alert, well orientated and pale, and febrile. Blood pressure was 130/60, pulse rate 72/minute and respiratory rate 19/minute. Purpura, lymphadenopathy and hepatosplenomegaly were absent. There was generalised flaccid motor weakness of grade III/V (MRC) in the upper limbs and of grade I/V (MRC) in the lower limbs. Deep tendon reflexes were very much diminished in the arms and were absent in the legs. Pinprick sensation was symmetrically impaired in the lower limbs in a stocking distribution and was preserved in the arms. Joint position and vibration sense were impaired in the legs and preserved in the arms. Signs of meningeal irritation, corticospinal tracts, cranial nerves and autonomic involvement were absent. Higher mental function remained normal. The haemoglobin was 6.7 g/dl without reticulocytes. Leukocyte count was 49.000/mm<sup>3</sup> with 6% polymorphonuclear neutrophils, 5% lymphocytes, 5% monocytes and 84% blast cells. The platelet count was 81.000/mm<sup>3</sup>. Bone marrow aspirate specimen showed increased cellularity due to

infiltration (67%) by blasts, Peroxidase + and 5% of promyelocytes. The haematological diagnosis was classified as acute non-lymphoblastic leukaemia, (FAB classification M2).<sup>4</sup> Chemotherapy was immediately started and included daunorubicin 40 mg/m<sup>2</sup> intravenously for three days and cytosine arabinoside 200 mg/m<sup>2</sup> in continuous perfusion for seven days. A remission of the haematological measures was obtained with one therapeutic cycle, after a 22 day period of aplasia complicated with infection and gastrointestinal haemorrhage. Consolidation of the haematological remission was carried out 38 days after the induction, according to a similar protocol. As postremission therapy, cycles of cytosine arabinoside associated alternatively with VP16, 6-thioguanine and daunorubicin have been performed each month to date.

Considering the severity of the haematological condition on admission and the emergency chemotherapy, lumbar puncture was delayed until nine weeks after the onset of the symptoms. CSF was clear and colourless, with normal opened pressure, cell count (one lymphocyte/mm<sup>3</sup>) and glucose concentration. A pure transudate was found with a protein content of 132 mg/dl (normal <50 mg/dl) and an albumin quotient (CSF/serum albumin × 10<sup>3</sup>) of 38.2 (normal <9). Oligoclonal bands of gamma globulins in serum and CSF protein electrophoresis were not observed. There was no evidence of intrathecal immunoglobulin synthesis. Electrophysiological studies were first performed eight weeks after the onset of symptoms. Motor nerve conduction of median nerve was 38.4 ms<sup>-1</sup> (normal >48 ms<sup>-1</sup>) with a distal motor latency of 4.1 (normal, up to 4.2). Distal sensory action potential was absent. Motor conduction velocity of peroneal nerve was 25 ms<sup>-1</sup> (normal >40 ms<sup>-1</sup>) with a distal motor latency of 8.7 (normal, up to six). Electromyography of the abductor pollicis brevis, tibialis anterior and extensor digitorum brevis muscles revealed a pattern of discrete activity with an increase of mean duration of individual motor unit potentials. Fibrillation potentials and positive waves were observed in these muscles. A sural nerve biopsy showed a mild perivascular mononuclear cell reaction in the endoneurium, and marked demyelination in several foci of nerve fascicles was observed. In addition, there was some axonal degeneration. Leukaemia cell infiltration or areas of necrosis were not present. A progressive improvement of the neurological picture was apparent nine weeks after the onset of symptoms. Thirteen weeks later, he was able to walk without assistance. Two months later, deep tendon reflexes were present though slightly decreased in the legs. Ten months after the onset of the symptoms, the neurological examination was normal and the patient now leads a normal social life and only complains of slight sporadic paresthesie in his feet.

This patient had a neurological illness that fulfilled the criteria for the diagnosis of Guillain-Barré syndrome (GBS):<sup>5</sup> he developed progressive areflexia and symmetrical weakness of all four limbs, and had characteristic CSF and electrophysiological features. The natural course of his neurological illness, with the phases of progression (four weeks), plateau (six weeks) and remission (40 weeks) was also typical of GBS.<sup>5</sup> Cancer patients with GBS differ significantly from non-cancer patients by a more