

Evaluation of the effect of treatment on movement disorders in astrocytomas of the basal ganglia and the thalamus

Joachim K Krauss, Dieter F Braus, Mohsen Mohadjer, Fritz Nobbe, Fritz Mundinger

Abstract

Twenty patients with movement disorders associated with astrocytomas (grade I-IV according to the WHO tumour classification) of the basal ganglia and the thalamus were evaluated for the effects of treatment. Five patients had more than one movement disorder when the histological diagnosis was verified by stereotactic biopsy. Twelve had tremors, eight hemidystonia, three hemichorea, and one hemichorea/ballismus, and myoclonus respectively. Ten patients died during the follow up period, and for the surviving patients follow up periods ranged from 6-21 years. The movement disorders changed over long periods of time related to therapeutic interventions. CSF shunt operations and percutaneous radiotherapy had no definite effect on the movement disorders. There was a moderate response to medical treatment in a few patients. Stereotactic aspiration of tumour cysts had a marked influence on the movement disorder in two patients, and functional stereotactic surgery abolished tumour induced tremor in one. Interstitial radiotherapy was performed in fifteen patients for treatment of the underlying neoplasm and resulted in different and variable alterations of the movement disorders. These differences may be explained by complex interactions involving structures affected primarily by the tumour, as well as by secondary functional lesions of adjacent structures.

(*J Neurol Neurosurg Psychiatry* 1993;56:1113-1118)

Movement disorders (MDs) in tumours of the basal ganglia and the thalamus have been described within a range from 1-9% in recent studies and from 4-33% in earlier ones.¹⁻⁵ The further course following treatment has been documented only rarely in patients with MDs due to basal ganglia and thalamic astrocytomas.⁶⁻²⁰ This study deals with the clinical course and the change and outcome of MDs in relation to treatment of either the tumour responsible for them or of the symptomatic MDs themselves in twenty patients with basal ganglia and thalamic astrocytomas grade I-IV presenting with MDs at the time of biopsy.

Methods

A total of 225 patients had astrocytomas grades I-IV of the basal ganglia or the thalamus confirmed histologically by stereotactic biopsy between 1965-86 in the department of stereotaxy. Twenty were identified as having an MD at the time of biopsy.⁵ The patients were followed up and examined at various times with recent follow ups in 1989, 90 or 91. No follow up data concerning the tremor in patient 16 could be obtained. Some patients had serial film recordings over the years. Most of the long term surviving patients returned at regular intervals for control CT scans. In addition, the relatives, attending physicians and neurologists were interviewed to compile the data.

Stereotactic biopsy was performed under local anaesthesia, except in the younger children. Tumour site, volume and the irradiation dosimetry were determined from CT data available since 1975. The Riechert-Mundinger stereotactic device in the computer-compatible version was used for stereotactic biopsy, interstitial implantation of radioactive isotopes, cyst aspiration and functional stereotactic surgery. The principles and methods are described in detail elsewhere.²¹⁻²⁶ The decision whether or not to perform interstitial radiotherapy was made according to the clinical state of the patient, the tumour size and the results of the intraoperative smear preparation. The presence of an MD was not relevant. Interstitial radiotherapy was performed in the same session via the puncture track for biopsy. To produce radionecroses of the tumours the radioactive isotopes ¹²⁵I (half-life 60.2 days, photon energy spectrum ranging between 27 and 35 keV) and ¹⁹²Ir (half-life 74.2 days, energy spectrum ranging from 300 to 610 keV) were used. The peripheral tumour accumulation dose (that is, at the surface of the tumour) ranged from 90 to 120 Gy. It was exceptionally high in patient 10 (150 Gy), and low (50 Gy) in patient 3. It was generally lower in more recent years.

Shunts placed were either ventriculoatrial or ventriculoperitoneal, and if necessary, bilateral.

Results

The study consisted of eleven female and nine male patients. The age at biopsy ranged from three to 70 years (table). Demographic, clinical and neuroradiological data have been reported recently.⁵ Ten patients were alive on recent follow up. Follow up periods ranged

Department of
Neurosurgery, Albert-
Ludwigs-Universität,
Freiburg
J K Krauss
D F Braus
F Nobbe

Department of
Stereotaxy and
Neuronuclear
Medicine
M Mohadjer

Zentralinstitut für
Seelische Gesundheit
Mannheim
D F Braus

St. Josefs-
Krankenhaus,
Freiburg, Germany
F Mundinger

Correspondence to:
Dr Krauss,
Neurochirurgische
Universitätsklinik,
Hugstetter Str 55, D-7800
Freiburg, Germany.

Received 2 September 1992
and in final revised form
11 December 1992.
Accepted 18 December 1992

Demographic data, treatment and follow-up of 20 patients with movement disorders in basal ganglia and thalamic astrocytomas.

Case	Sex/ Age at Biopsy Age at Onset	Movement disorder	Grade of astro- cytoma	Status	Follow up	KPS: a/b	Interstitial curietherapy	Shunt operation	Other treatment	Movement disorder Course—Outcome
1	M/25/13	Tremor, 3–4 Hz l arm: rest, post, int	I	A	12y	60/80	—	+ (–12y)	Perc. radiotherapy (–12y) Stereotactic aspiration of r thalamic tumour cyst (0)	Dis of tremor after cyst aspiration
2	M/3/3	Tremor, 3–5 Hz l arm > leg; post, int Athetosis, l hand: rest Head tilt	I	D	6m	80	I–125	+ (4m)	Perc. radiotherapy (–4m)	Inc of athetosis (4w), temporary imp with corticosteroids (2m)
3	M/50/44	Tremor, 3–4 Hz l arm > leg: rest, post, int	I	A	8y	60/70	I–125	—	Medication with biperiden	Tremor unc after curie- therapy, slight imp after biperiden
4	F/49/43	Chorea face bilat, l > r l arm > leg	II II–III (8m)	D	2.5y	60	a: Ir-192 b: Ir-192 (8m)	—	Perc. radiotherapy (–4y) Medication with haloperidol (8m)	a: Inc of hemichorea (6m) b: 2 w after 2nd stereotactic operation imp of chorea with haloperidol, dis 2 w later Parkinsonian symptoms unc
5	F/70/70	Parkinsonism	IV	D	1m	40	—	+ (–1w)	—	Fluctuation of intensity of tremor, presumably related to medication with cortico- steroids
6	M/37/31	Tremor, 4–5 Hz l arm: rest, post, int	II	D	4y	60	—	—	—	Inc of tremor + hp (6m), b: unc in further course
7	F/11/10	Dystonia l arm: rest, on action	I	A	9y	60/70	I–125	+ (–3m)	Stereotactic aspiration of tumour cyst (2y) 2nd stereotactic aspiration of tumour cyst (8y)	Inc of hp and dystonia (0.5–1y) imp of hp + dystonia (3y), inc of hp + dystonia (6–7y) imp of hp + dystonia (8y) a: imp of tremor + hp (6m), b: unc in further course
8	M/12/9	Dystonia l hand: on action Tremor, 4–5 Hz l arm: post, int	I	A	13y	70/80	a: Ir-192 b: Ir-192 (9m)	+ (1w) + (2y)	—	—
9	M/42/41	Tremor, 4 Hz r arm: rest, post, int	II	D	2.5y	70	—	—	Medication with biperiden, later with metixen	No response of tremor to biperiden, imp after metixen (1y), later red of tremor with parallel app of hp a: inc of hp and dystonia over years, no change in b: further course
10	M/25/25	Dystonia r arm: rest, on action	I	A	20y	60/60	a: Ir-192 b: Ir-192 (18y)	—	—	Inc of tremor after thioridazine, no response to trihexphenidyl, imp after biperiden, inc of hp, dis of tremor (6 m), spastic hp (7y) Dis of chorea without inc of hp (0.5y), no MD in further course
11	M/15/13	Tremor, 4–5 Hz r arm: rest, post, int	I	A	10y	70/60	I–125	—	Various medication	a: Dis of chorea + ballismus, inc of dystonia + hp (0.5y)
12	F/11/9	Chorea r arm > leg marked on action	II	A	21y	70/80	Ir-192	+ (–2y)	—	post shunt imp of hp, no effect on tremor (–2m), inc of tremor (8m), imp of tremor + app of mild dystonia arm (2y) Postop inc of obtundation, coma (possibly related to inc of edema), death unknown
13	F/10/9	Dystonia l arm > leg Chorea-Ballismus l arm > leg	I III(4y)	D	5y	60	a: Ir-192 b: Ir-192(1y)	+ (4y)	—	—
14	F/12/3	Tremor, 3–5 Hz l arm: rest, post, int	II	A	6y	60/70	I–125	+ (–3m)	—	—
15	M/16/15	Dystonia + Chorea l arm > leg > face: rest, on action	IV	D	3d	40	—	+ (2d)	—	—
16	F/62/59	Tremor, high- frequency bilateral, l > r fingers + eyelids	II	D	6m	60	I–125	—	unknown	—
17	F/13/11	Dystonia, r arm: rest, on action	I	D	5y	70	a: Ir-192 b: Gamma Med (4y)	+ (4d)	—	Imp of dystonia, dis of myoclonus (2y)
18	F/3/2	Myoclonus, r shoulder Tremor, 3–4 Hz r arm: int	I	D	11.5y	70	a: Ir-192 b: Ir-192 (3y) c: Ir-192 (10y)	+ (2w)	—	a: Dis of tremor (6m)
19	F/5/5	Dystonia, r arm: rest, on action	I	A	16y	60/70	a: Ir-192 b: Ir-192 (1y)	+ (1y)	—	a: imp of dystonia + hp (3m), inc of dystonia + app of r chorea (1y), b: inc of hp, imp of dystonia, dis of chorea (3y)
20	F/12/10	Tremor, 3–4 Hz r arm: int	I	A	20y	60/70	a: Ir-192 b: Ir-192 (4y)	—	Functional stereo- tactic operation (4y), Stereotactic aspiration of tumour cyst (15y)	a: Imp of hp + tremor (1y), inc of hp + tremor (3y), b: dis of tremor after functional stereotactic operation, no recurrence of tremor

Sex: M = male, F = female. R = right, L = left. Tremor: is qualified as: rest – tremor at rest, post – postural tremor and int – intention tremor. Status: A = alive (at last follow up available), D = dead. Follow up: is defined as time of survival after stereotactic biopsy at last follow up or until death. KPS (Karnofsky Performance Scale): a: preoperative/b: at last follow-up. All intervals of time refer to stereotactic biopsy: d = days, w = weeks, m = months, y = year(s), — = prior to biopsy.

Movement Disorder Course — Outcome: hp = hemiparesis, app = appearance, inc = increase, unc = unchanged, imp = improvement, red = reduction, dis = disappearance.

from 6–21 years (mean 13.5 years). There were no post operative complications except in patient 15. This 16 year old boy with a thalamic glioblastoma extending to the upper brainstem was in a poor condition when referred. He deteriorated further after biopsy and died three days later, probably due to an increase in intracranial pressure. In the other patients survival ranged from one month to

21 years after biopsy. In two patients anaplastic transformation was found on rebiopsy. Only patients with low-grade astrocytomas survived more than five years. With the exception of case 11, all patients who were alive on recent follow up were stable or had improved Karnofsky Performance Scores.²⁷

MDs in this selected group of patients changed over long periods of time. In most

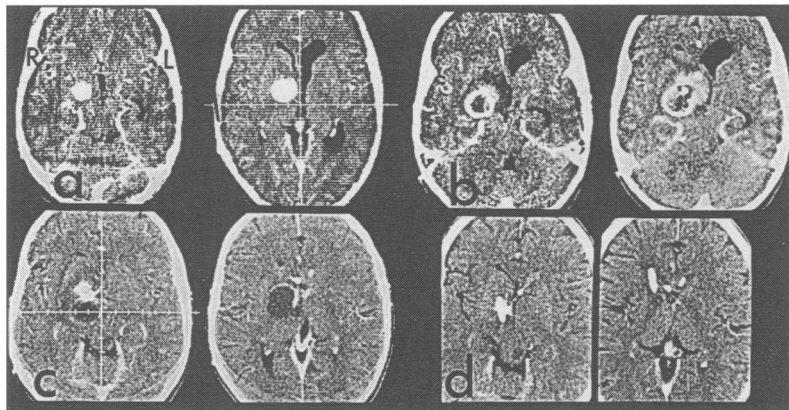


Figure 1 Axial enhanced CT scans of patient 7 with dystonia of the left arm due to a grade I astrocytoma located predominantly in the right pallidum and subthalamic region. The patient has a second tumour extending from the quadrigeminal plate to the pons and cerebellum. a) Before interstitial radiocurietherapy. b) 8 months after implantation of a ^{125}I seed a cyst developed. c) 18 months after interstitial radiotherapy the cyst enlarged. At that time, dystonia and hemiparesis had increased further. d) 24 months after interstitial radiotherapy the cyst was aspirated stereotactically and a drainage was placed. The dystonia and the hemiparesis improved significantly.

cases these changes were temporally related to therapeutic interventions (as described below), or to recurrence or regrowth of tumour as diagnosed neuroradiologically.

Increase of hemiparesis was associated with reduction of the MD in patients 9, 11 and 19. However, in other patients a parallel improvement of the hemiparesis and the MD could be observed (cases 7, 8), or conversely a parallel increase of the hemiparesis and worsening of the MD (cases 10, 13).

OUTCOME IN RELATION TO TYPE OF MOVEMENT DISORDER

The overall outcome of the MD at the last follow up, without respect to therapeutic strategies, was as follows: hemichorea and hemichorea/ballismus disappeared in three patients (cases 4, 12, 13); myoclonus disappeared in one (case 17); tremor disappeared in three patients (cases 1, 18, 20), improved to some degree in five (cases 3, 8, 9, 11, 14), fluctuated in one (case 6), and did not change in two (cases 2, 5); hemidystonia improved to some degree in three patients (cases 7, 17, 19), fluctuated in one (case 2), did not change in one (case 8), and worsened in two (cases 10, 13). In patient 14 with a grade II astrocytoma of the right thalamus extending to the midbrain, contralateral tremor improved two years after interstitial radio-

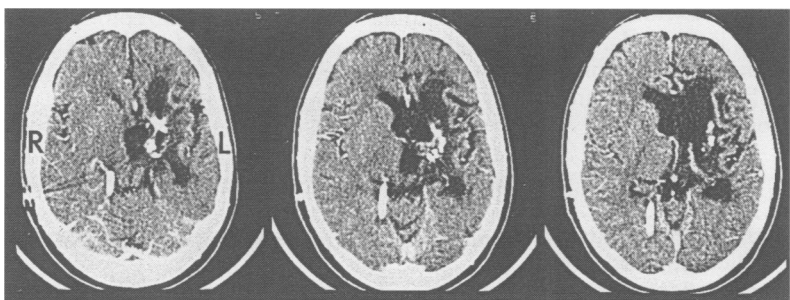


Figure 2 Axial enhanced CT scans of patient 19, 14 years after interstitial radiotherapy with ^{125}I . The patient had presented with dystonia of the right arm due to a grade I astrocytoma of the left thalamus and basal ganglia. She also had transient right hemichorea. The CT scans demonstrate the late effects of radionecrosis with metallic artefacts of the ^{125}I wires, calcifications and gliosis. There is no evidence of residual tumour.

therapy, however, over this period hemidystonic postures appeared. Transient hemichorea was observed one year after interstitial radiotherapy in patient 19.

OUTCOME IN RELATION TO TREATMENT MODALITY

In no patient was partial or radical tumour resection attempted.

Interstitial radiotherapy This was done in 15 patients. 6 were implanted twice, one patient on three occasions. During the first 3–12 months after interstitial radiotherapy, the MD increased, at least temporarily, in some patients (cases 2, 4, 7, 10, 14). CT scans showed signs of radionecrosis with varying degrees of peritumoral white matter oedema (fig 1), depending on the dose and the isotope applied. Twelve to 24 months after the operation, the MD had subsequently improved in patients 7 and 14 to be less severe than preoperatively. However, in other patients who also had signs of radionecrosis on CT controls, the MD improved (cases 8, 17, 19, 20) or even disappeared during the first months following interstitial radiotherapy (cases 11, 12, 17, 18). In three patients a later increase of the MD indicated tumour recurrence or cyst formation (cases 7, 19, 20). In patient 10 with a grade I astrocytoma located mainly in the left lenticulostriate area, hemidystonia increased over many years after interstitial radiotherapy. CT controls did not show local tumour recurrence; however, a porencephalic defect had developed in the region where the tumour was previously located. No signs of tumour recurrence on the last follow up were found in patients 3, 11, 12, 14, 19 and 20 (fig 2). The MD was no longer present in three of them (cases 11, 12, 20) and had improved in three others (cases 3, 14, 19/ case 14 developing hemidystonia).

Functional stereotactic surgery The right intention tremor and hemiparesis of patient 20 (grade I astrocytoma of the left thalamus extending to subthalamus and crus cerebri) which had improved one year after interstitial radiotherapy with ^{125}I worsened again considerably on tumour regrowth after three years. One year later a stereotactic biopsy from the centre of the tumour, which was located more posteriorly in the thalamus, verified tumour recurrence, and another course of interstitial radiotherapy with ^{125}I was given. A biopsy was then taken from the left zona incerta, which did not show tumour cells. Following electrical stimulation, two electrocoagulations were done at the site of the biopsy in the zona incerta. The tremor had disappeared completely postoperatively and did not recur.

Stereotactic aspiration of tumour cysts Two patients had tumour cysts aspirated. Patient 1 had a left 3–4 Hz resting, postural and intention tremor, which disappeared completely after aspiration of a right thalamic tumour cyst extending to the midbrain and did not recur during the 12 year period of follow up (fig 3). Patient 7 showed improvement of left hemiparesis and hemidystonia after aspiration

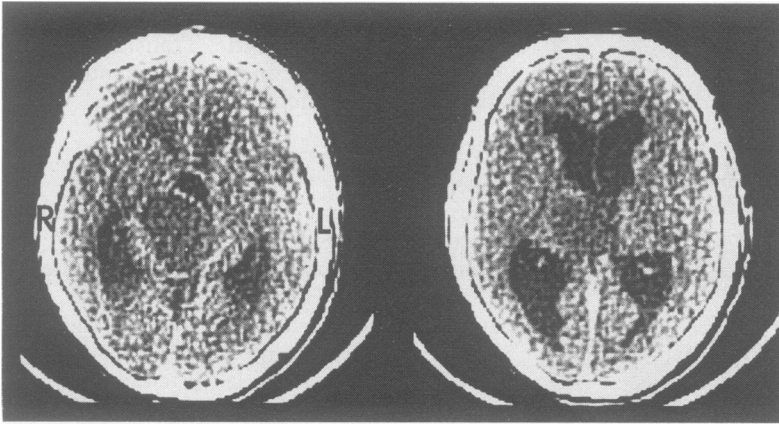


Figure 3 Axial enhanced CT scans of patient 1 who presented with left resting, postural and intention 3–4 Hz tremor show a cystic pilocytic grade I astrocytoma located in the right thalamus. The tremor disappeared after stereotactic aspiration of the tumour cyst.

of a tumour cyst located mainly in the right pallidum and subthalamus two years after interstitial radiotherapy (fig 1). The same effect was achieved six years later.

Percutaneous radiotherapy Three patients had undergone external beam radiation before biopsy. Patients 1 and 4 had no MD at that time and in patient 2 no obvious alterations were noted.

CSF shunts In 12 patients enlarged ventricles were shunted at some time during their disease. Three patients had had no MD when the shunt was placed and in six patients no effect on MDs was observed. A positive effect of shunting may not be excluded totally in two patients with hemidystonia and one with tremor, though improvement was more probably related to interstitial radiotherapy. Multiple revisions of shunts had no influence on MDs in seven patients (cases 1, 5, 7, 8, 12, 17, 19).

Pharmacological trials It was difficult to assess the response to drugs. Many patients took corticosteroids for some time during the course of their disease. In patient 6 with a large diffuse low-grade astrocytoma of the right thalamus, basal ganglia and hemisphere fluctuation in intensity of tremor was related to the dose of corticosteroids. Patient 2 with a mainly thalamic grade I astrocytoma showed a slight improvement in athetosis after corticosteroid therapy. Tremor improved slightly in patients 3 and 11 after treatment with biperiden, whereas no effect on tremor was noted in patient 9, who improved after taking metixen. Tremor increased after thioridazine in patient 11. Chorea in patient 4 with a right frontocaudate astrocytoma improved two weeks after the second course of interstitial radiotherapy while she took haloperidol and disappeared completely two weeks later.

Discussion

The majority of patients with MDs secondary to basal ganglia and thalamic tumours collected from the literature were reported more than three decades ago, most of them having had open surgery. Operations performed were described as subtemporal decompression,^{6,7} exploration,^{6,7} open biopsy,^{10,18} partial resec-

tion,^{6,8,9,13} "paleating operation",¹¹ subtotal¹⁰ and total extirpation.¹² Regardless of which technique was applied, the results in general were poor and the majority of patients died within two months after operation, many of them in the first postoperative days. There are no previous reports on long term follow up, and few data on the subsequent evolution of the MDs. Disappearance or relief of the MD postoperatively was reported after partial resection of tumours affecting parts of the hemisphere and the basal ganglia in three patients: remission of Parkinsonian symptoms,¹³ marked decrease of intention tremor⁶ and disappearance of tremor and rigidity.⁹ One recent patient with a frontotemporal astrocytoma grade I had temporary improvement of hemidystonia after a frontal lobectomy.¹⁵ "Disappearance" of dystonia or choreoathetosis was also reported after removal of basal ganglia or thalamic astrocytomas, but those patients were hemiplegic postoperatively.^{11,12} In two patients with tremor, stereotactic resection of a low-grade astrocytoma of the thalamus was performed¹⁶ resulting in mild improvement of tremor six months later in one of them.¹⁶

Functional stereotactic surgery was only rarely carried out in patients with MDs due to tumours or secondary to treatment of tumour.^{28–30} To our knowledge, its use has never been described in a patient with symptomatic MD due to a thalamic astrocytoma. Shunt operations have been reported to alter MDs in patients with hydrocephalus.^{31,32} However, there was no unequivocal effect on the MDs after shunt operations in the present series. For most previously reported cases, the effect of percutaneous radiotherapy on the MD was either not recorded or was doubtful.^{8,10,12,17,18,20} In two patients with hemidystonia due to contralateral tumours of the basal ganglia the MD was reported to have improved to some degree after percutaneous irradiation.^{15,19}

Experience with medication for MDs secondary to astrocytomas of the basal ganglia and the thalamus is very limited. Apart from one report stating that anti-Parkinsonian drug therapy had no benefit on Parkinsonian symptoms in a 62 year old male with a grade II astrocytoma of the thalamus,¹⁴ we found no other remarks on the effects of drug therapy on tremor. No data are available from the literature on medical treatment of chorea or "choreoathetosis". Moderate improvement of hemidystonia after carbamazepine was described in an eight year old boy with a contralateral low-grade astrocytoma located mainly in the putamen and pallidum.¹⁹

We could not find previous reports on the effect of interstitial radiotherapy on MDs in astrocytomas of the basal ganglia and the thalamus, which as demonstrated, may have complex effects on the later evolution of the MDs.

Interpretation of the data on alterations of MDs in patients with tumours of the basal ganglia and the thalamus—particularly the alterations after interstitial radiotherapy—needs to consider different variables that may

have either synergistic or opposing actions in an individual patient, and thus produce completely different results. We have proposed that MDs in those patients might result from structural lesions as well as from functional damage of structures involved primarily by the tumour ("internal" compression) or of adjacent regions ("external" compression).^{5,33} These interactions may account particularly for the change of MDs in patients who had treatment resulting in modifications of local pressure. Thus, for example, disappearance of tremor in patient 1 after decompression by aspiration of the thalamic tumour cyst probably results from reducing "external" compression on afferent thalamic pathways, and the amelioration of hemidystonia in patient 7 after aspiration of the tumour cyst located mainly in the pallidum and subthalamus might be the result of reducing "external" compression on the thalamus and/or the putamen.

The "internal" or "external" involvement of structures of the basal ganglia known to reduce MDs when lesioned or stimulated (that is, the target points of functional stereotactic surgery) may also change over time in a patient. Interstitial radiotherapy produces sharply delineated radionecrosis with a perifocal zone of demyelination, gliosis and vasogenic oedema, depending on the radioisotope and the dose applied.³⁴⁻³⁶ These sequelae may be responsible for the decrease as well as for the increase of the MDs by changing the degree of "internal" and "external" compression on relevant structures.

In those patients who had no neuroradiological signs of tumour regrowth or recurrence later on, the MD became more or less stable after some years. The residual structural lesions of the basal ganglia and the thalamus after interstitial radiotherapy corresponded to the established clinicopathological correlations between the site of the lesion and the resulting MD.^{5,15,37,38}

The severity of MDs, which may occur together with corticospinal tract dysfunction, is usually inversely related to the severity of the hemiparesis. It is therefore not surprising that MDs may "disappear" in hemiplegia.^{11,12} However, in individual patients with basal ganglia or thalamic tumours there may be different changes in pressure on the corticospinal tract and on "extra-pyramidal" nuclei and pathways, especially after interstitial radiotherapy, depending on the localisation and the extent of the tumour and on the reaction to radiation.

Movement disorders in most patients with astrocytomas of the basal ganglia and the thalamus are subject to change in the long term. Their evolution is more dynamic than that of other MDs secondary to basal ganglia lesions being influenced by therapeutic interventions and the growth or regrowth of the tumours.

Although symptomatic medical or surgical measures may sometimes alleviate the MD, treatment should primarily be directed to the neoplasm causing the MD.

We thank G Pfister, H Förster, K Roskamm and V Sonntag-O'Brien for technical assistance and preparation of the manuscript.

- 1 Kelly PJ. Stereotactic biopsy and resection of thalamic astrocytomas. *Neurosurgery* 1989;25:185-95.
- 2 Bernstein M, Hoffman HJ, Halliday WC, Hendrick EB, Humphreys RB. Thalamic tumors in children. *J Neurosurg* 1984;61:649-56.
- 3 McKissock W, Paine KWE. Primary tumours of the thalamus. *Brain* 1958;81:41-63.
- 4 Tovi D, Schisano G, Liljequist B. Primary tumors of the region of the thalamus. *J Neurosurg* 1961;18:730-40.
- 5 Krauss JK, Nobbe F, Wakhloo AK, Mohadjer M, Vach W, Mundinger F. Movement disorders in astrocytomas of the basal ganglia and the thalamus. *J Neurol Neurosurg Psychiatry* 1992;55:1162-7.
- 6 Ody F. Tumors of the basal ganglia. *Arch Neurol Psychiatr* 1932;27:249-69.
- 7 Globus JH, Kuhlbeck H. Tumors of the striatohalamic and related regions. *Arch Pathol* 1942;34:674-734.
- 8 Roth RL, Bebin J. Cerebral hemispheric tumors and extrapyramidal signs and symptoms. *Neurology* 1958;8:277-84.
- 9 Tolosa E, Vilato J, Fuenmayor P. Parkinsonisme tumoral. *Neurochirurgia* 1966;12:555-60.
- 10 Cheek WR, Taveras JM. Thalamic tumors. *J Neurosurg* 1966;24:505-13.
- 11 Arseni C, Nash F, Samitka DC. Extra-pyramidal syndromes with intracranial tumour. *Psychiat Neurol* 1959;137:230-44.
- 12 Chorobski J. Involuntary movements in patients with intracranial tumors. *Arch Neurol* 1962;6:27-42.
- 13 Garcin R, Klein MR, Kipfer M, Bozec L. Hémisindrome parkinsonien gauche par tumeur fronto-calleuse droite disparaissant complètement apres ablation de celle-ci. *Rev Neurol* 1943;3:80-3.
- 14 Kulali A, Tugtekin M, Ütkür Y, Erkurt S. Ipsilateral hemi-parkinsonism secondary to an astrocytoma. *J Neurol Neurosurg Psychiatry* 1991;54:653.
- 15 Marsden CD, Obeso JA, Zarranz JJ, Lang AE. The anatomical basis of symptomatic hemidystonia. *Brain* 1985;108:463-83.
- 16 McGirr SJ, Kelly PJ, Scheithauer BW. Stereotactic resection of juvenile pilocytic astrocytomas of the thalamus and basal ganglia. *Neurosurgery* 1987;20:447-52.
- 17 Mettler FA, Davidoff LM, Grimes R. Static tremor with hemiplegia. *Arch Neurol Psychiatr* 1947;57:423-9.
- 18 Millichap JG, Miller RH, Backus RE. Intracranial tumors in childhood. *JAMA* 1962;179:589-93.
- 19 Narbona J, Obeso JA, Tunon T, Martinez-Lage JM, Marsden CD. Hemi-dystonia secondary to localised basal ganglia tumour. *J Neurol Neurosurg Psychiatry* 1984;47:704-9.
- 20 Sciarra D, Sprockin BE. Symptoms and signs referable to the basal ganglia in brain tumor. *Arch Neurol Psychiatr* 1953;69:450-61.
- 21 Birg W, Mundinger F. Computer calculations of target parameters for a stereotactic apparatus. *Acta Neurochir* 1973;29:123-9.
- 22 Mundinger F. CT-stereotactic biopsy for optimizing the therapy of intracranial processes. *Acta Neurochir Suppl* 1985;35:70-4.
- 23 Mundinger F, Riechert T. Die stereotaktischen Hirnoperationen zur Behandlung extrapyramidalen Bewegungsstörungen (Parkinsonismus und Hyperkinesen) und ihre Resultate. *Fortschr Neurol Psych* 1963;31:1-66, 69-120.
- 24 Riechert T, Mundinger F. Beschreibung und Anwendung eines Zielgerätes für stereotaktische Hirnoperationen (2. Modell). *Acta Neurochir* 1956;3:308-37.
- 25 Mundinger F, Braus DF, Krauss JK, Birg W. Long-term outcome of 89 low-grade brain-stem gliomas after interstitial radiation therapy. *J Neurosurg* 1991;75:740-6.
- 26 Mundinger F, Sauerwein. "GammaMed", ein neues Gerät zur interstitiellen, nur einige Minuten dauernden Bestrahlung von Hirngeschwülsten mit Radioisotopen, auch intraoperativ anwendbar. *Acta Radiol* 1966;5:48-52.
- 27 Karnofsky DA, Burchenal JH. The clinical evaluation of chemotherapeutic agents in cancer. In: MacLeod CM, ed. *Evaluation of chemotherapeutic agents*. New York: Columbia University Press, 1949;191-205.
- 28 Nittner K. Doppelseitige einzeitige stereotaktische Hirnoperation nach Hirntumoroperation. *Nervenarzt* 1965;36:394-7.
- 29 Hirai T, Miyazaki M, Nakajima H. The correlation between tremor characteristics and the predicted volume of effective lesions in stereotaxic nucleus ventralis intermedius thalamotomy. *Brain* 1983;106:1001-18.
- 30 Maeda H, Kondo T, Ohye C, Narabayashi H. Physiologically controlled VIM thalamotomy for red nucleus syndrome. *Appl Neurophysiol* 1979;42:310-1 (Abst).
- 31 Jensen F, Jensen FT. Acquired hydrocephalus. *Acta Neurochir* 1979;46:119-33.
- 32 Sybert GW, Leffman H, Ojemann GA. Occult normal pressure hydrocephalus manifested by parkinsonism-dementia complex. *Neurology* 1973;23:234-8.
- 33 Krauss JK, Mohadjer M, Nobbe F, Scheremet R. Hemidystonia due to a contralateral parieto-occipital metastasis: disappearance after removal of the mass

- lesion. *Neurology* 1991;41:1519-20.
- 34 Groothuis DR, Wright DC, Ostertag CB. The effect of ¹²⁵I interstitial radiotherapy on blood-brain barrier function in normal canine brain. *J Neurosurg* 1987;67:895-902.
- 35 Ostertag CB, Groothuis D, Kleihues P. Experimental data on early and late morphologic effects of permanently implanted gamma and beta sources (iridium-192, iodine-125 and yttrium-90) in the brain. *Acta Neurochir Suppl* 1984;33:271-80.
- 36 Ostertag CB, Weigel K, Warnke P, Lombeck G, Kleihues P. Sequential morphological changes in the dog brain after interstitial iodine-125 irradiation. *Neurosurgery* 1983;13:523-8.
- 37 Pettigrew LC, Jankovic J. Hemidystonia: a report of 22 patients and a review of the literature. *J Neurol Neurosurg Psychiatry* 1985;48:650-7.
- 38 Krauss JK, Mohadjer M, Braus DF, Wakhloo AK, Nobbe F, Munding F. Dystonia following head trauma: a report of nine patients and review of the literature. *Mov Disord* 1992;7:263-72.