

recombinant chromosome originating from a carrier parent. Mules and Stamberg⁵ also found the risk for liveborn recombinants to be low.

No cytogenetic information was available on the fetal tissue from the mother's two spontaneous abortions in our case. Mules and Stamberg,⁵ however, reported that paracentric inversion carriers seem to be at some risk of pregnancy wastage. Their data indicate that about one third of these pregnancies ended in spontaneous abortion.

In conclusion, it is advisable for all paracentric inversion carriers to have prenatal chromosome analysis performed on every pregnancy, even though the risk of recombination may be low. X chromosome inactivation studies are also recommended for inv(X) female carriers. The commonly accepted theory for inactivation of X chromosomes with duplications or deficiencies of material is that the abnormal X is inactivated to avoid genetic imbalance. Therefore, non-random inactivation of an inv(X) may indicate whether or not the rearrangement is balanced, and be a significant factor in counselling parents of a carrier male fetus.

References

- ¹ Sparkes RS, Salter WJ, Blaker RG, Muller HM. Insertional translocation into the X chromosome of a 46,XY male. *Clin Genet* 1977;12:114-8.
- ² Tiepolo L, Zuffardi O, Rodewald A. Nullisomy for the distal portion of Xp in a male child with X/Y translocation. *Hum Genet* 1977;39:277-81.
- ³ Brøndum Nielsen K, Langkjær F. Inherited partial X chromosome duplication in a mentally retarded male. *J Med Genet* 1982;19:222-4.
- ⁴ Venter PA, Dawson B, DuToit JL, et al. A familial paracentric inversion: a short review of the current status. *Hum Genet* 1984;67:121-5.
- ⁵ Mules EH, Stamberg J. Reproductive outcomes of paracentric inversion carriers: report of a liveborn dicentric recombinant and literature review. *Hum Genet* 1984;67:126-31.

Correspondence and requests for reprints to Dr Richard L Neu, Department of Pediatrics, University of South Florida College of Medicine, 12901 N 30th Street, Box 15-G, Tampa, Florida 33612-4799, USA.

A recognisable short stature syndrome with premature aging and pigmented naevi

M BARAITSER*, J INSLEY†, AND R M WINTER‡

*The Hospital for Sick Children, Great Ormond Street, London; †The Infant Development Unit, Birmingham Maternity Hospital, Edgbaston, Birmingham; and ‡The Kennedy-Galton Centre for Clinical Genetics, Harperbury Hospital, Harper Lane, Radlett, Herts.

SUMMARY We report the progress up to the age of seven years of a small for dates baby whose face and neck are strikingly devoid of subcutaneous tissue and who has, in addition, multiple pigmented naevi.

In 1975 Mulvihill and Smith¹ published a short case report which they entitled 'Another disorder with prenatal shortness of stature and premature aging'. There had been one previous report by Shepard² in 1971 with a review of the same patient by Elliott³ in 1975. Both publications appeared in the *Birth Defects* series which is not easily accessible to many clinicians. A case recently seen, now the third, has prompted us to make the condition more widely known. The diagnosis was made using the London Computerised Dysmorphology Database by asking

for the retrieval of all the syndromes with short stature, naevi, and premature aging.

Case report (figs 1 to 4)

The proband, a male, was the first born child of a healthy, 34 year old mother and an unrelated 36 year old father after a normal pregnancy apart from intrauterine growth retardation. They have since produced a normal girl. The fetus grew poorly and weighed 1.88 kg after 39 weeks' gestation. His length was 43 cm and his head circumference 31 cm, both below the 3rd centile. The facial appearance with its lack of subcutaneous tissue was striking in infancy but the features have become accentuated over the years. The lower jaw remains small and the ears are somewhat prominent with deficient lobules. The trunk, though profoundly small, is well covered with subcutaneous tissue.

Fig 5 portrays his progress until the age of seven years. His voice is high and piping and speech, though perfectly constructed, is difficult to follow.

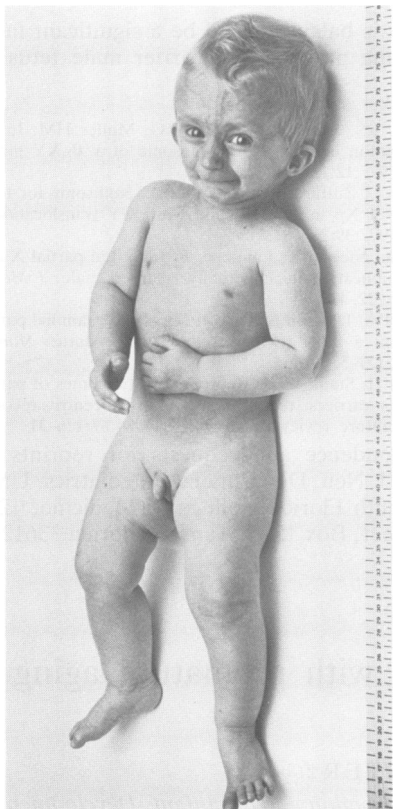


FIG 1 The proband at eight and a half months. Note normal fat distribution over trunk.

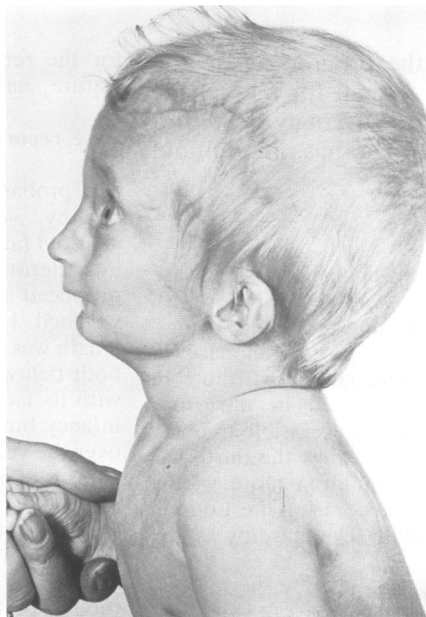
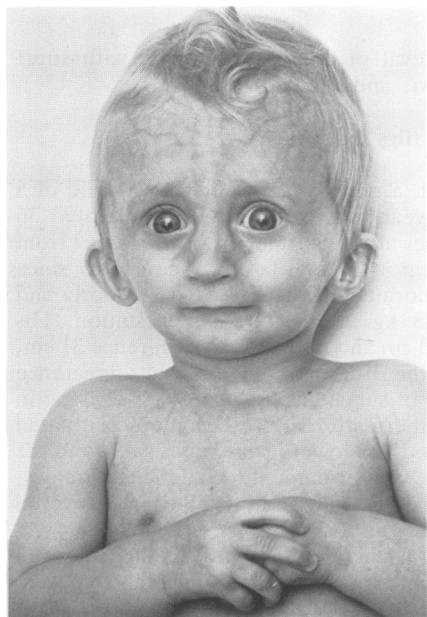


FIG 2 AP and lateral view of proband at eight and a half months. Note premature aging.

The larynx has not been formally examined, but the tongue and palate are normal. Intellectually, he is mildly slow for his age. Further thinning of the subcutaneous tissue around the neck and face and the appearance of pigmented naevi and depigmented naevi over the body are striking. At the age of six years painless liver enlargement was noted and this was accompanied by a modest rise of both AST and alanine transaminases but without jaundice. Alpha₁ antitrypsin, AFP, gamma GT, albumin, and globulin levels were all normal. IgG was slightly low at 5.0 g/l. Plasma amino acid electrophoresis was normal and so was a coagulation screen. Skeletal survey at one year was normal but the bone age, estimated at a chronological age of 6.3 years, was advanced to 10.2 years. Thyroxine (126 nmol/l) and free thyroxine (17.0 pmol/l) were normal. A chromosomal analysis in 1985 was normal.

Discussion

The main features in the three reported cases are summarised in the table.

A more complete clinical picture of this rare condition is beginning to emerge. Mulvihill and Smith¹ in their paper ask for additional information about some of the features which they thought might not necessarily be part of the syndrome. Of these, diabetes and multiple childhood infections were not present in our case. He did, however, have a moderately low IgG as was present in their case. A disturbing feature in our patient is the progressive

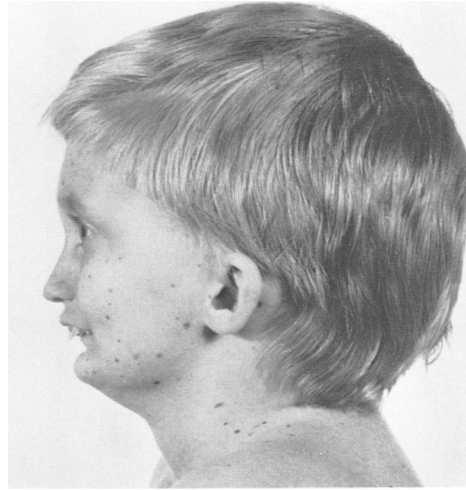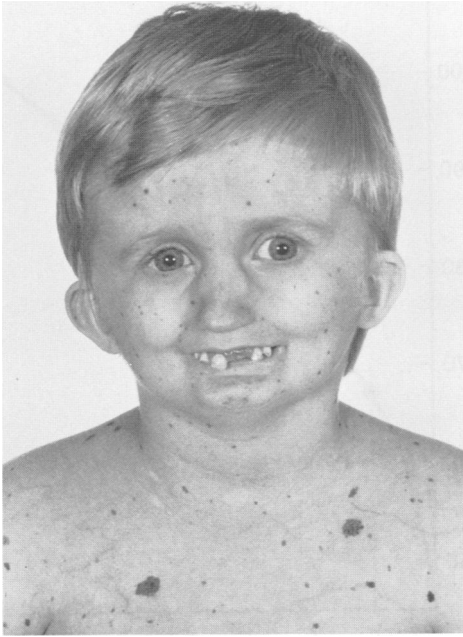


FIG 3 AP and lateral view of proband at seven years showing a bird-like face, a small jaw, irregular dentition, pigmented and depigmented naevi, and accentuation of premature aged appearance.

enlargement of the liver first noted at six years with abnormal liver function. The patient described by Elliott³ also had hepatomegaly but the liver function tests were normal.

Another unexpected difference was in the bone age. In the patient of Mulvihill and Smith¹ and Elliott,³ it was appropriate for chronological age

whereas, in our patient, at a chronological age of six years the bone age was advanced to 10 years. Despite these differences the three patients are strikingly similar and clearly have the same condition.

There are a number of other syndromes characterised by premature aging. Cockayne syndrome is

TABLE Clinical features of the three cases.

	<i>Elliott³</i>	<i>Mulvihill and Smith¹</i>	<i>Present case</i>
Low birth weight	+	+	+
Short stature	+	+	+
Microcephaly	-	+	+
Mild to moderate mental retardation	+	+	+
Multiple pigmented naevi	+	+	+
Bird-like face	+	+	+
Lack of facial subcutaneous fat	+	+	+
Small pointed chin	+	+	+
Prominent ear lobes	±	+	+
Broad forehead	+	+	+
Normal subcutaneous tissue elsewhere	+	+	+
High pitched voice	?	+	+
Hypospadias	+	+	+
Sensorineural hearing loss	-	+	+
Hypodontia or irregular dentition	+	+	+
Hair	Fine, silky	Fine, sparse	Fine
Mild hypertelorism	+	±	-

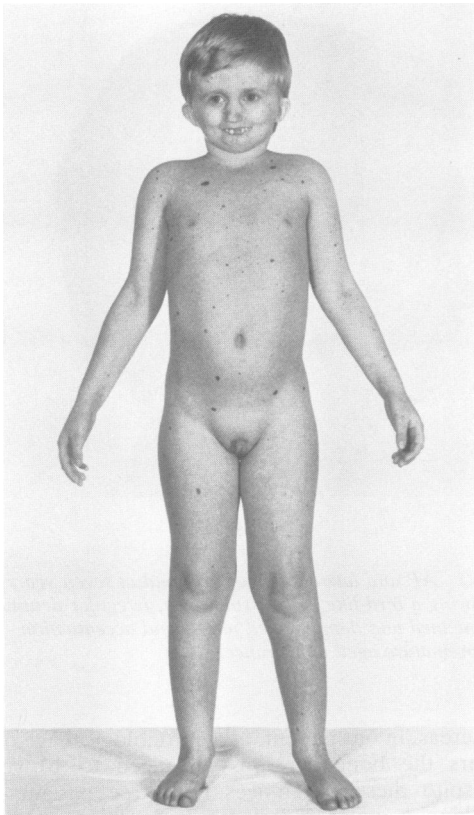


FIG 4 Full length view of the proband showing normal subcutaneous tissue over lower trunk and legs.

different in that it has an onset in the second year of life with progressive neurological deterioration, joint contractures, peripheral neuropathy, cataracts, and photosensitivity. Those affected lose subcutaneous fat in an unusual distribution causing a sunken eye and sharp nose appearance. There is an early onset Cockayne syndrome, but growth diminishes disastrously within the first year of life and most die before the third year.

Progeria has a distinct phenotype caused in part by the bird-like face, lack of scalp hair, and generalised loss of subcutaneous fat. A brown/yellow skin pigmentation develops in most and pigmented naevi are not usually part of the condition. The age of onset in Werner's syndrome is in early adulthood and the skin lesion in Rothmund-Thomson syndrome is characteristically a poikiloderma, which appears red with areas of atrophy.

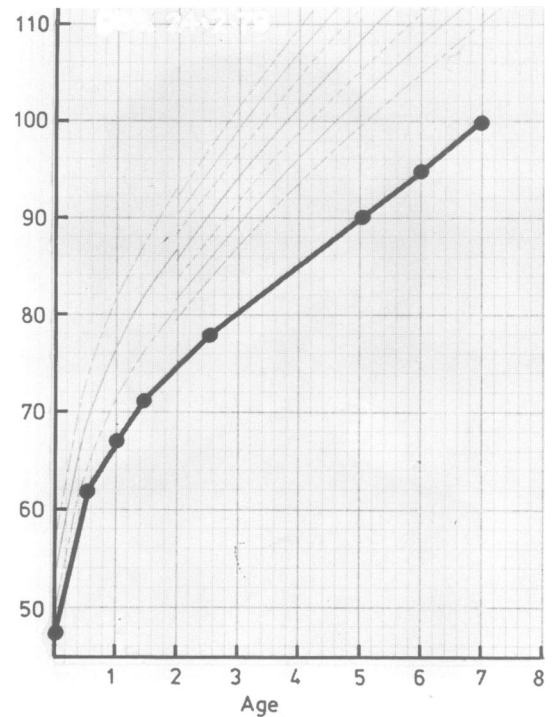


FIG 5 Growth chart from 0 to 7 years.

Perhaps the most helpful diagnostic features and those that led to the diagnosis in this case are the pigmented naevi in a child with short stature (of prenatal onset) and premature aging. In our patient these features have become more noticeable with age. All three cases have been single and the aetiology awaits further reports.

References

- Mulvihill JJ, Smith DW. Another disorder with prenatal shortness of stature and premature aging. *Birth Defects* 1975;XI (2):368-71.
- Shepard MK. An unidentified syndrome with abnormality of skin and hair. *Birth Defects* 1971;VII (8):353-4.
- Elliott DE. Undiagnosed syndrome of psychomotor retardation, low birthweight dwarfism, skeletal, dental, dermal and genital anomalies. *Birth Defects* 1975;XI (2):364-7.

Correspondence and requests for reprints to Dr M Baraitser, Clinical Genetics Unit, The Hospital for Sick Children, Great Ormond Street, London WC1N 3JH.