

right or inverted into chromosome 2 at q21 (fig 6). The karyotype of the balanced carriers was 46,XX,inv?ins(2;7)(q21;q32q34), or in more detailed form, 46,XX,inv?ins(2;7)(2pter→2q21::7q32→7q34::2q21→2qter;7pter→7q32::7q34→7qter). The proband's karyotype was 46,XY,der(2)inv?ins(2;7)(q21;q32q34)mat, or in more detailed form, 46,XY,der(2)inv?ins(2;7)(2pter→2q21::7q32→7q34::2q21→2qter)mat.

The father (III.1) has a normal karyotype with an enlarged satellite region on one chromosome 21 which has apparently been inherited by the index case but not by his sister.

The genetical imbalance of the index case IV.2 is therefore a duplication of the segment 7q32→q34. In addition, there may be effects on control of rearranged genes in the vicinity of the breakpoints.

### Discussion

Absence of an external ocular muscle has not previously been described in association with chromosomal abnormalities and there have been only a few reports of absent eye muscles in association with a syndrome. It has been reported with Axenfeld's anomaly<sup>1</sup> and Apert's syndrome.<sup>2</sup> In Duane's syndrome, in which there is little or no abduction beyond the midline, the lateral rectus muscle is well formed, but the sixth cranial nerve nucleus is absent

and the muscle is innervated from the third cranial nerve nucleus.

We have not found any other record of duplication of the segment 7q32→q34. The numerous case reports cited by Schinzel<sup>3</sup> of dup(7)(q32→qter) describe variable features which are not found in our case. However, Nielsen *et al*<sup>4</sup> reported one family transmitting 46,XX,ins(13;7)(q32;q34): three children had a deletion of 7q32→q34, all were retarded, and one, a girl, had bilateral optic atrophy and hypermetropia. This family is obviously at risk of segregating the duplication of this segment 7q32→q34 as in our case. The palatal ridging, skin creases on the soles, absent eye muscle, and optic nerve hypoplasia of our patient are unusual features which may be characteristic of 7q32→q34 duplication.

### References

- 1 Sandall GS, Morrison JW Jr. Congenital absence of lateral rectus muscle. *J Pediatr Ophthalmol Strabismus* 1979;16:35-9.
- 2 Morax S, Pascal D. Absence of the right superior rectus muscle in Apert's syndrome. *J Fr Ophthalmol* 1982;5:323-6.
- 3 Schinzel A. *Catalogue of unbalanced chromosome aberrations in man*. Berlin, New York: Walter de Gruyter, 1984:291-2.
- 4 Nielsen KB, Egede F, Mouridsen I, Mohr J. Familial partial 7q monosomy resulting from segregation of an insertional chromosome rearrangement. *J Med Genet* 1979;16:461-6.

Correspondence and requests for reprints to Mr C Gregory Keith, FRCS, 231 Flemington Road, North Melbourne, Victoria 3051, Australia.

## Concurrent de novo interstitial deletion of band 2p22 and reciprocal translocation (3;7)(p21;q22)

G C WEBB, C G KEITH, AND N T CAMPBELL

*Departments of Genetics, Ophthalmology, and Neonatology, Royal Children's Hospital, Melbourne, Australia.*

**SUMMARY** A child is described with a de novo interstitial deletion of band 2p22 and a reciprocal translocation (3;7)(p21;q22). The child has mild developmental delay, coloboma of the right eye, and Hirschsprung's disease. The clinical and cytogenetic findings are described.

### Case report

The proband, the second child of normal unrelated parents aged 28 and 30, was born at term by elective lower segment caesarian section. Birth weight was 3035 g and the Apgar scores were 8 at one minute and 10 at five minutes. She was mildly jaundiced, lethargic, and floppy at birth. The only dysmorphic

features noted were epicanthic folds and coloboma of the right iris, which was atypical, being upwards and medially located (fig 1). Shortly after birth she developed respiratory distress, abdominal distension, and persistent vomiting. Abdominal x rays revealed generalised bowel distension with multiple fluid levels. A suction rectal biopsy showed an absence of ganglion cells and was acetylcholinesterase positive. A diagnosis of Hirschsprung's disease was made. A left iliac fossa loop colostomy was per-

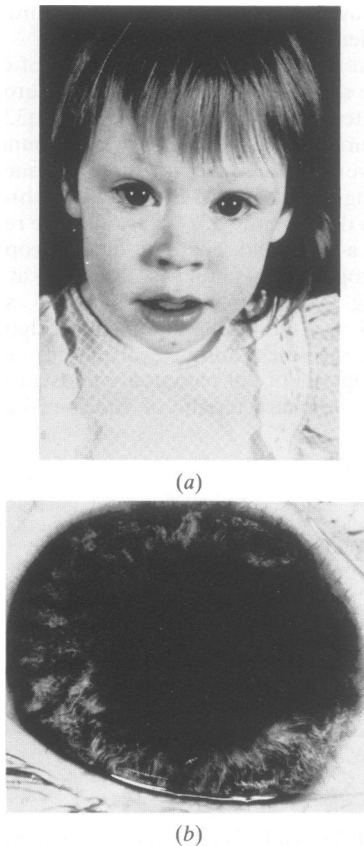


FIG 1 (a) Facial appearance of the proband. (b) Right eye showing coloboma of the iris.

formed on day 3. Seromuscular biopsy revealed ganglion cells at the low pelvic colon level. The colostomy was closed when the child was two years old after Duhamel's pull through procedure. The child achieved continence by four years of age. At three years of age Shepherd's tubes were fitted when the child developed conductive deafness associated with unresolving middle ear infections. There is no visual handicap associated with the coloboma.

Overall development has been delayed. Gross motor development has been affected by increased mobility of the hip and wrist joints. The child was walking at the age of two, but still unsteady at three years. When she was assessed at three years two months of age she was found to be functioning generally at around an 18 month level of development, though possibly lower in language skills. At four years of age, she was performing at a three to three and a half year level except for receptive

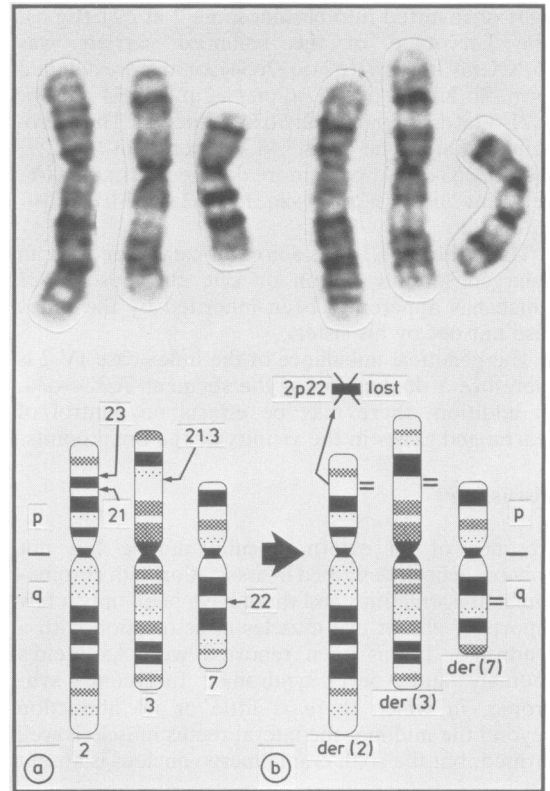


FIG 2 Partial karyotype of the proband and diagram showing chromosomes 2, 3, and 7 in (a) the normal and (b) rearranged states.

language which was at a two year old level. She has had regular speech therapy, has attended normal kindergarten, and has recently entered the regular school system.

#### CYTOGENETIC FINDINGS

Cytogenetic analysis of peripheral blood lymphocytes using GTL banding and prophasic technique revealed an interstitial deletion with breakpoints in 2p21 and 2p23.1. Both of these breakpoints were very close to the margins of 2p22 so the resulting deletion is primarily of the dark band, leaving the adjacent pale bands apparently intact (fig 2). As well as this deletion, all cells, in a total of 50 examined, had an apparently balanced translocation,  $t(3;7)(p21;q22.1)$ . The imbalance of genetic material results from deletion of band 2p22. Parental chromosomes were normal with the father having a variant short arm of one chromosome 15 which was transmitted to the affected daughter.

The karyotype of the proband is  $46,XX,del(2)$

(p21p23·1),t(3;7)(p21·3;q22·1). In the complete nomenclature it is 46,XX,der(2)(pter→p21::p23·1→qter), der(3)(7qter→7q22·1::3p21·3→3qter), der(7)(7pter→7q22·1::3p21·3→3pter). There have been only two reports of interstitial deletion of the short arm of chromosome 2 and neither involved band 2p22; similarly, t(3;7)(p21·3;q22·1) has not previously been reported.<sup>1</sup>

### Discussion

Specific phenotypic abnormalities associated with a small chromosome deletion provide some evidence that those abnormalities might map to that region of the karyotype. In the present case two specific abnormalities, atypical coloboma of the iris and Hirschsprung's disease, were seen in association with a small deletion of the band 2p22; however, only coloboma of the iris has been previously reported associated with a deletion of chromosome 2,<sup>2</sup> but of a different region, 2p25·1→pter. The situation is complicated by both Hirschsprung's disease and coloboma of the iris being probably multifactorial in their causation.<sup>3</sup>

Apart from the concordance of a small specific deletion with well defined physical features, the major interest in this case lies in the possible origin of two apparently independent chromosomal rearrangements. The simplest interpretation is the mis-repair of four simultaneous breaks. This gains

support from the many rearrangements which have been observed to occur after three or more breaks. In almost all of these, the rearranged chromosomes are such that it is necessary to postulate simultaneous breaks. Although it is possible that the deletion and translocation seen in the proband were successive events, there is no evidence to support this, such as mosaicism, or the presence of a balanced translocation in one parent.

Cases such as this support the hypothesis that at least in some cells breaks are being repaired. It is possible that multiple breaks occur frequently in all cells, but repair results in normal chromosomes, and it is only the occasional error of rejoining that permits observation of this activity.

The authors thank Ms L Voullaire and Ms H Sparks for assistance in the preparation of the manuscript.

### References

- <sup>1</sup> Schinzel. A. *Catalogue of unbalanced chromosome aberrations in man*. Berlin, New York: de Gruyter, 1984.
- <sup>2</sup> Arias S, Rolo M, Gonzalez N. Human gene mapping 7. *Cytogenet Cell Genet* 1984;37:401.
- <sup>3</sup> McKusick VA. *Mendelian inheritance in man*. 6th ed. Baltimore: Johns Hopkins University Press, 1983.

Correspondence and requests for reprints to Dr G C Webb, Department of Genetics, Royal Children's Hospital, Flemington Road, Parkville 3052, Victoria, Australia.