

Johanson-Blizzard syndrome

JANE A HURST AND MICHAEL BARAITSER

From the Department of Clinical Genetics, Institute of Child Health, 30 Guilford Street, London WC1N 1EH.

In 1971 Johanson and Blizzard¹ reported a new syndrome in three unrelated girls characterised by congenital aplasia of the alae nasi, deafness, hypothyroidism, dwarfism, absent permanent teeth, and malabsorption. Children with this syndrome had been described earlier by Morris and Fisher in 1967² and Townes in 1969³ as examples of trypsinogen deficiency disease. Townes and White⁴ subsequently reviewed the patient reported in 1969³ and described the presence of additional features which confirmed the diagnosis of the Johanson-Blizzard syndrome. There have since been 22 patients reported with Johanson-Blizzard syndrome, and a further seven children related to these. The spectrum of associated features is now well documented and the inheritance of the syndrome is autosomal recessive. However, there remain many problems which make counselling difficult, in particular the degree of mental handicap and the observation that some children die from complications of the severe malabsorption despite intensive treatment. This article reviews the 22 patients previously reported and also includes details of a previously unreported boy.

Clinical features

The main features are shown in the table. The most constant signs necessary to make a diagnosis are aplasia of the alae nasi, an exocrine pancreatic defect, and unusual hair growth pattern.

In the absence of major structural abnormalities, the affected infant usually comes to medical attention because of failure to thrive. On presentation, the infant is malnourished, hypotonic, and often oedematous because of hypoproteinaemia.

THE FACE

The diagnosis should be made easily in the neonatal period. Indeed the 'gestalt' of the Johanson-Blizzard syndrome is so distinct that seen once it should not

be missed (figs 1 and 2). The picture is determined by the unusual nasal configuration. The severe aplasia of the alae nasi leads to the appearance of a

TABLE Frequency of features in the Johanson-Blizzard syndrome

	Reported cases (n=22)	This case
Hypoplastic alae nasi	22	+
Pancreatic insufficiency/failure to thrive	21	+
Aplasia cutis congenita	19	-
Short stature	15	+
Mental retardation	13	Mild
Dental anomalies	13	+
Deafness	12	+
Anorectal anomalies	11	-
Microcephaly	8	-
Genitourinary abnormalities	7	-
Hypothyroidism	6	+
Cardiac malformation	3	-

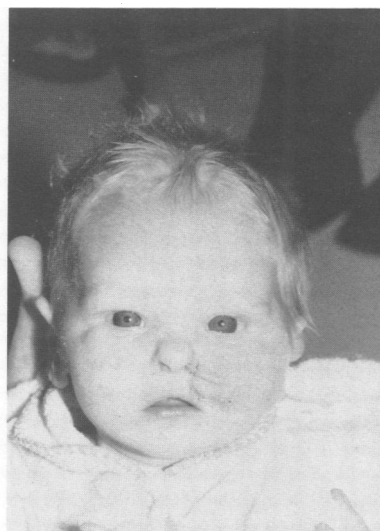


FIG 1 Our patient, a boy, aged two months. Note the small nose with aplasia of the alae nasi and the abnormal hair growth pattern, also shown in fig 3.

thin, torpedo shaped nose with large nostrils. In addition, the hair is swept up, especially frontally (fig 3), and has a patchy distribution over the scalp. Closer inspection shows areas of alopecia (fig 4) with underlying aplasia cutis congenita, which are

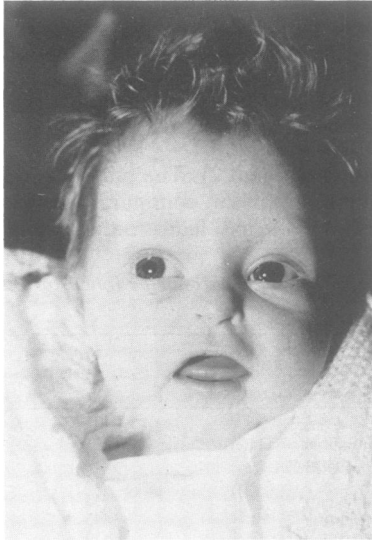

FIG 2 *Strikingly similar facial features are seen in this unrelated girl.*

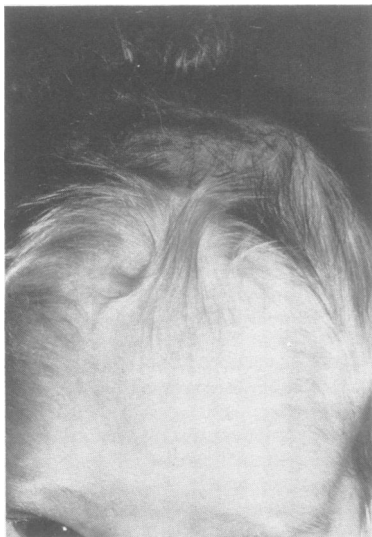


FIG 3 *Frontal upsweep of the hair. The same boy as shown in fig 1.*

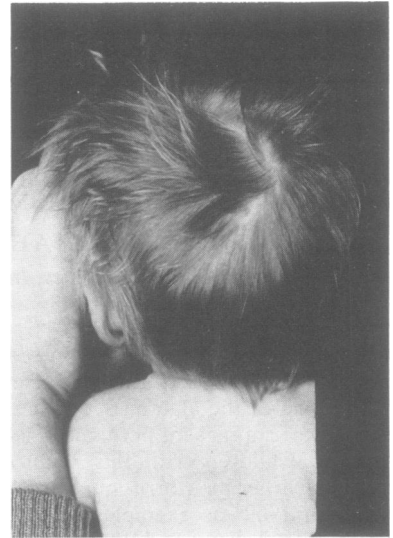


FIG 4 *A small area of alopecia in the occipital region. This child had an area of aplasia cutis congenita.*

characteristically in the midline and in the occipital region. They heal to form atrophic scars.

MALABSORPTION

An exocrine pancreatic defect is a constant feature of this condition. Townes³ and Townes and White⁴ described the abnormalities of pancreatic function. They reported an absence of trypsin, chymotrypsin, and their proenzymes, as well as carboxypeptidase and lipase, but they thought the amylase activity was normal. This was subsequently found to be a spurious result as isoenzyme studies showed the amylase was from the salivary gland. When the contribution from saliva is excluded, pancreatic amylase activity is absent. At necropsy the parenchyma of the pancreatic gland is replaced by fatty tissue.^{5 6} There are fewer islets of Langerhans but clinically there are no reports of impaired glucose tolerance.

The severe malabsorption caused by these enzyme deficiencies leads to hypoproteinaemia, oedema, anaemia, and failure to thrive. The treatment of the pancreatic failure is by pancreatic enzyme replacement, as in cystic fibrosis. It is a life threatening condition and several of the children reported have died despite full medical treatment.

SHORT STATURE

The short stature has been attributed to hypothyroidism and malabsorption. There have been suf-

ficient cases of short children with normal thyroid function^{4 6 7} to know that hypothyroidism is not the cause. A poor nutritional state contributes to the short stature and the child will not grow well unless the pancreatic enzyme deficiency is treated.

Our patient had pituitary hypothyroidism, but as yet has not had further pituitary function tests. It is interesting to speculate that growth hormone deficiency may be the cause of the short stature in this syndrome. In the two necropsy reports,^{5 6} there is no mention of pituitary gland pathology.

HYPOTHYROIDISM

All three girls in the original report of Johanson and Blizzard¹ were hypothyroid. They stated that the hypothyroidism may be acquired rather than congenital, as one of their patients had a normal bone age at birth and her thyroid function was not as depressed as in the older patients. Subsequently six out of the 22 reported cases have been found to have reduced thyroid function. The results may be difficult to interpret because in severely malnourished children there will be depression of the thyroid binding globulin. The additional patient with the Johanson-Blizzard syndrome we present here had normal thyroid function, including a TRH test at the age of eight weeks. By the age of six months he had a low T4 (29 nmol/l) and low TSH (1.5 mU/l) indicating pituitary hypothyroidism.

The true aetiology of the hypothyroidism has not been determined. Thyroid autoantibodies are not present. At necropsy⁵ the thyroid gland was atrophic with colloid distension in a child known to be hypothyroid, but normal⁶ in a euthyroid child. The growth failure, deafness, and mental retardation have also been considered in terms of the hypothyroidism. However, there are sufficient children with normal thyroid function to know that hypothyroidism is unlikely to be the cause, though it can contribute if allowed to go untreated.

MENTAL RETARDATION

Thirteen out of the 22 children reported have been developmentally delayed. This is an underestimate as infants have died in the neonatal period. The cause is obscure. Daentl *et al*⁵ showed focal migrational defects in the brain at necropsy but this was not confirmed by Moeschler *et al*,⁶ who found the brain to be small but structurally normal. There is also no clear relationship between mental retardation and hypothyroidism. As pointed out by Moeschler and Lubinsky,⁸ the patients of Schussheim *et al*⁹ and Sismansis *et al*⁷ were severely retarded but neither microcephalic nor hypothyroid. The degree of retardation cannot be predicted. The patient of Day and Israel¹⁰ showed mild developmental delay

and that of Townes¹¹ was reported as "relatively normal" at three and a half years, although by 12½ years she needed special education. The brother and sister reported by Moeschler and Lubinsky⁸ were normal at two and a half and two years. Severe retardation was found in the patients of Daentl *et al*,⁵ Baraitser and Hodgson,¹² and Mardini *et al*.¹³

ANORECTAL ANOMALIES

As shown in the table, 11 of the reported children with the Johanson-Blizzard syndrome had anorectal abnormalities. In the majority of cases this was an imperforate anus. These children come to medical attention early and the initial surgical management is the fashioning of a transverse colostomy. It is important that poor weight gain in these infants is not attributed to the surgery but that malabsorption is recognised and treated.

DEAFNESS

Hearing loss has been reported in 12 out of 22 patients. The case of Sismansis *et al*⁷ was investigated in detail. There was a severe sensorineural hearing loss with associated absent vestibular function, but the inner ears were structurally normal on polytomograms. There have been no further reports of more detailed radiological investigations. At necropsy⁶ the temporal bones were not studied.

Our patient has a symmetrical, moderately severe sensorineural hearing loss.

OTHER FEATURES

Additional features listed in the table are abnormalities of dentition, genitourinary anomalies, and cardiac malformations. The dental findings have been well reviewed by Zerres and Holtgrave.¹⁴ The children have delayed eruption of teeth, which are small but normal in shape. The genitourinary anomalies were striking in the three girls originally reported,¹ two of whom had a single urogenital orifice, but other children have not had major structural problems. A congenital heart defect has been reported in only three of the children, two of whom were sibs reported by Helin and Jodal¹⁵ with situs inversus. Minor abnormalities of the lacrimal duct have also been recorded.

DIFFERENTIAL DIAGNOSIS

The diagnosis of the Johanson-Blizzard syndrome is not difficult when all the features are present. Hypoplasia of the alae nasi occurs in the oculodentodigital syndrome,¹⁶ aplasia cutis congenita of the scalp in the Adams-Oliver syndrome,¹⁷ and pancreatic malabsorption in the Shwachman-Diamond syndrome, but these should not prove to be diagnostic problems.

Counselling

There is strong evidence for autosomal recessive inheritance. Affected sibs have been described by Moeschler and Lubinsky,⁸ Day and Israel,¹⁰ Helin and Jodal,¹⁵ and Bresson *et al.*¹⁸ Parental consanguinity has been reported by Schussheim *et al.*,⁹ Sismanis *et al.*,⁷ Mardini *et al.*,¹³ and Bresson *et al.*¹⁸

A more difficult problem in counselling is that of predicting the degree of mental retardation, the presence of severe structural lesions, and the success in treating the pancreatic exocrine defect. There have been no reports of prenatal diagnosis to date. At present one could offer a high resolution ultrasound scan in the hope of detecting the distinctive facial features and any structural abnormalities, such as the cardiac or urogenital lesions.

Prognosis

In the family of Mardini *et al.*,¹³ all three patients died in infancy from complications of malabsorption and failure to thrive. The girl reported by Townes³ and Townes and White⁴ was still alive at the age of 12 years nine months. She had short stature, no permanent teeth, a sigmoidostomy because of an imperforate anus, and she required pancreatic enzyme supplements with her meals. She had mild mental retardation. If the pancreatic malabsorption problems are overcome the child can survive infancy, but is likely to require prolonged medical supervision. Even when given the best medical attention these children may develop severe problems associated with hypoproteinaemia, namely infections and oedema, which can lead to death in childhood.

References

- ¹ Johanson AJ, Blizzard RM. A syndrome of congenital aplasia of the alae nasi, deafness, hypothyroidism, dwarfism, absent permanent teeth and malabsorption. *J Pediatr* 1971;**79**:982-7.
- ² Morris MD, Fisher DA. Trypsinogen deficiency disease. *Am J Dis Child* 1967;**114**:203-8.
- ³ Townes PL. Proteolytic and lipolytic deficiency of the exocrine pancreas. *J Pediatr* 1969;**75**:221-8.
- ⁴ Townes PL, White MR. Identity of two syndromes. Proteolytic, lipolytic, and amyolytic deficiency of the exocrine pancreas and congenital anomalies. *Am J Dis Child* 1981;**135**:248-50.
- ⁵ Daentl DL, Frias JL, Gilbert EF, Opitz JM. The Johanson-Blizzard syndrome. Case report and autopsy findings. *Am J Med Genet* 1979;**3**:129-35.
- ⁶ Moeschler JB, Polak MJ, Jenkins JJ, Amato RSS. The Johanson-Blizzard syndrome: a second report of full autopsy findings. *Am J Med Genet* 1987;**26**:133-8.
- ⁷ Sismanis MD, Polisar IA, Ruffy ML, Lambert JC. Rare congenital syndrome associated with profound hearing loss. *Arch Otolaryngol* 1979;**105**:222-4.
- ⁸ Moeschler JB, Lubinsky MS. Brief clinical report: Johanson-Blizzard syndrome with normal intelligence. *Am J Med Genet* 1985;**22**:69-73.
- ⁹ Schussheim A, Choi SJ, Silverberg M. Exocrine pancreatic insufficiency with congenital anomalies. *J Pediatr* 1976;**89**:782-4.
- ¹⁰ Day DW, Israel JN. Johanson-Blizzard syndrome. *Birth Defects* 1978;**XIV**(6B):275-87.
- ¹¹ Townes PL. Trypsinogen deficiency and other proteolytic deficiency diseases. *Birth Defects* 1972;**VIII**(2):95-101.
- ¹² Baraitser M, Hodgson SV. The Johanson-Blizzard syndrome. *J Med Genet* 1982;**19**:302-3.
- ¹³ Mardini MK, Ghandown I, Sakati NA, Nyham WL. Johanson-Blizzard syndrome in a large inbred kindred with three involved members. *Clin Genet* 1978;**14**:247-50.
- ¹⁴ Zerres K, Holtgrave EA. The Johanson-Blizzard syndrome: report of a new case with special reference to the dentition and review of the literature. *Clin Genet* 1986;**30**:177-83.
- ¹⁵ Helin I, Jodal U. A syndrome of congenital hypoplasia of the alae nasi, situs inversus, and severe hypoproteinaemia in two siblings. *J Pediatr* 1981;**99**:932-4.
- ¹⁶ Gorlin RJ, Meskin LH, St Geme JW. Oculodentodigital dysplasia. *J Pediatr* 1963;**63**:69-75.
- ¹⁷ Adams FH, Oliver CP. Hereditary deformities in man due to arrested development. *J Hered* 1945;**36**:3-7.
- ¹⁸ Bresson JL, Schmitz J, Saudubray JM, Lesec G, Hummel JA, Rey J. Le syndrome de Johanson-Blizzard. Une autre cause de lipomatose pancréatique. *Arch Fr Pediatr* 1980;**37**:21-4.

Correspondence and requests for reprints to Dr Jane A Hurst, Department of Clinical Genetics, Institute of Child Health, 30 Guilford Street, London WC1N 1EH.