

Deletion (12)(q15q21.2)

The infant who is the subject of this report is, to our knowledge, the second reported case with a deletion, interstitial or terminal, of the long arm of chromosome 12. The patient was a three and a half month old white female. She was the product of an uncomplicated term pregnancy and normal spontaneous vaginal delivery to a 32 year old, G2P1, healthy mother and a 40 year old healthy father. Birth weight was 3300 g. Paternal history was significant for a child with Potter's syndrome from an earlier marriage.

After going home at three days without problems she developed a unilateral breast abscess aged three weeks and required admission to hospital. Weight gain was slow in her first few weeks, reflecting an initial poor suck, but thereafter was satisfactory.

At 14 weeks the proband (fig 1) was 61.5 cm (50th centile) in length, 5.19 kg (10th to 25th centile) in weight, and the head circumference was 39.5 cm (10th centile).

Received for publication 26 September 1988.
Accepted for publication 25 October 1988.

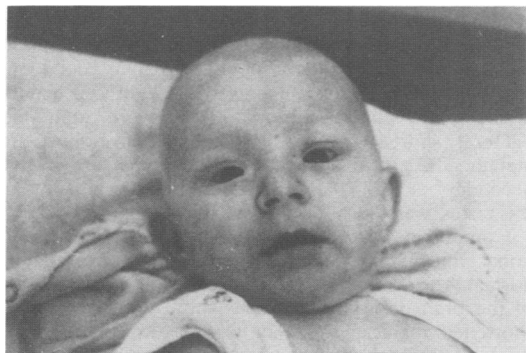


FIG 1 The proband with *del(12)(q15q21.2)*.

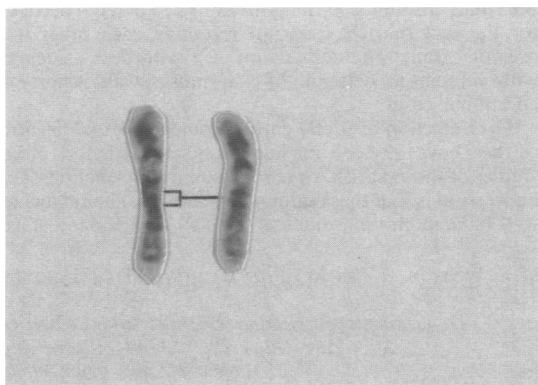


FIG 2 GTG banded chromosomes 12. The normal 12 is on the left and the deleted 12 on the right.

Physical examination was remarkable for a broad forehead with frontal bossing, a flattened occiput, small sunken eyes, a mildly beaked nose, low set ears, a thin upper lip with a normal philtrum, and a high arched palate. The head and eyelash hair was sparse and fine. There was a syndactyly of the second and third toes of the left foot. The skin was pale with mild cutis marmorata. Examinations of chest, heart, abdomen, and genitalia, as well as neurological examination, were unremarkable. Her development was delayed with behaviour estimated to be in the six to seven month range when she was 11 months old. At 14 months she was able to stand while holding on and her only speech was "da-da". At that age her length was 76 cm (25th to 50th centile), weight 8.59 kg (10th centile), and head circumference 44.5 cm (10th centile).

Although apparent at the 500 band stage, studies of elongated chromosomes were necessary to delineate the abnormality. These showed a deletion in the long arm of a chromosome 12 resulting in the loss of band q21.1 and a portion of the contiguous bands q15 and q21.2 (fig 2). Parental chromosomes were normal.

TABLE Features in two patients with deletion of 12q.

Meinecke and Meinecke ¹	This report
46,XY,del(12)(pter→q13.3::q21.1→qter)	46,XX,del(12)(pter→q15::q21.2→qter)
Hypertelorism	Forehead broad, frontal bossing
Upward slanting palpebral fissures	Occiput flat
Cleft lip/palate, bilateral	Palate, high arched
Macrostomia	Thin upper lip
Retrognathia	Beaked nose
Auricles, deep set, dorsally rotated	Low set ears
Fingers 2 and 5 overriding, bilateral rockerbottom feet	Syndactyly, toes 2 and 3, left foot
Short big toes, bilateral	Skin: cutis marmorata
?Cardiac defects (ASD, VSD)	Developmental delay
Developmental delay	
Death at 10 weeks	

Interestingly, the previously reported patient with a different but overlapping deletion of chromosome 12 long arm (q13.3–q21.1) and the subject of this report have only a few features in common (table). The deletion in each includes the portion 12q13.3 to q21.1. It is unclear whether the small difference in the portion of 12q deleted accounts for the fact that they do not resemble each other to a greater extent. The delineation of a syndrome associated with interstitial deletion of 12q must await reports of additional cases.

The detection of subtle chromosome abnormalities such as this show the need for minimum standards for routine studies of those at risk for chromosome abnormalities. Our impression is that these minimum standards should include well banded chromosomes of the 450 to 550 band stage.

M S WATSON, L McALLISTER-BARTON, M J MAHONEY,
AND W R BREG
*Departments of Human Genetics and Pediatrics,
Yale University School of Medicine,
New Haven, Connecticut,
USA.*

Reference

- ¹ Meinecke P, Meinecke R. Multiple malformation syndrome including cleft lip and palate and cardiac abnormalities due to an interstitial deletion of chromosome 12q. *J Med Genet* 1987; 24:187.

Correspondence to Dr M S Watson, Department of Pediatrics, Washington University School of Medicine, 400 South Kingshighway Boulevard, St Louis, Missouri 63110, USA.

A third case of de novo partial trisomy 4p

More than 30 cases of partial trisomy 4p have been described.¹ The majority of these cases were the result of a parental translocation and only two cases had parents with normal karyotypes.

The proband was born spontaneously at term after a pregnancy complicated by mild toxemia. Paternal age was 32 years and maternal age 29 years. Birth weight was less than 2500 g. Failure to thrive was mentioned in the early medical records, but generally physical health has been good. His height developed along the 25th centile. At 16 years of age he started to grow excessively with a final height, at the age of 21, of 201 cm. Psychomotor development has always been slow and speech never developed.

At the age of 23 years the proband was examined by one of us (JWEO). He was a tall, restless, mentally deficient man with an occipitofrontal circumference of

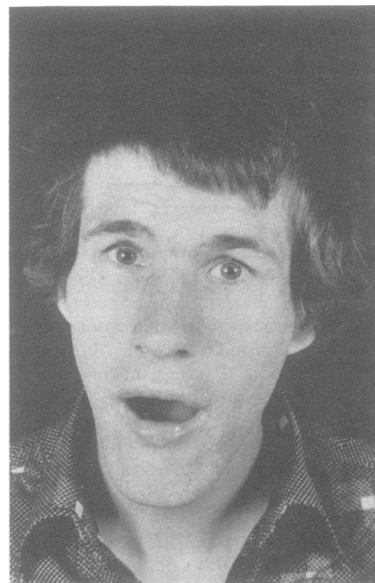


FIG 1 The facial features of the proband at 21 years of age.

53 cm (<–2 SD). His face (fig 1) was elongated and rather narrow with a prominent glabella, heavy eyebrows with synophrys, a mild mongoloid slant, midfacial hypoplasia, bulbous nose, mild macrostomia, high palate, and a long, receding chin. The ears showed a slightly prominent antihelix and attached earlobes. There were cubiti valgi, bilateral short third to fifth metacarpals, short first metatarsals, and a short fourth metatarsal on the left. Secondary sexual characteristics were normal, although the testes were rather small in size.

Examination by an endocrinologist provided no additional information; ophthalmological examination was normal. The EEG showed diffuse abnormalities, especially of the brain stem. Radiographs showed a normal skull, shortened metacarpals, and hypoplastic first ribs. The degree of mental deficiency was considered to be moderate, but was difficult to assess because of behavioural problems.

Cytogenetic analysis was performed on peripheral blood lymphocytes, using GTG and RBA banding techniques. Fourteen cells from the proband were examined and showed 46 chromosomes in all cells with a partial duplication of chromosome 4: 46,XY,dup(4)(p12→p15.2) (fig 2). The parental karyotypes were normal.

Apart from the excessive height the phenotypic abnormalities of the proband are consistent with trisomy 4p, as reviewed by Gonzalez *et al.*¹ Only two cases of de novo interstitial trisomy 4p have been reported. In a third case,² a chromosome 1 was also involved and therefore, in the strictest sense, this was not isolated trisomy 4p.

We thank J M N Hoovers, Cytogeneticist, for his advice,