

Familial translocation t(9;16)

CHRISTINE DOWMAN, DAVID LOCKWOOD, AND JUDITH ALLANSON
Southwest Biomedical Research Institute, 6401 East Thomas Road, Scottsdale, Arizona 85251, USA.

SUMMARY We report a female with a deletion of 9p and concomitant duplication of 16q [46,XX,-9,+der(9),t(9;16)(p24;q13)]. Parental chromosome analysis showed a balanced maternal translocation [46,XX,t(9;16)(p24;q13)]. Three other cases of translocations involving chromosomes 9 and 16 have been reported, one of them with identical breakpoints. A review of published reports of deletion 9p and duplication 16q is presented, and a comparison is made with previously described cases.

Case report

Our patient is the first child of healthy, non-consanguineous parents. She was born at term after an uncomplicated pregnancy, vaginal delivery, and vertex presentation. Birth weight was 2395 g (3rd centile) and birth length 47.6 cm (3rd centile).

Apgar scores were 6 at one minute and 7 at five minutes. She was noted at birth to have trigonocephaly and dysmorphic facial features. Subsequent evaluation showed synostosis of the metopic suture, dilatation of the third ventricle, atrial septal defect, and ventriculoseptal defect.

On examination at 13 days of age, height, weight, and head circumference lay below the 3rd centile (fig 1). There was marked trigonocephaly with a frontal upsweep to the hair pattern and two posterior hair whorls. There was obvious temporal hirsutism and hemispherical bushy eyebrows. The ears were low set and posteriorly rotated. The nose had a fleshy root and bridge, beaky profile, and upturned tip with anteverted nares. The philtrum was long and poorly grooved. The vermilion borders of the lips were thin. The chin was small. The orbits were shallow with proptosis. Palpebral fissures slanted upwards with mild epicanthic folds. There was profound hypotonia with reduced deep tendon reflexes. Cardiac and cranial reconstructive surgery were performed during the first year of life.

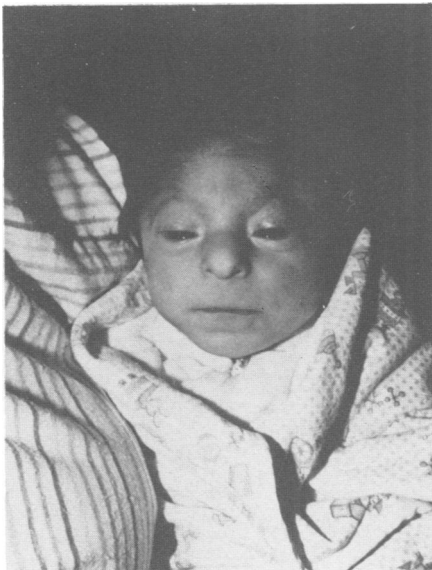

FIG 1 *The proband in the newborn period.*

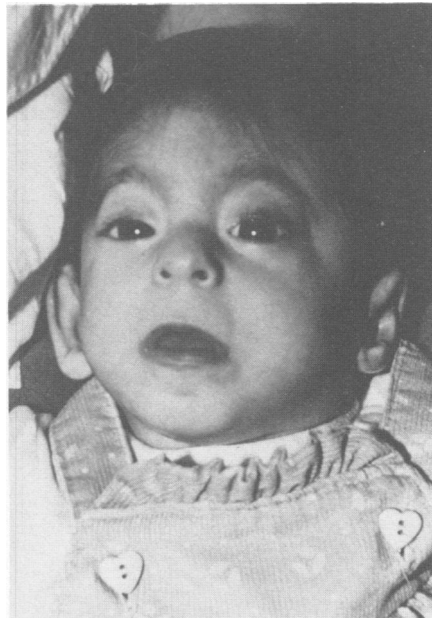


FIG 2 *The proband at two and a half years of age.*

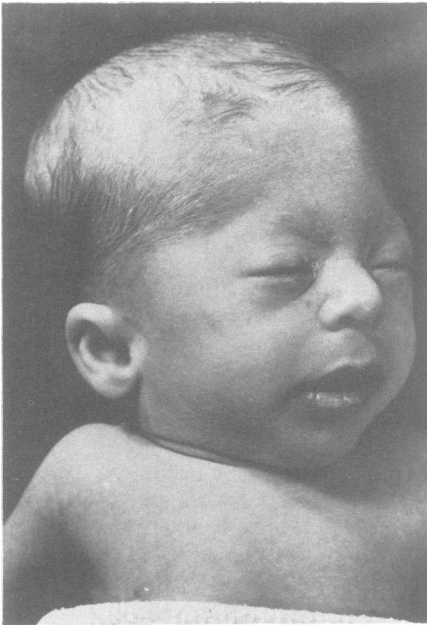


FIG 3 *The proband's maternal uncle.*

On examination at the age of two years seven months, our patient had made considerable developmental progress and was functioning at approximately a 12 month level in all areas except fine motor skills, where functioning was at a 15 month level. Height, weight, and head circumference lay considerably below the 3rd centile. There was obvious brachycephaly (fig 2) with a low anterior hairline and widow's peak patterning and a normal posterior hair line. The eyes were mildly upward slanting with thickened lids and a prominent crease under the eyes, suggesting malar hypoplasia. The orbits were shallow. The eyebrows were semi-circular with mild synophrys. There was exotropia. Inner and outer canthal distances lay between the 3rd and 25th centiles. The ears were borderline low set with normal rotation and prominent antihelix and crus, more obvious on the right than the left. The nose had a prominent root and bridge with a beaky, bulbous tip, small nares, and low hanging columella. The philtrum was long and poorly grooved. The mouth was wide with a thin vermilion border to the lips. The teeth were small and widely spaced. There was micrognathia and a short neck. Examination of the hands showed bilateral fifth

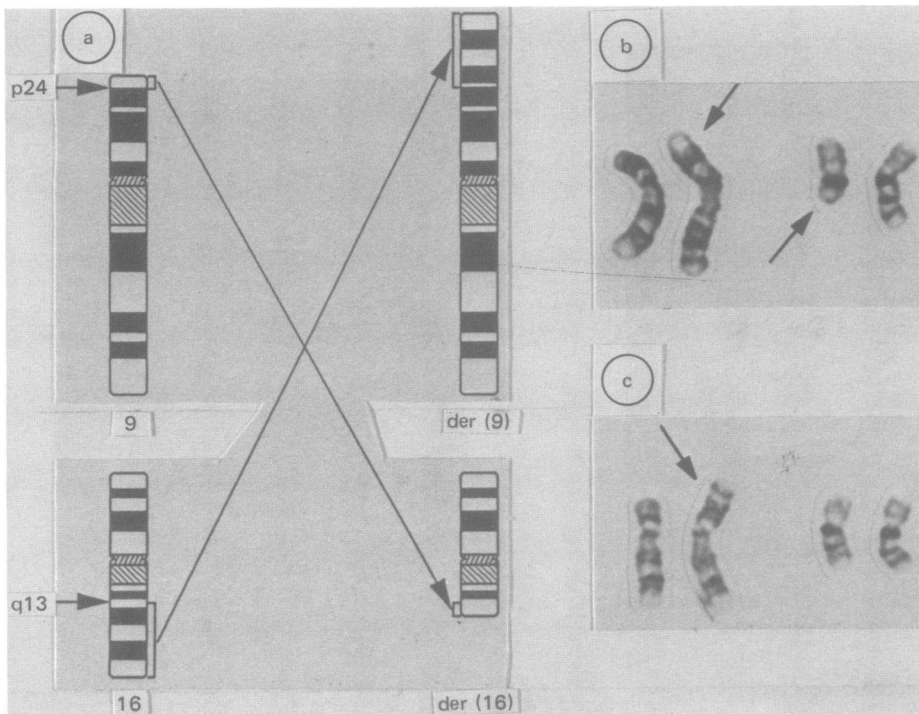


FIG 4
(a) *Ideogram of the translocation.*
(b) *Balanced form: the patient's mother.*
(c) *Unbalanced form: the patient.*

TABLE Clinical features of present case, three previously reported cases, and cases of 9p-

	Present case (9p24-16q13+mat)	Buckton and Barr ⁵ (9p24-16q13+pat)	Alfi et al ¹ (9p22-16q24+mat)	Donnenfeld et al ⁴ (9p21.2-16q23.1+pat)	9p-
Birth weight (centile)	3rd	5th	10th	<3rd	N
Postnatal growth retardation	+		+		+/-
DD/MR	+		+		+
Hypotonia	+			-	-
Trigonocephaly	+	-	+	-	+
Prominent metopic suture	+		+		+
Brachycephaly	-	+	-	-	-
Flat occiput	+	+	+	-	-
Upward slanting palpebral fissures	+	-	+	-	+
Epicanthic folds	+	+	+	+	+
Hypoplastic orbits	+		+	-	+
Hypertelorism	-		+	+	+
Flat nasal bridge	-		+	+	+
Fleshy nasal bridge	+	-	-	-	-
Anteverted nares	-	+	+	+	+
Beaked nose	+		-	-	-
Long philtrum	+	+	+	+	+
Small mandible	+	+	+	+	+
Low set/abnormal ears	+	+	+	+	+
Short, broad neck	+	+	+	+	+
Webbed neck	+	+	-		+/-
CHD	+	+	+	-	+/-
Renal anomalies	+		-	+	-
External genital anomalies	-		+	-	+
Contractures	-	+		+	+
Long fingers	+		+	-	+

finger clinodactyly, underdevelopment of the distal interphalangeal joints, spatulate fingertips, prominent proximal interphalangeal joints, bridged palmar flexion creases, and an excess of whorls on dermatoglyphics. The thumbs were proximally placed with a large pad over the palmar surface of the digit. The nails were small and slightly hyperconvex. Examination of the feet showed pes planus, a puffy dorsum, and a deep crease on the sole between the first and second digits. There was generalised hyperextensibility of the joints with considerable hypotonia and reduced deep tendon reflexes. CT scan was unremarkable. BAER indicated bilateral sensorineural hearing loss. VCUG showed reflux with a trabeculated bladder.

A detailed pedigree indicated a significant maternal family history. A maternal uncle died at four days of age. He is known to have had craniosynostosis with trigonocephaly, frontal upswept hair pattern, upward slanting palpebral fissures with orbital prominence, epicanthic folds, a poorly formed philtrum, and small chin (fig 3). In addition, he had a congenital heart defect, pulmonary and gastrointestinal anomalies, and ambiguous genitalia. There are three more distant maternal relatives who died during infancy with cranial anomalies. In addition, the maternal grandmother had several first trimester miscarriages.

Metaphase chromosomes were prepared at the 375 to 500 band stage. The patient's karyotype showed a 46,XX,-9,+der(9),t(9;16)(p24;q13) chromosome

complement resulting in deletion of the short arm of chromosome 9 from p24→pter and duplication of the long arm of chromosome 16 from q13→qter. Parental studies showed that the derivative chromosome 9 was inherited from the mother, who carries a balanced 9;16 translocation, 46,XX,t(9;16)(p24;q13) (fig 4).

The patient's maternal uncle had the reciprocal rearrangement with a partial deletion of the long arm of chromosome 16 and partial duplication of the short arm of chromosome 9 [46,XY,-16,+der(16),t(9;16)(p24;q13)].

Discussion

Deletion of the short arm of chromosome 9 results in a characteristic clinical phenotype, which since its initial report¹ has been well summarised.² The majority of reported cases involve a deletion of 9p22→pter. Phenotypic characteristics of deletion 9p include mental retardation, trigonocephaly with prominent metopic suture, upward slanting palpebral fissures, hypertelorism, flat nasal bridge, anteverted nares, long philtrum, small chin, short and broad neck, low set ears, widely spaced nipples, cardiac anomaly, and long fingers. Larger deletions with breakpoints at 9p12, 9p13, and 9p21 have been reported with a similar phenotype. Several cases are the result of an unbalanced chromosome rearrangement.

In contrast, duplication of the long arm of chromosome 16 is a rare cytogenetic finding and is

associated with significant neonatal mortality. The majority of reported cases are secondary to parental chromosome rearrangements.³ The phenotype in duplication 16q is difficult to ascertain fully because of the variable concomitant chromosome deletions, although common features include pre- and postnatal growth retardation, failure to thrive, low set, malformed ears, long philtrum, micrognathia, cryptorchidism, and joint contractures.

Three cases have been reported previously with deletion 9p and concomitant duplication 16q secondary to a parental translocation.^{1 4 5} One case⁵ is paternally derived with identical breakpoints to our patient. Two other cases have larger deletions of 9p and smaller duplications of 16q.^{1 4} The table outlines and compares the clinical features in our patient, the three previously reported patients, and the 9p phenotype.

Our patient clearly has many features of the deletion 9p syndrome and resembles the three cases previously described with an unbalanced translocation involving chromosomes 9 and 16. She has done well

with craniofacial surgery and is currently functioning at the 14 to 15 month level.

We wish to thank Debra Hopfensperger for preparation of the manuscript and Fred Flohrschultz III for graphics.

References

- Alfi OS, Donnell GN, Crandall BF, Derencsenyi A, Menon R. Deletion of the short arm of chromosome #9 (46,9p-): a new deletion syndrome. *Ann Genet (Paris)* 1973;16:17-22.
- Huret JL, Leonard C, Forestier G, Rethoré MO, Lejeune J. Eleven new cases of del(9p) and features from 80 cases. *J Med Genet* 1988;25:741-9.
- Garaw A, Crisponi G, Peretti D, Vanni R, Zuffardi O. Trisomy 16q21→qter. *Hum Genet* 1980;53:165-7.
- Donnenfeld AE, McDonald DM, Emanuel BS, Zackai EH. Partial monosomy 9p and partial trisomy 16q in a liveborn female. *Karyogram* 1988;14:12-4.
- Buckton KE, Barr DGD. Partial trisomy for long arm of chromosome 16. *J Med Genet* 1981;18:483.

Correspondence to Dr Judith Allanson, Department of Genetics, Children's Hospital of Eastern Ontario, 401 Smyth Road, Ottawa, Ontario K1H 8L1, Canada.

De novo terminal deletion 7p22.1-pter in a child without craniosynostosis

F SPELEMAN*, M CRAEN†, AND J LEROY†

Departments of Medical Genetics and Paediatrics†, University Hospital Ghent, Belgium.*

SUMMARY A patient with a de novo terminal deletion of the short arm of chromosome 7 (p22.1-pter) is described. Facial dysmorphism, a congenital heart defect, and genital hypoplasia were evident. There were no signs of craniosynostosis. Our observation confirms that deletion of 7p22 is not necessarily associated with craniosynostosis.

More than 20 patients with malformation syndromes resulting from partial deletions of the short arm of chromosome 7 have been reported. Most of the deletions are cytogenetically different. The majority of patients show variable clinical features most of which are common to congenital anomaly syndromes resulting from other types of aneuploidy.^{1 2} Craniosynostosis, however, has so far appeared to be consistently associated with deletion of a segment of band 7p21¹⁻³ and the exact location of the

chromosomal segment critically important for this type of craniosynostosis has been the subject of discussion.¹⁻³

We report on a patient with marked facial dysmorphism, tetralogy of Fallot, and genital hypoplasia but without craniosynostosis, whose karyotype showed a de novo terminal deletion of the short arm of chromosome 7 (7p22.1-pter). To our knowledge, this is only the second patient reported with a pure terminal 7p22 deletion.

Case report

A six year old boy was referred because of severe psychomotor retardation and a congenital heart defect. Weight was 96 kg, length 90.0 cm, and head circumference 44.5 cm (all <3rd centile). He was the second child of healthy, unrelated parents. He was delivered at 38 weeks' gestation with a birth weight of 2300 g, a length of 45 cm, and a head circumference of 32.5 cm. On clinical examination, facial dysmorphism was apparent with an antimongoloid eye slant, epicanthic folds, broad and flat nasal bridge, thin upper lip, triangular shaped