

Emery-Dreifuss syndrome

ALAN E H EMERY

From the Medical School, University of Edinburgh, Teviot Place, Edinburgh EH8 9AG.

SUMMARY Emery-Dreifuss muscular dystrophy is characterised by the triad of (1) early contractures of the elbows, Achilles tendons, and postcervical muscles; (2) slowly progressive muscle wasting and weakness with a humeroperoneal distribution in the early stages; and (3) a cardiomyopathy usually presenting as heart block. The early recognition of the condition is essential because the insertion of a cardiac pacemaker can be life saving. The disorder is usually inherited as an X linked recessive trait (linked to DNA markers around Xq28). However, occasionally it can be inherited as an autosomal dominant trait and there is an indication that this and the X linked form may in some cases have a neurogenic basis. For these reasons it has recently been proposed that the appellation 'Emery-Dreifuss syndrome' be used for this triad of symptoms and signs.

It was nearly a hundred years after Duchenne described the severe form of X linked muscular dystrophy which now bears his name that a clinically similar but milder disease was described by Becker.¹⁻³ However, apart from Becker muscular dystrophy another relatively benign form of X linked muscular dystrophy has also been recognised more recently, the unique features of which were delineated some 20 years ago.⁴ Its distinguishing features, however, may have been noted earlier by Cestan and Lejonne⁵ of the Salpêtrière in 1902, and by Schenk and Mathias⁶ of Breslau in 1920. This disorder was referred to as Emery-Dreifuss muscular dystrophy (EDMD; McKusick 31030) in 1979,⁷ and there have been many reports of the condition since (reviewed in references 8 and 9). However, recent studies indicate that though it is usually myopathic in origin, it may in some cases be neurogenic. Furthermore, though usually X linked, it can occasionally be inherited as an autosomal dominant trait. For these reasons, and because the features of the condition are so distinctive, the appellation Emery-Dreifuss syndrome (EDS) has recently been proposed.¹⁰ The recognition of the condition is important because the timely insertion of a cardiac pacemaker can be life saving.

Clinical features

The disorder (figure) is characterised by the triad of (1) early contractures of the elbows, Achilles tendons, and postcervical muscles; (2) slowly progressive muscle wasting and weakness with a humeroperoneal distribution early in the course of the disease; and (3) a cardiomyopathy usually presenting as heart block.

CONTRACTURES

Muscle contractures are a frequent finding in the later stages of any form of muscular dystrophy or spinal muscular atrophy. However, in this disorder contractures develop *before* there is any significant weakness. These involve the elbows, which result in the arms being carried in a semiflexed position from childhood, the Achilles tendons, so that the patient walks on his toes, and the postcervical muscles, resulting in limitation of neck flexion. Later, forward flexion of the entire spine becomes limited.

MUSCLE WASTING AND WEAKNESS

Muscle wasting and weakness predominantly affects the biceps, triceps, anterior tibial, and peroneal muscles early in the course of the disease. Thus, the weakness is more proximal in the upper limbs and distal in the lower limbs. Later, weakness of the pectoral girdle musculature and the knee and hip

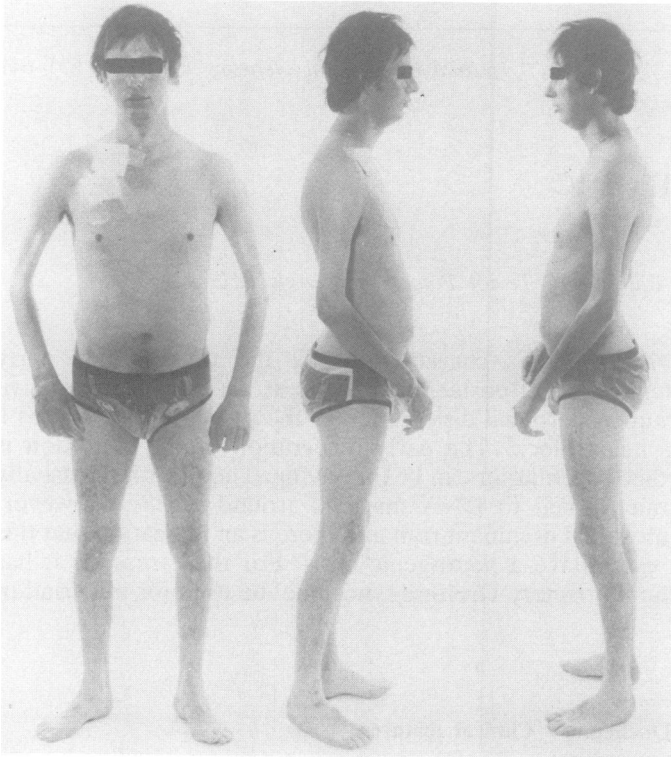


FIGURE A 17 year old boy with EDMD. Note the flexion contractures of the elbows and the wasting of the lower legs. A cardiac pacemaker has been inserted. (From Emery AEH.⁹ *Duchenne muscular dystrophy*. Oxford: Oxford University Press, 1988, with permission.)

extensor muscles develops. The distribution of muscle weakness may therefore be described as humeroperoneal at the beginning and as scapulo-humeropelvoperoneal later. The serum level of creatine kinase is usually moderately raised, but even in the early stages never approaches the grossly raised levels which occur in Duchenne and Becker muscular dystrophies.

Though frank muscle weakness seems to be uncommon in female carriers of X linked EDMD, there have been reports of affected females with no family history of the disorder,^{11 12} as well as of an affected mother and daughter.¹³

CARDIOMYOPATHY

This usually presents as a cardiac conduction defect clinically manifest by sinus bradycardia and prolongation of the PR interval on ECG. Drowsiness and syncope attacks can occur and, later, frank heart block is a frequent cause of death. Detailed studies¹² have shown that cardiac involvement consists of four independent, though often combined, features: (1) impairment of impulse generating cells; (2) conduction defects with atrial preponderance; (3) increased atrial and ventricular heterotopia; and

(4) functional impairment of the ventricular myocardium. Cardiac involvement usually becomes evident as muscle weakness progresses, though exceptionally it may occur before significant weakness is apparent.¹² Provided that the diagnosis is made sufficiently early, the insertion of a cardiac pacemaker can be life saving.^{7 14-18} Cardiac conduction defects of varying degree have also been reported in some otherwise healthy female carriers of X linked EDMD.^{8 15 16 19}

Prognosis

The disorder is relatively slowly progressive and provided that a cardiomyopathy does not intervene, most affected subjects may be expected to survive into at least middle age with varying degrees of incapacity. There does not appear to be any significant intellectual defect.

Genetics

The majority of cases described so far have been inherited as an X linked recessive trait. The responsible gene is linked to colour blindness,²⁰ and to

DNA markers located around Xq27→qter.²¹⁻²⁴ The sum of lod scores from published data so far for linkage between EDMD and the *DXS15* locus exceeds 6 at $\theta=0.10$. Linkage studies so far give no evidence of genetic heterogeneity.²⁵ A proportion of female carriers have slightly raised serum CK levels and this information may be used in conjunction with linked DNA markers for carrier detection.

There have been several reports of families in which EDMD is clearly inherited as an autosomal dominant trait (reviewed in references 8 and 9). Clinically the X linked and autosomal forms are very similar in the distribution of muscle weakness and in the association with early contractures of the elbows, Achilles tendons, and postcervical muscles, and a cardiomyopathy. It has been suggested, however, that the autosomal form may be more variable in its age at onset and degree of severity.²⁶

Differential diagnosis

An X linked disorder similar to EDMD has been described recently (Bergia type), but differs in that early contractures are *not* a feature and all three affected subjects were markedly mentally retarded.²⁷ An autosomal dominant disorder similar to EDMD has been described, but differs in that cardiac conduction defects are *not* a feature.²⁸ A scapulo-peroneal syndrome also exists which can be myopathic²⁹ and has been confused with EDMD, but in fact is a distinct disorder differing in several important respects, namely, in the former, in contrast to EDMD, onset is usually much later (in adult life), *early* contractures do *not* occur, and cardiac conduction defects are *not* a consistent feature. Furthermore, whereas EDMD can be X linked or autosomal dominant and usually myopathic and rarely neurogenic,¹⁰ scapulo-peroneal syndrome is autosomal dominant and not X linked, is usually neurogenic, and only occasionally myopathic.

Features which may be used to differentiate between EDMD and some other similar disorders are summarised in tables 1 and 2.

Finally, the so called rigid spine syndrome has some similarities with EDMD because of the occurrence of joint contractures and limitation of spinal flexion. However, in the rigid spine syndrome, which is probably not a single disease entity,³² these features predominate and any muscle weakness is of secondary importance. Furthermore, cardiac conduction defects are *not* a feature of the rigid spine syndrome.³³

Pathogenesis

The protein dystrophin, found to be absent from muscle in Duchenne muscular dystrophy and abnormal in Becker muscular dystrophy, appears to be normal in EDMD.^{34 35} To date the vast majority of cases of EDMD have been assumed to be myopathic in origin on the basis of electromyography (EMG) and muscle histology. This is supported by the fact that a careful neuropathological necropsy study of a 50 year old affected male showed no abnormality of the spinal cord, and the ventral spinal roots were

TABLE 2 Differentiation between ED and scapulo-peroneal syndromes.

	ED syndrome	Scapulo-peroneal syndrome
Genetics		
X linked	++	
Autosomal dominant	+	++
Clinical		
Onset	Early childhood	Adulthood
Contractures	Early	Late
Cardiac conduction defects	+	-
Basis		
Myopathic	++	+
Neurogenic	+	++

TABLE 1 Differential diagnosis of Emery-Dreifuss muscular dystrophy (EDMD).

Inheritance	Type	Onset (usual)	Predominant weakness (early on)	Early contractures	Mental handicap	Cardiac conduction defects	Reference
X linked	EDMD	Early childhood	Humeroperoneal	+	-	+	-
	Duchenne	Early childhood	Proximal	-	+/-	-*	-
	Becker	Early adulthood	Proximal	-	?	-	-
	Mabry	Early adolescence	Proximal	-	-	-*	30
	Bergia	Early childhood	Humeroperoneal	-	++	-*	27
Autosomal	EDMD	Early childhood	Humeroperoneal	+	-	+	31
	Bailey	Early childhood	Humeropelvo-peroneal	+	-	-	28
	'Scapulo-peroneal'	Adulthood	Scapulo-peroneal	-	-	-	29

*Cardiomyopathy occurs but conduction defects are not a predominant feature

found to be intact.³⁶ There was also no evidence of anterior horn cell loss in a case of the autosomal dominant form of the disorder.³⁷ However, there is little doubt that in some reported cases there has been disagreement as to the interpretation of muscle biopsy and EMG findings.^{7 10} Furthermore, in a 15 year old affected boy who came to necropsy, various muscles showed both neurogenic and myopathic changes and examination of the spinal cord showed a significant decrease in the number of anterior horn cells.³⁸ Another family has been described¹⁰ with the autosomal dominant form of EDMD in which both the electromyographic and muscle histological findings were interpreted as indicating a neurogenic basis for the disease. In view of these various findings it has been suggested that the term Emery-Dreifuss syndrome should be used for the disorder characterised by early contractures, humero-peroneal muscle weakness, and a cardiomyopathy, and then classified as either myopathic or neurogenic in origin, and inherited as an X linked recessive or an autosomal dominant trait.¹⁰

References

- Becker PE, Kiener F. Eine neue X-chromosomale Muskeldystrophie. *Arch Psychiatr Z Neurol* 1955;193:427-48.
- Becker PE. Neue Ergebnisse der Genetik der Muskeldystrophien. *Acta Genet Med Gemellol (Roma)* 1957;7:303-10.
- Becker PE. Two new families of benign sex-linked recessive muscular dystrophy. *Rev Can Biol Exp* 1962;21:551-66.
- Emery AEH, Dreifuss FE. Unusual type of benign X-linked muscular dystrophy. *J Neurol Neurosurg Psychiatry* 1966;29:338-42.
- Cestan R, Lejonne. Une myopathie avec rétractions familiales. *Nouvelle Iconographie Salpêtrière* 1902;15:38-52.
- Schenk P, Mathias E. Zur Kasuistik der Dystrophia musculorum progressiva retrahens. *Klin Wochenschr* 1920;57:557-8.
- Rowland LP, Fetell M, Olarte M, Hays A, Singh N, Wanat FE. Emery-Dreifuss muscular dystrophy. *Ann Neurol* 1979;5:111-7.
- Emery AEH. X-linked muscular dystrophy with early contractures and cardiomyopathy (Emery-Dreifuss type). *Clin Genet* 1987;32:360-7.
- Emery AEH. *Duchenne muscular dystrophy*. Revised reprint. Oxford: Oxford University Press, 1988.
- Witt N, Garner CG, Pongratz D, Baur X. Autosomal dominant Emery-Dreifuss syndrome: evidence of a neurogenic variant of the disease. *Eur Arch Psychiatr Neurol Sci* 1988;237:230-6.
- Takamoto K, Hirose K, Uono M, Nonaka I. A genetic variant of Emery-Dreifuss disease: muscular dystrophy with humero-pelvic distribution, early joint contracture, and permanent atrial paralysis. *Arch Neurol* 1984;41:1292-3.
- Voit T, Krogmann O, Lenard HG, et al. Emery-Dreifuss muscular dystrophy: disease spectrum and differential diagnosis. *Neuropediatrics* 1988;19:62-71.
- Galassi G, Modena MG, Benassi A, et al. Autosomal dominant dystrophy with humero-peroneal weakness and cardiopathy: a genetic variant of Emery-Dreifuss disease? *Ital J Neurol Sci* 1986;7:125-32.
- Hassan Z, Fastabend CP, Mohanty PK, Isaacs ER. Atrioventricular block and supraventricular arrhythmias with X-linked muscular dystrophy. *Circulation* 1979;60:1365-9.
- Hopkins LC, Jackson JA, Elsas LJ. Emery-Dreifuss humero-peroneal muscular dystrophy: an X-linked myopathy with unusual contractures and bradycardia. *Ann Neurol* 1981;10:230-7.
- Dickey RP, Ziter FA, Smith RA. Emery-Dreifuss muscular dystrophy. *J Pediatr* 1984;104:555-9.
- Merlini L, Granata C, Dominici P, Bonfiglioli S. Emery-Dreifuss muscular dystrophy: report of five cases in a family and review of the literature. *Muscle Nerve* 1986;9:481-5.
- Oswald A, Goldblatt J, Horak A, Beighton P. Lethal cardiac conduction defects in Emery-Dreifuss muscular dystrophy. *S Afr Med J* 1987;72:567-70.
- Mawatari S, Katayama K. Scapulo-peroneal muscular atrophy with cardiopathy. An X-linked recessive trait. *Arch Neurol* 1973;28:55-9.
- Thomas PK, Calne DB, Elliott CF. X-linked scapulo-peroneal syndrome. *J Neurol Neurosurg Psychiatry* 1972;35:208-15.
- Hodgson SV, Boswinkel E, Cole C, et al. A linkage study of Emery-Dreifuss muscular dystrophy. *Hum Genet* 1986;74:409-16.
- Thomas NST, Williams H, Elsas LJ, Hopkins LC, Sarfarazi M, Harper PS. Localisation of the gene for Emery-Dreifuss muscular dystrophy to the distal long arm of the X chromosome. *J Med Genet* 1986;23:596-8.
- Yates JRW, Affara NA, Jamieson DM, et al. Emery-Dreifuss muscular dystrophy: localisation to Xq27.3→qter confirmed by linkage to the factor VIII gene. *J Med Genet* 1986;23:587-90.
- Romeo G, Roncuzzi L, Sangiorgi S, et al. Mapping of the Emery-Dreifuss gene through reconstruction of crossover points in two Italian pedigrees. *Hum Genet* 1988;80:59-62.
- Goldblatt J, Schram LJ, Wallis G, Oswald A, Beighton P. Emery-Dreifuss syndrome and X-linked muscular dystrophy with contractures: evidence for homogeneity. *Clin Genet* 1989;35:1-4.
- Becker PE. Dominant autosomal muscular dystrophy with early contractures and cardiomyopathy (Hauptmann-Thannhauser). *Hum Genet* 1986;74:184.
- Bergia B, Sybers HD, Butler IJ. Familial lethal cardiomyopathy with mental retardation and scapulo-peroneal muscular dystrophy. *J Neurol Neurosurg Psychiatry* 1986;49:1423-6.
- Bailey RO, Dentinger MP, Toms ME, Hans MB. Benign muscular dystrophy with contractures: a new syndrome? *Acta Neurol Scand* 1986;73:439-43.
- Thomas PK, Schott GD, Morgan-Hughes JA. Adult onset scapulo-peroneal myopathy. *J Neurol Neurosurg Psychiatry* 1975;38:1008-15.
- Mabry CC, Roeckel IE, Munich RL, Robertson D. X-linked pseudohypertrophic muscular dystrophy with a late onset and slow progression. *N Engl J Med* 1965;273:1062-70.
- Serratrice G, Pouget J. Maladie d'Emery-Dreifuss ou syndrome d'amyotrophie avec rétractions précoces et troubles secondaires de la conduction cardiaque d'hérédité variable. *Rev Neurol (Paris)* 1986;142:766-70.
- Poewe W, Willeit H, Sluga E, Mayr U. The rigid spine syndrome—a myopathy of uncertain nosological position. *J Neurol Neurosurg Psychiatry* 1985;48:887-93.
- Goto I, Ishimoto S, Yamada T, Hara H, Kuroiwa Y. The rigid spine syndrome and Emery-Dreifuss muscular dystrophy. *Clin Neurol Neurosurg* 1986;88:293-8.
- Arahata K, Ishiura S, Ishiguro T, et al. Immunostaining of skeletal and cardiac muscle surface membrane with antibody against Duchenne muscular dystrophy peptide. *Nature* 1988;333:861-3.
- Hoffman EP, Fischbeck KH, Brown RH, et al. Characterization of dystrophin in muscle-biopsy specimens from patients with Duchenne's or Becker's muscular dystrophy. *N Engl J Med* 1988;318:1363-8.
- Hara H, Nagara H, Mawatari S, Kondo A, Sato H. Emery-Dreifuss muscular dystrophy—an autopsy case. *J Neurol Sci* 1987;79:23-31.

³⁷ Chakrabarti A, Pearce JMS. Scapulo-peroneal syndrome with cardiomyopathy: report of a family with autosomal dominant inheritance and unusual features. *J Neurol Neurosurg Psychiatry* 1981;**44**:1146-52.

³⁸ Kudo H, Yano S, Saito K, Yanagisawa M, Kamoshita S. Spinal cord involvement in Emery-Dreifuss muscular atrophy

(X-linked recessive scapulo-peroneal muscular atrophy). *Brain Dev (Japan)* 1982;**14**:363-9.

Correspondence to Professor A E H Emery, Medical School, University of Edinburgh, Teviot Place, Edinburgh EH8 9AG.