

References

- ¹ Young ID, Simpson K. Unknown syndrome: abnormal facies, congenital heart defects, hypothyroidism, and severe retardation. *J Med Genet* 1987;24:715-6.
- ² Fryns JP, Moerman P. Unknown syndrome: abnormal facies, hypothyroidism, and severe retardation: a second patient. *J Med Genet* 1988;25:498-9.

Correspondence to Dr D P Cavalcanti, Departamento de Genética Médica, FCM, UNICAMP, CP 6111, 13081 Campinas, SP, Brazil.

Unknown syndrome: microcephaly, hypoplastic nose, exophthalmos, gum hyperplasia, cleft palate, low set ears, and osteosclerosis

SUMMARY We report a neonate, born at term, with microcephaly, a hypoplastic nose, exophthalmos, gum hyperplasia, cleft palate, and low set ears, who died at 86 minutes of age. Radiographs showed diffuse sclerosis of the bones.

Received for publication 10 April 1989.
Accepted for publication 23 May 1989.

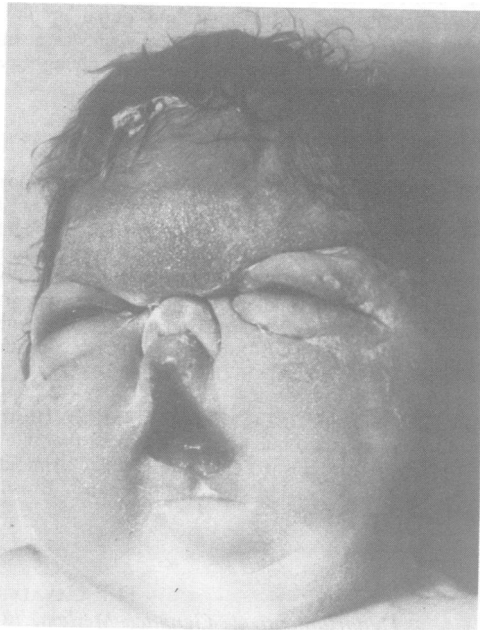

FIG 1 AP view of face.

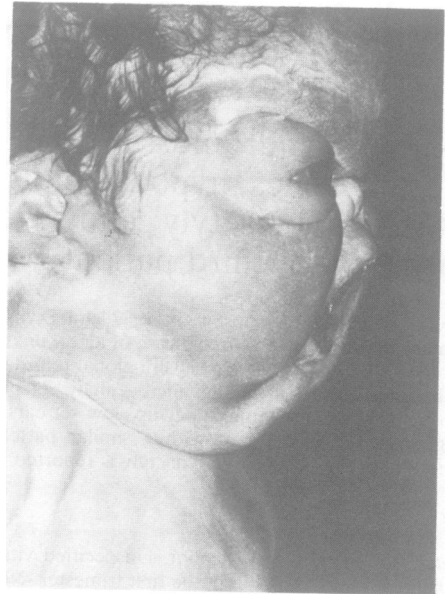


FIG 2 Lateral view of face.

History

Prenatal. No infections or drugs in pregnancy.

Birth. Cephalic delivery at term. Female infant. Weight 2730 g (10th centile), length 44.5 cm (<3rd centile), and occipitofrontal circumference 30 cm (<3rd centile). Apgar scores 8 at one and five minutes. Noted to be hypotonic.

Family. Healthy, unrelated, Caucasian parents. One healthy daughter. One stillbirth at term after placental abruption: normal baby. One first trimester miscarriage. No family history of congenital abnormalities.

Clinical examination (figs 1, 2, and 3)

Microcephaly. Sagittal suture 5 cm wide with large anterior and posterior fontanelles. Ridged coronal sutures. Marked exophthalmos. Maxillary hypoplasia with a sunken nasal bridge and micrognathia. Bowed upper lip. Cleft in soft palate and uvula. Hyperplastic premaxillary and mandibular gums. Low set ears.

Subsequent course

Placed in a cot in the special care baby unit. Respiratory distress developed within 30 minutes of birth, presumably secondary to pulmonary hypoplasia. Because of the multiple severe abnormalities a policy of conservative treatment was adopted. Gasping at 80 minutes at age, she died at 86 minutes of age.

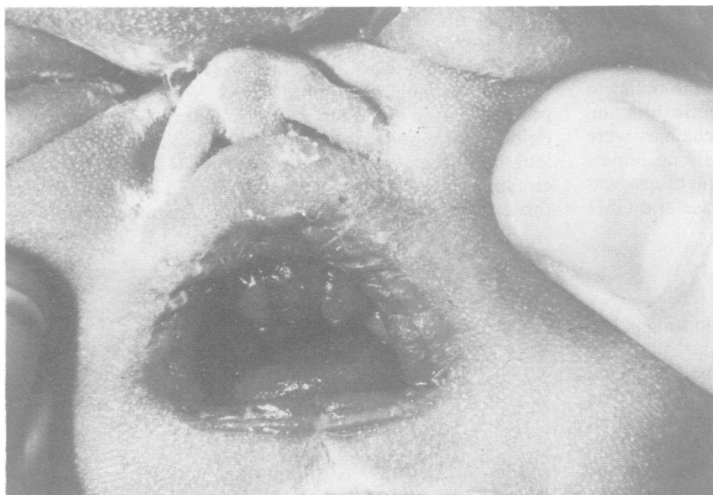

FIG 3 *Close up of mouth.*

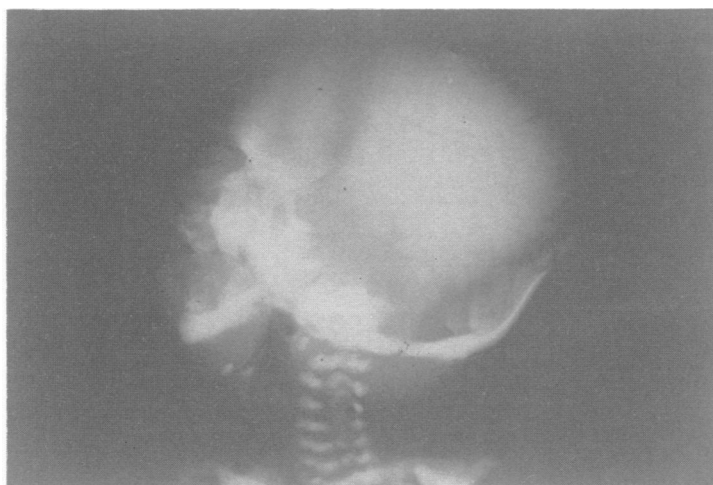


FIG 4 *Lateral skull radiograph.*

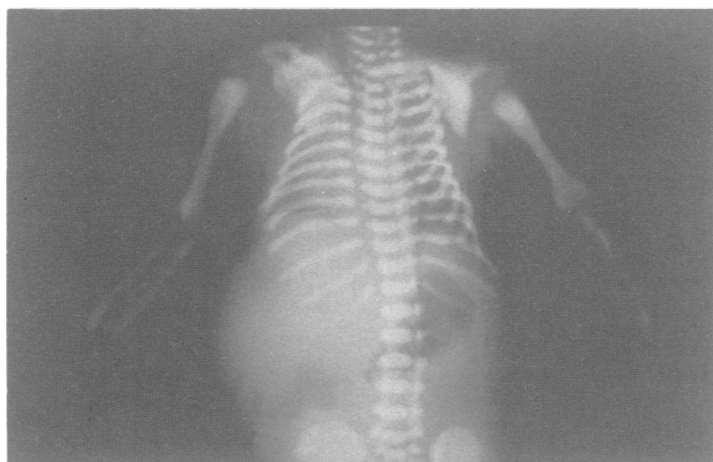


FIG 5 *Radiograph of chest and upper abdomen.*

Investigations

Chromosomes (G banded) showed a normal female karyotype. Radiological examination showed the bones to be generally osteosclerotic with extensive periostitis and metaphyseal flaring (figs 4 and 5). These changes were particularly marked in the skull, pelvis, and long bones. Enzymology on cultured fibroblasts from a skin biopsy was normal and in particular excluded I cell disease and GM1 gangliosidosis.

Necropsy findings

Macroscopic examination showed hypoplastic lungs. The lungs weighed half their joint expected weight of 50 g. The liver and spleen were one and a half times their expected weight, weighing 15.4 g and 11 g respectively. The adrenal glands were hyperplastic; the right and left adrenals weighed 5.8 g and 6.3 g respectively, which is almost twice their expected weight. The brain was of normal size weighing 310 g. The contours of the brain were distorted by the shape of the skull but fissures and sulci appeared normal. There were no other abnormal findings on macroscopic examination.

Discussion

In spite of a detailed search of published reports we were unable to find any cases such as the one we have described.

We would like to thank Dr V Mitchell and Dr S Gilani for their help regarding the radiological aspects of this case.

J RAINE, R M WINTER, A DAVEY, AND S M TUCKER
*Kennedy Galton Centre,
 Northwick Park Hospital,
 Harrow, Middlesex HA1 3UJ.*

Correspondence to Dr R M Winter, Kennedy Galton Centre, Clinical Research Centre, Northwick Park Hospital, Watford Road, Harrow, Middlesex HA1 3UJ.

Unknown syndrome: pachygyria, joint contractures, and facial abnormalities

SUMMARY A male infant, the offspring of a father-daughter mating, is described. He had a lethal condition consisting of brachycephaly, large fontanelles, a flat face, a small nose with thin nares, hypertelorism, small ears with cystic pinnae, camptodactyly, talipes equinovarus, and hypoplastic lungs and kidneys. The brain was very short in the anterior-posterior diameter with simplified broad convolutions (a form of pachygyria).

Received for publication 21 November 1988.
 Revised version accepted for publication 25 May 1989.

Medical history

This male baby was apparently the offspring of a father-daughter mating. The parents were West Indian and the mother was a 15 year old primipara. Pregnancy and delivery were normal. Birth weight was 3200 g, crown-heel length 49 cm, crown-rump length 34 cm, and head circumference 31.5 cm (<3rd centile). The baby died at three hours of age from respiratory insufficiency.

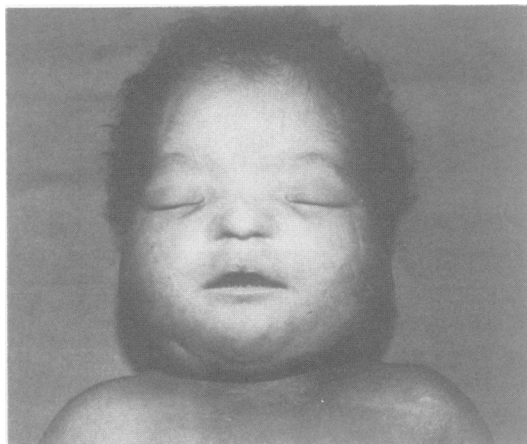


FIG 1 *The face at necropsy.*

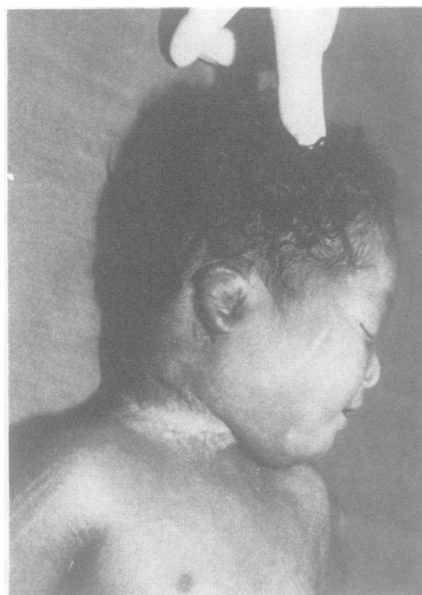

FIG 2 *Lateral view of head at necropsy; note cystic ear pinna.*