

## The “echo-free space” technique: a safe and reliable method for endoscopic ultrasound scope insertion

OPEN  
ACCESS

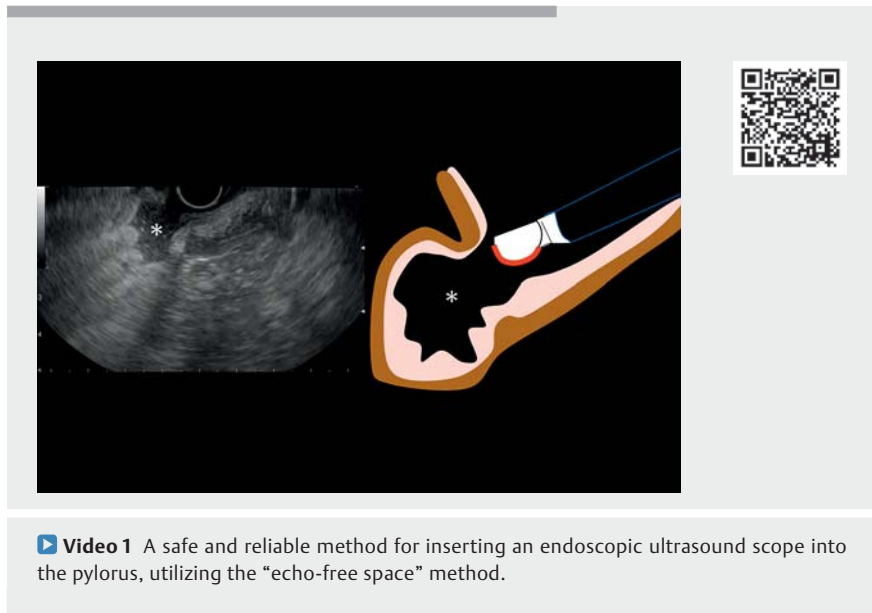
In recent years, the applications of endoscopic ultrasound (EUS) have expanded greatly, not only as an observational tool but also as a treatment procedure such as with EUS-guided fine-needle aspiration (FNA) and EUS-guided drainage [1–4].

Both EUS-FNA and EUS-guided drainage require a linear-type EUS scope, which can be challenging to insert into the pylorus. As the EUS scope is a side-viewing scope, the tip does not face the pylorus, which may result in damage to the stomach wall and lead to unsuccessful insertion into the pylorus if the scope is advanced with reference to the endoscopic image (► **Fig. 1**). For this reason, inserting an EUS scope into the pylorus can be challenging for trainees learning this procedure [5]. Even expert EUS sonographers often experience pyloric insertion difficulties, resulting in repeated insertion attempts and gastric mucosal damage.

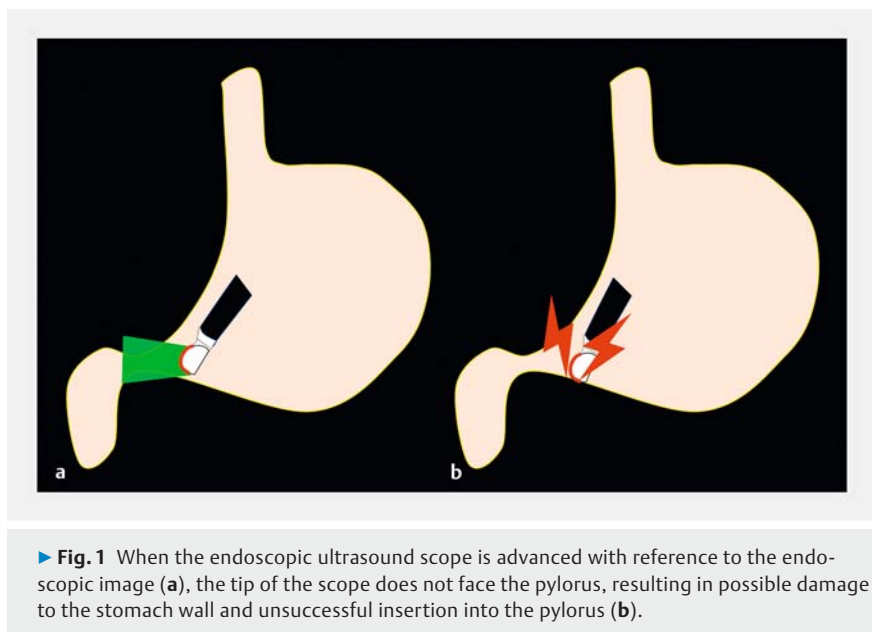
We have therefore developed a safe and reliable method for inserting an EUS scope into the pylorus, which utilizes the “echo-free space” method.

First, advance the EUS scope in front of the pyloric ring and search for the lumen of the duodenal bulb, which is depicted as an “echo-free space” on EUS (► **Fig. 2 a**). Next, search for the site where the continuity of the intestinal wall adjacent to the echo-free space is interrupted (► **Fig. 2 b**). As this break would be the pyloric ring, aligning the tip of the scope with the discontinuity on the EUS screen will lead to successfully inserting the EUS scope into the pylorus (► **Fig. 2 c**, ► **Video 1**).

This method, guided only by the EUS image and not the endoscopic image, is a safe and reliable method for inserting the EUS scope into the duodenal bulb. It can be a useful technique not only for trainees but also for experienced EUS



► **Video 1** A safe and reliable method for inserting an endoscopic ultrasound scope into the pylorus, utilizing the “echo-free space” method.



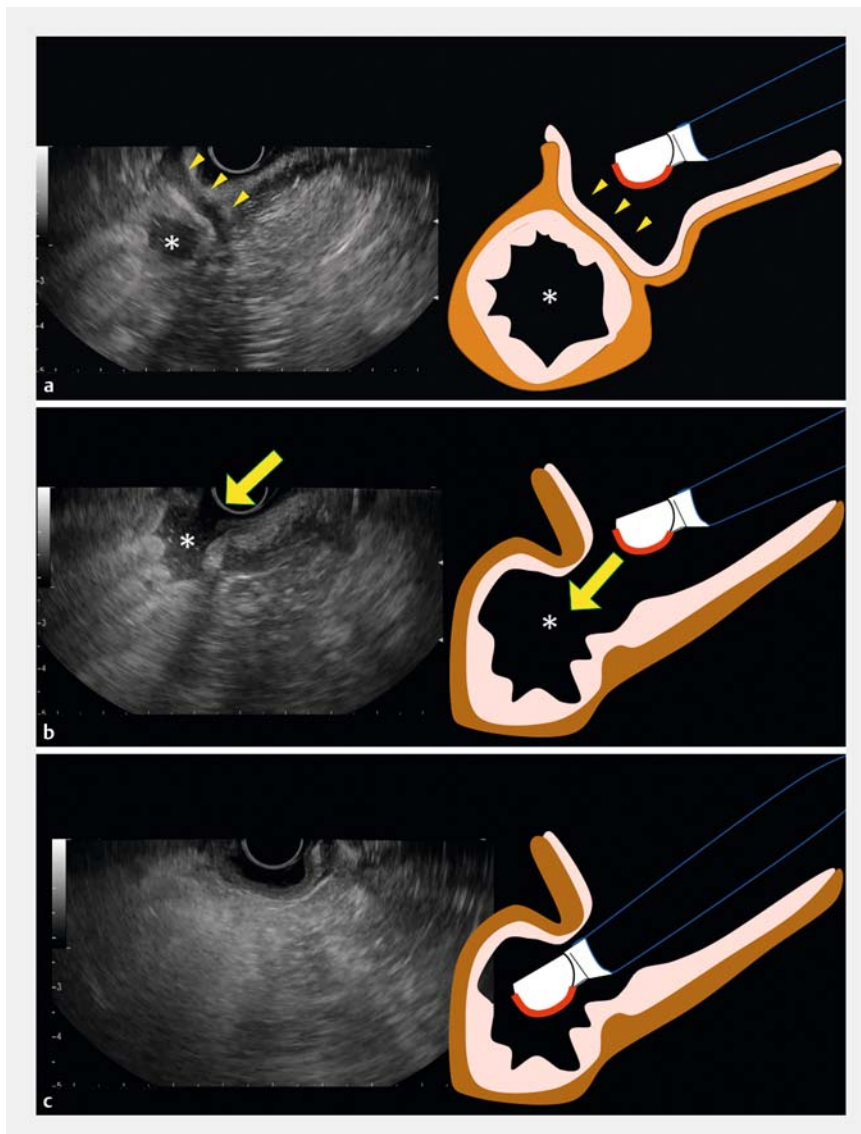
► **Fig. 1** When the endoscopic ultrasound scope is advanced with reference to the endoscopic image (a), the tip of the scope does not face the pylorus, resulting in possible damage to the stomach wall and unsuccessful insertion into the pylorus (b).

sonographers in cases where insertion is difficult.

Endoscopy\_UCTN\_Code\_CCL\_1AF\_2AZ



### Competing interests

The authors declare that they have no conflict of interest.



► **Fig. 2** The “echo-free space” method. **a** First, advance the endoscopic ultrasound (EUS) scope in front of the pyloric ring (arrows) and search for the lumen of the duodenal bulb, which is depicted as an echo-free space (\*) on EUS. **b** Next, search for the site where the continuity of the intestinal wall adjacent to the echo-free space (\*) is interrupted (arrow). This part would be the pyloric ring. **c** Aligning the tip of the scope with the discontinuity on the EUS screen will lead to successful insertion of the EUS scope into the pylorus.

## The authors

Shunsuke Omoto<sup>1</sup>, Mamoru Takenaka<sup>1</sup>   
Tomohiro Fukunaga<sup>1</sup>, Kota Takashima<sup>1</sup>,  
Yoriaki Komeda<sup>1</sup> , Seok Jeong<sup>2</sup>, Masatoshi  
Kudo<sup>1</sup>

- 1 Departments of Gastroenterology and Hepatology, Kindai University Faculty of Medicine, Osaka-Sayama, Japan
- 2 Division of Gastroenterology Department of Internal Medicine, Inha University Hospital, Inha University School of Medicine, Incheon, South Korea

## Corresponding author

**Mamoru Takenaka, MD, PhD**  
Department of Gastroenterology and  
Hepatology, Kindai University Faculty of  
Medicine, 377-2 Ohno-Higashi, Osaka-  
Sayama, 589-8511, Japan  
mamoxyo45@gmail.com

## References

- [1] Takenaka M, Okabe Y, Kudo M. Hemorrhage from metastasis of a 5-mm renal cell carcinoma lesion to the gallbladder detected by contrast-enhanced endoscopic ultrasonography. *Dig Liver Dis* 2019; 51: 743
- [2] Takenaka M, Omoto S, Kudo M. Endoscopic ultrasound fine-needle biopsy may contribute to the diagnosis of malignant lymph nodes. *Clin Endosc* 2020; 53: 508–509
- [3] Tanaka T, Omoto S, Takenaka M. Urgent endoscopic ultrasound-guided choledochoduodenostomy for adenocarcinoma of the ampulla of Vater with scirrhous invasion. *Dig Endosc* 2021; 33: e43–e44
- [4] van der Merwe SW, van Wanrooij RLJ, Bronswijk M et al. Therapeutic endoscopic ultrasound: European Society of Gastrointestinal Endoscopy (ESGE) Guideline. *Endoscopy* 2022; 54: 185–205
- [5] Omoto S, Takenaka M, Maluf-Filho F et al. A novel and effective EUS training program that enables visualization of the learning curve: Educational Program of Kindai system (EPOK). *VideoGIE* 2022; 7: 165–168

## Bibliography

*Endoscopy* 2023; 55: E698–E699  
DOI 10.1055/a-2062-5718  
ISSN 0013-726X  
© 2023. The Author(s).

This is an open access article published by Thieme under the terms of the Creative Commons Attribution License, permitting unrestricted use, distribution, and reproduction so long as the original work is properly cited.

(<https://creativecommons.org/licenses/by/4.0/>)

Georg Thieme Verlag KG, Rüdigerstraße 14,  
70469 Stuttgart, Germany

