

Distal 8p deletion (8p23.1→8pter): a common deletion?

R Hutchinson, M Wilson, L Voullaire

Abstract

The clinical manifestations and cytogenetic details of five patients with a de novo deletion of the short arm of chromosome 8, del(8)(p23), are described. Of the four surviving children all had mild mental retardation and subtle facial anomalies; three of the five had cardiac abnormalities. The clinical features seen in these patients are compared with those of three previous single case reports with del(8)(p23), and with patients described as having the '8p-' syndrome associated with del(8)(p21).

The findings in these patients suggest that major congenital anomalies, especially congenital heart defects, are frequent even in small distal 8p deletions, but facial dysmorphism may be subtle and mental retardation less severe than in those with deletions associated with more proximal breakpoints.

The five patients were detected within a four year period, suggesting that this deletion syndrome is relatively frequent. The possible mechanisms for the formation of terminal deletions are discussed.

An '8p-' syndrome has been described associated with partial deletion of the short arm of chromosome 8, del(8)(p21).¹ The features of this syndrome include mental retardation, post-natal growth retardation, dysmorphic facies, and congenital heart defect. Terminal deletion of a smaller segment of 8p (8p23.1→pter) has recently been reported in three patients with less marked phenotypic abnormalities.²⁻⁴

We describe five further patients with this distal deletion, and compare their clinical features with those previously reported.

Case reports

CASE 1

This 8 year old girl (fig 1) was delivered at term after a normal pregnancy. There were episodes of staring and eye fluttering in the neonatal period suggesting seizures: EEG and cerebral ultrasounds were normal. She sat at 6 months, walked at 15 months, and has persisting fine motor and coordination problems. She rarely vocalised in infancy, produced her first recognisable word after the age of 2 years and at 8 years had limited speech abilities but could conduct simple conversations. She had a left convergent strabismus associated with hypermetropia which improved with corrective lenses. Pubic hair was noted from the age of 7 years, attributed to premature adrenarache. She is described as affectionate, extremely active and distractable, easily frustrated, and sometimes aggressive.

On examination at the age of 8 years 7 months her OFC was 52 cm (50th centile), height 134.5 cm (90th centile), and weight 43.3 kg (>97th centile). Her face was round, with broad cheeks and a relatively narrow forehead. Her palpebral fissures were slightly upward slanting, her eyelashes were long, and she had prominent eyebrows. Her nasal bridge was high, her nose small, and the upper lip was thin and tented. Her hands were small with tapered, pudgy fingers and her feet were short and broad. Tanner stage 2 pubic hair was present, but there were no other signs of

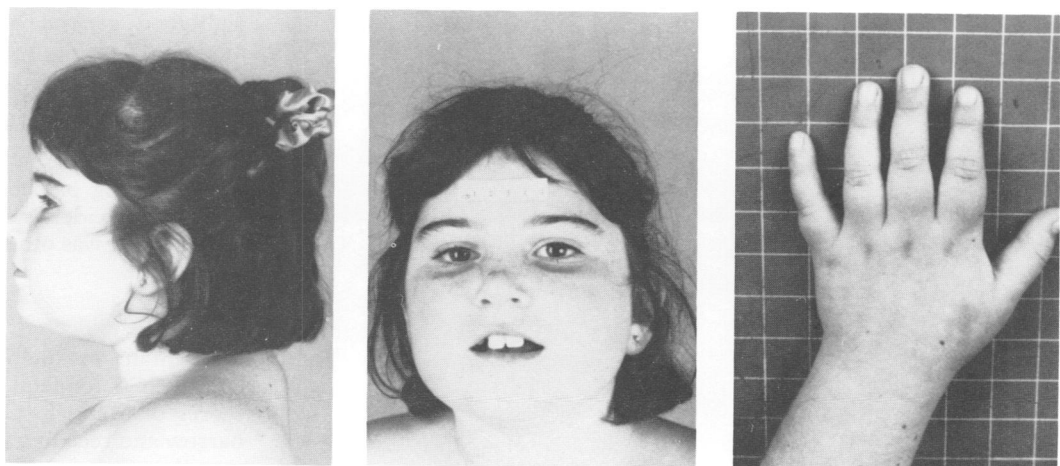

Figure 1 Case 1 at 8 years of age: note broad cheeks, high nasal bridge, and puffy tapering fingers.

Victorian Clinical Genetics Services, Murdoch Institute, Royal Children's Hospital, Flemington Road, Parkville, Victoria 3052, Australia.
R Hutchinson
M Wilson
L Voullaire

Correspondence to Ms Voullaire.

Received 18 June 1991.
Revised version accepted 1 October 1991.

puberty or virilisation. General clinical examination was otherwise normal.

CASE 2

This male child (fig 2) was the second child of healthy parents. Apart from first trimester hyperemesis, the pregnancy and delivery were normal. Fetal ultrasound at 36 weeks had suggested mild dilatation of the cerebral ventricles, but no increase in ventricular size was found on cerebral ultrasound at birth and at 1 month. Episodic vomiting attacks, at intervals of weeks to months, occurred from the age of 2 weeks. These episodes typically lasted two to three days and were associated with frequent vomiting, lethargy, and a dazed appearance. No metabolic abnormalities were detected. Intravenous pyelogram and micturating cystourethrogram, performed after a urinary tract infection at the age of 2 months, were normal. A cerebral CT scan showed partial agenesis of the corpus callosum with dilatation of the temporal and occipital horns of the lateral ventricles and wide separation of the bodies of the lateral ventricles. Cardiac catheterisation, performed at 19 months for investigation of an asymptomatic cardiac murmur, showed mild pulmonary valve stenosis and a small patent foramen ovale. He sat unaided at 8 months, walked at 17 months, and spoke his first words after the age of 2 years.

On examination at the age of 3 years 9 months his weight was 14.4 kg (3rd to 10th centile), height 95.5 cm (10th centile), and OFC 51.2 cm (50th centile). His overall developmental function was equivalent to 2.5 years and his neurological examination was normal apart from a tendency to drool.

Minor facial anomalies noted were dolichocephaly, high and prominent forehead, high nasal bridge, long philtrum, prominent premaxilla, high palate, retrognathia, and posteriorly rotated ears with poor definition of the superior crus of the antihelix. Apart from mild pectus carinatum, pes planus, and a systolic cardiac murmur, general physical examination was normal.

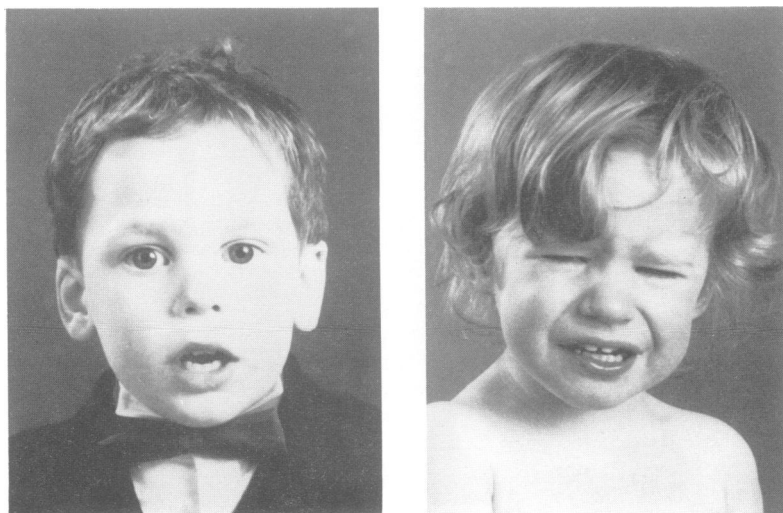

Figure 2 Case 2 at 3 years 9 months and case 4 at 2 years 2 months of age.

CASE 3

This 4 year old girl (fig 3) was born at term of a pregnancy associated with poor maternal weight gain, and her low birth weight was attributed to placental insufficiency. Gavage feeding was required for several days in the neonatal period. At 6 weeks she presented with poor feeding, cyanosis, and congestive cardiac failure. Investigations showed mild ventricular septal defects, Ebstein's anomaly, patent ductus arteriosus, and pulmonary hypertension. She underwent ligation of the PDA and pulmonary artery banding at 7 weeks and further surgery at 12 months. An intravenous pyelogram performed after a urinary tract infection at 10 months showed mild right hydronephrosis (ultrasound at 4 years showed that this had resolved). She required surgical correction of a left convergent strabismus; subsequent visual acuity was normal.

On examination at the age of 4 years, her height was 97 cm (10th centile), weight 15 kg (10th centile), and OFC 45 cm (<3rd centile). She had a broad forehead, laterally upswept eyebrows, high, broad nasal bridge, small anteverted nose, broad cheeks, wide mouth, thin upper lip, and posteriorly angulated ears. Her hands were small with tapered fingers, clinodactyly, and a single right transverse palmar crease. She had pes planus and prominent heels. She had mild to moderate developmental delay, was extremely active, slept poorly, had frequent tantrums, and was described as affectionate but difficult to control.

CASE 4

This boy (fig 2) was the product of a pregnancy associated with mild pre-eclampsia in the third trimester and delivery was by LSCS at term for fetal distress in labour; Apgar scores were 3 and 9. His first feed precipitated a cyanotic episode; oesophageal atresia with tracheo-oesophageal fistula was diagnosed and repaired on day 1. He was observed to have preaxial polydactyly of the left hand, a left undescended testis, and widely separated first and second toes. Chest x ray showed 13 pairs of ribs and extra thoracic vertebrae. Renal ultrasound studies showed horseshoe kidneys and bilateral ureteric reflux. Echocardiogram and cerebral ultrasound were normal. Subsequently, he has had good general health, but has mild to moderate developmental delay.

On examination at the age of 2 years 7 months his height was 86 cm (3rd to 10th centile) and weight 12.8 kg (10th to 25th centile). He had a narrow forehead, narrow downward slanting palpebral fissures, broad nasal bridge, and widely spaced nipples, but general examination was otherwise normal.

CASE 5

This infant was delivered at term by emergency LSCS for fetal bradycardia with Apgar scores of 6 and 8. Clinical features included narrow and receding forehead, prominent premaxilla, micrognathia, low set ears, and single transverse palmar creases.

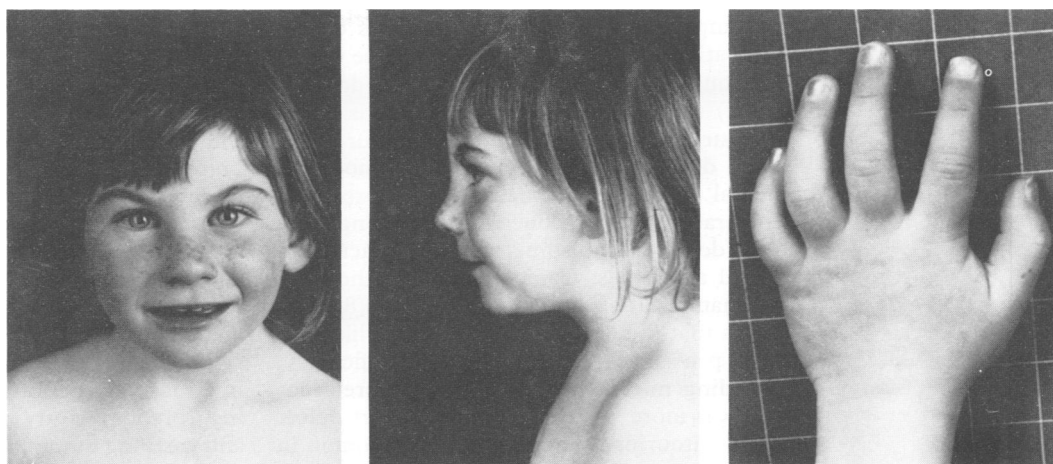
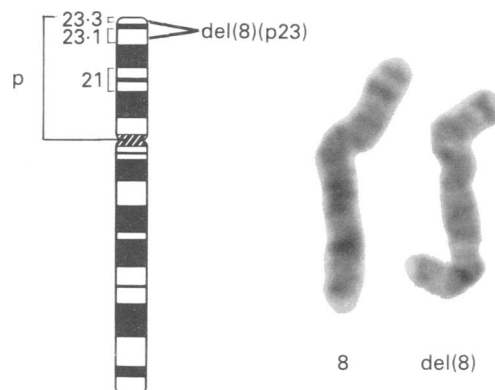
Figure 3 Case 3 at 4 years of age: note broad cheeks, high nasal bridge, small jaw, and puffy fingers.

Central cyanosis developed on day 1, and cardiological investigations showed a complete AV canal, common AV valve, double outlet right ventricle, small left ventricle, and severe pulmonary stenosis. A right subclavian to right pulmonary artery shunt was performed on day 3. Cranial ultrasound showed no cerebral structural abnormality. The infant's clinical course was complicated by cardiac arrhythmias, recurrent right upper lobe collapse/consolidation, necrotising enterocolitis, and multiple episodes of leukemoid reaction and fever, suggesting sepsis. Death occurred at 11 weeks. Necropsy was not performed.



CYTOGENETIC STUDIES

Mitotic cells were obtained from PHA stimulated peripheral blood lymphocytes (permanent cell lines were not established). Metaphase chromosomes were examined after GTL banding at the 550 band level. In each patient deletion of the short arm of one chromosome 8, del(8)(p23), was observed in an otherwise normal karyotype (fig 4). In case 4 the paternal karyotype was normal, but the mother was not studied. In all other cases parental chromosomes were found to be normal.

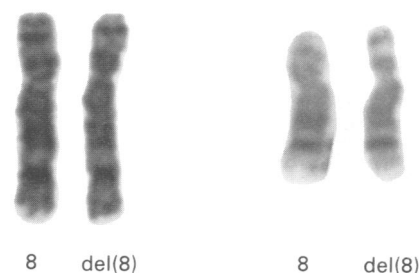
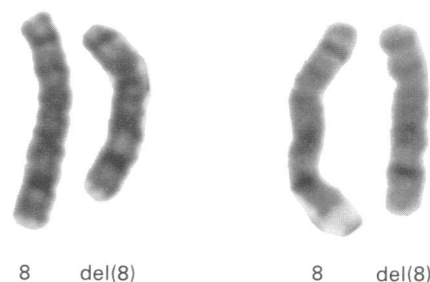


Figure 4 Partial karyotypes of the five patients showing the normal and deleted chromosomes 8 after GTL banding.

Discussion

We have described five patients with partial distal deletion of 8p (8pter→p23.1). Three patients had chromosome analysis at less than 1 year of age because of major anomalies and dysmorphic features. The main indication in the other two cases, ascertained at 2 years 8 months and 7 years 6 months, was developmental delay. Congenital heart defects were present in three of the five patients and a further patient had multiple anomalies including oesophageal atresia with fistula, polydactyly, and costovertebral anomalies. No obvious facial dysmorphism was present except in case 5; all other patients had minor facial anomalies. Although as a group there was no consistent facies, two unrelated subjects (cases 1 and 3) presented a very similar facial appearance, characterised by strabismus, high nasal bridge with broad nasal root, short nose, broad cheeks, small jaw, and low set, posteriorly

rotated ears; both had puffy, tapering fingers. These patients showed a marked resemblance in facial appearance, behavioural characteristics, and degree of developmental delay to the patient with del(8)(p23) reported by Blennow and Brondum-Nielsen.²

Comparison of the clinical features of our five patients with del(8)(p23) and three others previously reported with a similar deletion (table) suggests that although there is not a consistent phenotype, frequent features include developmental delay/mild to moderate mental retardation, behavioural problems (hyperactivity, poor concentration), congenital heart defects, strabismus, and minor facial and digital anomalies. Comparison with the clinical manifestations of patients with del(8)(p21) shows that the latter group was more likely to have pre- and postnatal growth deficiency, including microcephaly, and mental retardation was more severe. Congenital heart defect and genitourinary anomalies were common in both groups. Facial dysmorphism was more pronounced in the del(8)(p21) patients, but was non-specific. Epicanthic folds and broad, flat nasal bridge were reported in the majority with del(8)(p21), but were not seen in our patients; rather, the nasal bridge was high.

It has been suggested that this smaller terminal deletion may not have any major phenotypic effect.³ This is not supported by our findings. Although facial dysmorphism is slight, congenital heart defects, genitourinary abnormalities, and other major malformations have been described in over half of the reported patients. Variation in breakpoint within band 8p23 might be responsible for the observed variability in clinical presentation in patients with a cytogenetically similar deletion.

The deletion seen in these patients is detectable at the 400 band level (ISCN) but when routine chromosome diagnosis is undertaken using trypsin banded chromosomes the deletion involves partial loss of a light terminal

band and hence it is easily overlooked. Trypsin banding of longer chromosomes giving a 550 band pattern shows the dark band, 8p23.2, within the light band 8p23 and the deletion of this dark band is readily observed. This requirement for routine analysis at the 550 band level may explain why it has only recently been described. Children with cardiac defects and mental retardation who had chromosomal analysis in the past, but not at the 550 band level, may warrant repeat chromosomal investigation.

The five cases presented here were detected in a four year period in a laboratory performing predominantly paediatric cytogenetics and carrying out approximately 1500 chromosomes analyses annually, drawn from a population with an annual birth rate of 60 000. This suggests that the deletion may in fact be relatively common and have an incidence rate comparable to that of the deletion of 5p associated with the cri du chat syndrome.

Following the findings of Muller⁵ and McClintock⁶ that terminal deletions produced by X irradiation or physical breakage were unstable and liable to rejoining, Muller⁵ postulated the presence of telomeres to explain the special properties of the ends of chromosomes that gave them stability and suggested that stable terminal deletions were in fact interstitial and resulted from two breaks. It has followed that the stable de novo terminal deletions seen in the clinical situation are assumed to result from a two break rearrangement with the second break occurring close to the telomere. However, certain terminal deletions, for example of 5p, 4p, 18p, 18q, and now apparently also 8p, occur more frequently as de novo deletions than as unbalanced translocations,

Clinical manifestations in patients with distal 8p deletions.

	Fryns <i>et al</i> ³	Blennow and Brondum- Nielsen ²	Pecile <i>et al</i> ⁴	Case 1	Case 2	Case 3	Case 4	Case 5	Total	Dobyns <i>et al</i> ¹ (10 patients)
	del(8)(p23)	del(8)(p23)	del(8)(p23)	del(8)(p23)	del(8)(p23)	del(8)(p23)	del(8)(p23)	del(8)(p23)		del(8)(p21)
Mat age, pat age	24, 24	28, 30	39, 31	27, 27	25, 37	25, 27	32, 32	33, 34		
Birth weight (g)	3150	3430	2680	4300	3000	2230	2660	3160	3/8*	9/10*
Mental retardation	+	+	+	+	+	+	+	+	8/8	10/10
Hyperactivity/ behaviour problems	+	+	-	+	-	+	+	-	5/8	...
Postnatal growth deficiency	-	-	-	-	-	-	+	N/A	1/7	6/10
Microcephaly	-	-	+	-	-	+	-	-	2/8	7/10
High, narrow forehead	-	+	...	+	-	-	+	+	4/7	7/10
Epicanthic folds	-	-	-	-	-	-	-	-	0/8	8/10
Upward slanting palpebral fissures	-	+	-	-	-	+	-	-	2/8	...
Strabismus	-	+	-	+	-	+	-	-	3/8	...
High nasal bridge	...	+	-	+	+	+	+	-	5/7	...
Wide, flat nasal bridge	-	-	+	-	-	-	-	-	1/8	6/10
Short nose	-	-	+	+	-	+	-	-	3/8	5/10
Broad cheeks	-	+	+	+	-	+	+	-	5/8	...
Thin upper lip	-	-	+	+	-	+	+	-	4/8	...
Retrognathia/small jaw	+	+	+	+	+	+	+	+	8/8	5/10
Low set/post angulated/ malformed ears	+	-	+	+	-	+	+	+	6/8	6/10
Puffy hands/feet	...	-	+	+	-	+	+	-	4/7	2/10
Pes planus	...	-	...	-	+	+	+	-	3/6	...
Broad chest/wide set nipples	+	-	+	+	+	+	+	-	6/8	3/10
Congenital heart defect	-	-	+	-	+	+	-	+	4/8	7/10
Genitourinary anomalies	+	-	-	-	+	+	+	-	4/8	5/10
Other malformations	-	-	Diaphragmatic hernia	Premature adrenarache	Agnesis corpus callosum	-	TOF, polydactyly, skeletal abn	-	4/8	...

* No with low birth weight

which suggests that they may not be the result of random breakage and exchange involving two breaks.

Terminal deletions could occur by a recombinational mechanism involving uneven crossing over between sister chromatids, or intrachromosomally, by looping out of the interstitial region. Such recombinational errors might be facilitated by repeat sequences near the telomere and within the chromosome. Such mechanisms have been proposed to explain interstitial deletion of 15q11.2 associated with the Prader-Willi syndrome and the presence of direct and inverted repeated DNA sequences have been shown in the region 15q11-13.⁷

Alternatively, stable terminal deletions might be formed following a single break if healing occurs to add a telomere. Molecular analysis of a patient with a truncated chromosome 16 has shown that healing of a terminally deleted chromosome can occur.⁸ This might involve the action of telomerase or occur by recombinational replication mechanisms where repeats from the telomere of one chromosome are copied to that of another.⁹ Recent evidence¹⁰ suggests that telomerase may operate in the germ cells to add telomeres to the ends of chromosomes. Thus, it is possible that a terminal deletion occurring at a particular stage in the development of a germ cell could

be healed by the action of telomerase. This healing might be dependent upon the site of the initial break, as specific sequences might be needed in the proximity of the break to permit the addition of telomeric sequences by telomerase.⁸

- 1 Dobyns WB, Dewald GW, Carlson RO, Mair DD, Michels VV. Deficiency of chromosome 8p21.1→8pter: case report and review of the literature. *Am J Med Genet* 1985;22:125-34.
- 2 Blennow E, Brondum-Nielsen K. Partial monosomy 8p with minimal dysmorphic signs. *J Med Genet* 1990; 27:327-9.
- 3 Fryns JP, Kleczkowska A, Vogels A, Van Den Berghe H. Normal phenotype and slight mental retardation in de novo distal 8p deletion (8pter→8p23.1). *Ann Genet (Paris)* 1989;32:171-3.
- 4 Pecile V, Petroni MG, Fertz MC, Filippi G. Deficiency of distal 8p-: report of two cases and review of the literature. *Clin Genet* 1990;37:271-8.
- 5 Muller HJ. The remaking of chromosomes. In: *Studies in genetics: selected papers of H J Muller*. New York: Bloomington University Press, 1969:384-408.
- 6 McClintock B. The production of homozygous deficient tissues with mutant characteristics by means of the aberrant mitotic behaviour of ring-shaped chromosomes. *Genetics* 1938;23:315-76.
- 7 Donlon TA, Lalonde M, Wyman A, Bruns G, Latt SA. Isolation of molecular probes associated with the chromosome 15 instability in the Prader-Willi syndrome. *Proc Natl Acad Sci USA* 1986;83:4408-12.
- 8 Wilkie AOM, Lamb J, Harris PC, Finney RD, Higgs DR. A truncated chromosome 16 associated with α thalassaemia is stabilized by addition of telomeric repeat (TTAGGG)_n. *Nature* 1990;346:868-71.
- 9 Wang S-S, Zakian VA. Telomere-telomere recombination provides an express pathway for telomere acquisition. *Nature* 1990;345:456-8.
- 10 Hastie ND, Dempster M, Dunlop MG, Thompson AM, Green DK, Allshire RC. Telomere reduction in human colorectal carcinoma and with ageing. *Nature* 1990; 346:866-8.