

# Holoprosencephaly: a family showing dominant inheritance and variable expression

Amanda L Collins, Peter W Lunt, Christine Garrett, Nicholas R Dennis

## Abstract

A family with probable dominant holoprosencephaly is presented with five affected subjects in two sibships, the offspring of healthy sisters who are presumed gene carriers. Of the affected children, three had cecobcephaly and died shortly after birth. One had left choanal atresia, retinal coloboma, a single central maxillary incisor, microcephaly, short stature, and learning problems. Another had only a single central maxillary incisor. The occurrence of hypotelorism, microcephaly, and unilateral cleft lip and palate as minor manifestations of the gene in possible and probable gene carriers is discussed.

(J Med Genet 1993;30:36-40)

Holoprosencephaly results from impaired midline cleavage of the embryonic forebrain<sup>1</sup> leading to incomplete morphogenesis. The midline facial developmental anomalies are variable but usually reflect the severity of the underlying brain malformation, as described by deMyer *et al*<sup>2</sup> and reviewed by Cohen.<sup>3</sup> Holoprosencephaly is most commonly seen as an isolated occurrence in a family or in association with trisomy 13, del(13q), del(18p), or triploidy,<sup>3</sup> while families with both recessive<sup>4-6</sup> and dominant<sup>7-11</sup> inheritance patterns have also been reported. Affected infants with chromosome abnormalities often have additional extracranial abnormalities.

We report a large family where a dominant inheritance pattern with reduced penetrance and variable expression seems most likely and

discuss the minor manifestations in probable and possible gene carriers.

## Case reports

The pedigree is shown in fig 1. The family was ascertained through subject II.2 who sought genetic advice in 1978 when 14 weeks pregnant, prompted by the birth of an abnormal child (III.10) to one of her two sisters; three of the four liveborn offspring of her other sister had already had craniofacial abnormalities. These four cases are now described.

### CASE 1

A female infant (III.6) weighed 2700 g at 38 weeks' gestation. She had a single nostril and both orbits were absent. Her skull transilluminated. Head circumference (OFC) was 31.5 cm (just below the 3rd centile) and crown-heel length was 48 cm (10th to 50th centile). She died at a few hours of age. Necropsy showed vestigial cerebral hemispheres, a probably absent pituitary gland, absent left adrenal gland, and a tiny atrophic right adrenal. Chromosomes were 46,XX.

### CASE 2

A female (III.8) was noted at birth to have a small left eye, left sided choanal atresia, and a small jaw. The choanal atresia required surgical correction. A left retinal coloboma was found subsequently. At 3 months, height, weight, and OFC were all below the 3rd centile. Later a single central upper incisor was noted (fig 2). She started at normal primary school aged 5 years after attending a special preschool group and required speech therapy. She remains small, but growth hormone studies have been normal. At the age of 10½ years she is approximately two years behind her peers in academic achievement. Vision in the left eye is limited to light perception. Her left nostril becomes blocked with upper respiratory tract infections. Her height (118.3 cm) and OFC (45.5 cm) are both well below the 3rd centile. Her chromosomes are 46,XX.

### CASE 3

A third malformed baby (III.9) was born to the same parents. The male infant weighed 2700 g at term and died aged 1 day. Extreme hypotelorism was noted. The right pupil was eccentric and the left globe was small

Wessex Clinical Genetics Service, Princess Anne Hospital, Coxford Road, Southampton SO9 4HA.  
A L Collins  
N R Dennis

Clinical Genetics Unit, Bristol Royal Hospital for Sick Children, St Michael's Hill, Bristol BS2 8BJ.  
P W Lunt

Department of Child Health, Royal Devon and Exeter Hospital, Wonford, Exeter EX2 5DW.  
C Garrett

Correspondence to Dr Collins.

Received 24 October 1991.  
Revised version accepted 3 June 1992.

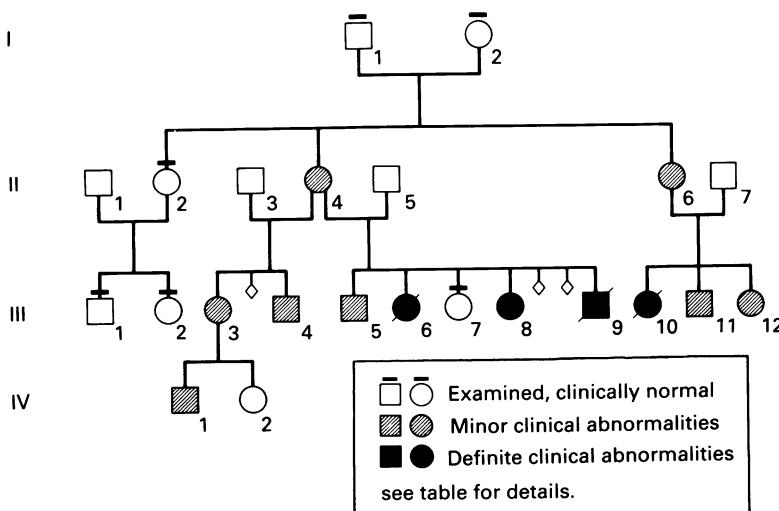


Figure 1 Family pedigree.

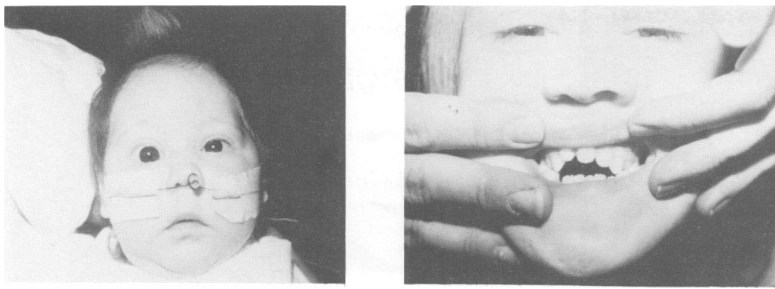


Figure 2 III.8 aged 3 months and 10½ years showing single central upper incisor.

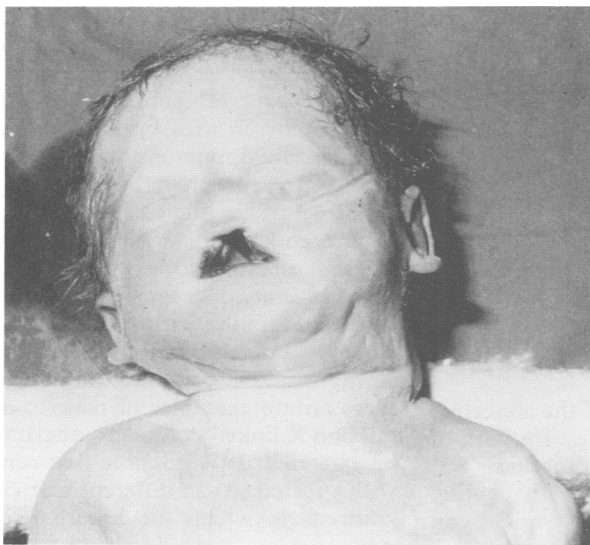

Figure 3 III.9 showing hypotelorism, single nostril, and absent philtrum.

with an opaque cornea. There was a single nostril, a large midline cleft of the upper lip opening into the nasal region, and a wide cleft of the hard and soft palates. The cerebral hemispheres were fused with a single large ventricle. The optic nerves and pituitary were absent; the cerebellum was present but small.



Figure 4 The three sisters II.2, II.4, and II.6. II.4 and II.6 are presumed gene carriers.

The left adrenal gland was rudimentary and the right was absent. His chromosomes were 46,XY.

#### CASE 4

A female infant (III.10) was born to the other sister of the proband. This infant had cebocephaly with hypotelorism, midfacial hypoplasia, and a single nostril. She died at a few hours of age. The cerebral hemispheres were fused and the posterior part of the brain was replaced by a fluid filled cyst. The olfactory bulbs and pituitary were absent and the optic chiasm was abnormal. Chromosomes were 46,XX.

During her pregnancy the proband had detailed ultrasound scans performed which showed no abnormalities and subsequently an apparently normal boy was born at term. A daughter, also apparently normal, was born two years later. The proband has a normal facial appearance and is dissimilar in appearance to her sisters (fig 4); her inner canthal distance (ICD), interpupillary distance (IPD), and outer canthal distance (OCD) all lie between the 25th and 50th centiles. Her OFC is on the 25th centile. She has minor dental anomalies with unerupted upper canines bilaterally; her father (I.1) has a similar anomaly. Her son has eye spacings and OFC on the 50th centile, her daughters' are on the 75th centile or above, and both children have developed normally.

Subject II.4, an obligate gene carrier on the hypothesis of dominant inheritance, has had three spontaneous abortions and four apparently normal children in addition to the three with either holoprosencephaly or facial abnormalities. Her height is on the 3rd centile and eye measurements are on the 3rd to 25th centiles (fig 4). Her OFC is markedly reduced at 48.5 cm (approximately 4 SD below the mean). Her teeth are normal. One apparently normal daughter (III.3) has had a son (IV.1) with unilateral cleft lip and palate, who is otherwise normal. In this daughter, OFC and ICD are both on the 3rd centile, while in her son OFC is below the 3rd centile and ICD is on 3rd to 25th centiles.

The proband's other sister (II.6, fig 4), also a presumed gene carrier, has an OFC of 52 cm (just below the 3rd centile), ICD on the 3rd centile, and IPD and OCD on the 25th centile. Her teeth are normal. Her son (III.11), aged 6 years, is doing well at a normal primary school. His OFC is on the 3rd centile and ICD is below the 3rd centile (fig 5). Her daughter (III.12) has a single central incisor and a smooth border to the upper lip (fig 6). Her OFC is on the 10th centile and ICD on the 3rd to 25th centile. Aged 4 years she is of normal intelligence but required speech therapy for one term. The single central incisor suggests that she is probably a gene carrier.

In generation III, four (III.3, III.4, III.5, and III.11) of the seven otherwise normal cousins have a very similar facial appearance with apparent hypotelorism, slightly prominent eyes, and small heads (fig 5). One of these

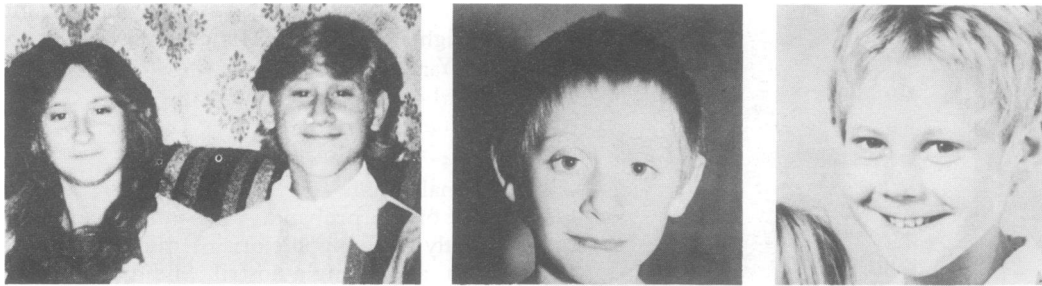

Figure 5 III.3, III.4, III.11, and III.5 showing similar facial appearance.

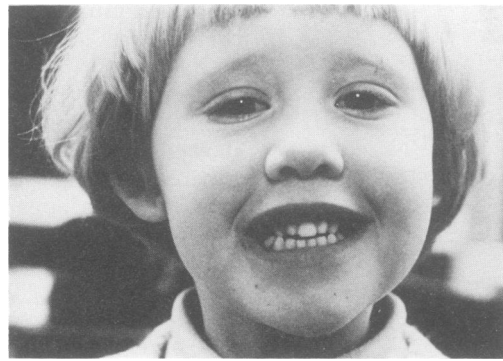

Figure 6 III.12 showing single central upper incisor and smooth border to upper lip.

(III.4) had learning difficulties and attended a special school.

The maternal grandparents of the abnormal children are shown in fig 7. They are both of normal intelligence. The grandmother (I.2) has an OFC greater than the 50th centile. Although the grandfather (I.1) gives an impression of hypotelorism, this is not borne out by eye measurements. His OFC is on the 50th centile. He has non-eruption of the upper canines. His parents are shown in fig 8, his father again giving the impression of hypotelorism. However, the proband feels that her sisters both resemble their mother in facial appearance.



Figure 7 I.1 and I.2, the maternal grandparents of the affected children.

## Discussion

The incidence of severe holoprosencephaly has been estimated in Indiana as 1/16 000 live births<sup>12</sup> and in Avon as 1 in 14 500.<sup>13</sup> Because holoprosencephaly is seen in association with other syndromes (for example Meckel syndrome, trisomy 13) and in the children of diabetic mothers, a single embryological basis seems unlikely. In addition, there have been many reports of familial cases, the earliest being of twins with cyclopia.<sup>14</sup> Burck *et al*<sup>15</sup> also described monozygotic twins concordant for holoprosencephaly but with varying facial abnormalities, while Corsello *et al*<sup>16</sup> described monozygotic twins with identical facial and cerebral malformations. Reports of affected subjects in two or more generations<sup>18,9</sup> may represent families with a dominant inheritance pattern and incomplete penetrance. Our family would also fit into this category, but as there are no examples of male to male transmission X linked dominant inheritance cannot be excluded. It is possible that some families with affected sibs in different branches of large kindreds in which the inheritance has been suggested as autosomal recessive may be further examples of dominant inheritance with non-penetrance in some gene carriers. Affected offspring from consanguineous marriages support recessive inheritance in other families.<sup>15</sup>

For patient III.8 in our family, although the appearance of a single central incisor and the family history are strong indications that she carries the 'holoprosencephaly gene', her features are also consistent with a diagnosis of the CHARGE association, namely choanal atresia, retinal coloboma, postnatal growth deficiency, and mild mental retardation. Her ears are normal. A CT scan of the head has not been performed. The choanal atresia has not been previously recognised in other families as a minor manifestation of the holoprosencephaly gene. As in other families,<sup>17</sup> necropsies on infants III.6 and III.9 showed absent pituitaries and rudimentary adrenal glands, probably secondary to lack of hormonal stimulus in utero. However, III.9 also had eye abnormalities, with absent optic nerves, microphthalmia, and opaque cornea. Optic nerve hypoplasia and secondary hypopituitarism, in association with absence of the septum pellucidum, are the features of the septo-optic dysplasia sequence.<sup>18</sup> The embryological early basis of this sequence is thought also to be incomplete early morphogenesis of anterior midline structures in the developing forebrain, but while the



Figure 8 The parents of I.1. The father gives the impression of hypotelorism.

Summary of findings in affected family members.

Pedigree No	OFC (centile)	ICD (centile)	Schooling	Other features
I.1	> 50	50	Normal	Minor dental anomalies
I.2	50	50	Normal	
II.4	≤ 1	3–25	Normal	
II.6	< 3	3	Normal	
III.3	< 3	3	Normal	Unusual facies (fig 5)
III.4			Special	Unusual facies (fig 5)
III.5			Normal	Unusual facies (fig 5)
III.6	< 3			Cebocephaly
III.8	< 3	3	Special	L choanal atresia, L microphthalmia, L retinal coloboma, single central incisor, short stature
III.9				Cebocephaly
III.10				Cebocephaly Eccentric R pupil, L microphthalmia, L corneal opacity
III.11	3	3	Normal	Unusual facies (fig 5)
III.12	10	3–25	Normal	Single central incisor
IV.1	< 3	3–25	Normal	Cleft lip + palate

holoprosencephaly sequence probably results from abnormal development during the third week of fetal life, the septo-optic dysplasia sequence results from a defect around the sixth week.<sup>19</sup>

Because of the variability of expression of dominant holoprosencephaly, the possibility of this diagnosis is not always considered in families where an apparently sporadic case has occurred. Our family and others similar to it emphasise the importance of microcephaly as a minor manifestation of the gene. In the families described by Ardinger and Bartley<sup>10</sup> and Jaramillo *et al.*,<sup>11</sup> all obligate carriers had microcephaly as did the two carrier sisters in our family. Inner canthal distance (ICD) as a reflection of hypotelorism seems less reliable. In our family, obligate carrier II.4 has a head circumference of  $-4$  SD, yet her ICD is on the 3rd to 25th centile. No member of our family had an ICD below the 3rd centile. The occurrence of a single central incisor has been recognised by other authors as a risk factor for holoprosencephalic offspring.<sup>20–23</sup> Other dental anomalies, such as the unerupted canines present in two members of our family, do not

seem to be a feature in other holoprosencephaly families. One presumed gene carrier with an absent nasal septum has also been described.<sup>24</sup> The significance of unilateral clefting in an otherwise normal child is not clear. In one family with consanguineous parents<sup>25</sup> the proband had four sibs with cleft lip or palate or both. One large dominant family<sup>9</sup> had one member with cleft palate; another large dominant pedigree, family JG,<sup>8</sup> had eight members with cleft lip and palate.

Cohen<sup>3</sup> has estimated from published multi-generation families that the penetrance of the gene for severe holoprosencephaly is approximately 32%, and 26% for minor manifestations of the gene. In our family, assuming that one of the grandparents in generation I is a gene carrier, and excluding IV.1 (with unilateral cleft lip and palate, discussed below), there are 13 first degree relatives of obligate gene carriers, 11 of whom, after allowing for ascertainment bias,<sup>26</sup> would be at 50% risk of inheriting the gene. Of these, two have been severely affected. With inclusion of the obligate carriers this suggests an overall penetrance of 27%, in general agreement with Cohen.<sup>3</sup> However, in noting the small head circumference of the obligate carriers, we suspect that four other members of generation III may also be gene carriers because of their relatively small heads and similar facial appearance (fig 5). Accepting this as evidence of heterozygote status, and also including III.12, a penetrance of or close to 100% should be considered in this family, particularly if one of the grandparents of the affected children could have germline mosaicism rather than be a non-penetrant gene carrier. Thus, we feel it is important to examine the family members carefully with regard to the above features after the birth of a child with apparently sporadic holoprosencephaly. Microcephaly (OFC < 3rd centile) is probably the most reliable minor manifestation, but other features, especially a characteristic face, single central incisor, unilateral cleft lip and palate, and iris or retinal colobomas, may all be significant in such a family. For presumed gene carriers, ultrasound examination in pregnancy is currently the only way to avoid the birth of a severely affected child.

- DeMyer W, Zeman W, Palmer CG. Familial alobar holoprosencephaly (arhinencephaly) with median cleft lip and palate. *Neurology* 1963;13:913–8.
- DeMyer W, Zeman W, Palmer CG. The face predicts the brain: diagnostic significance of median facial anomalies for holoprosencephaly (arhinencephaly). *Pediatrics* 1964;34:256–63.
- Cohen MM. Perspectives on holoprosencephaly. Part 1. Epidemiology, genetics and syndromology. *Teratology* 1989;40:211–35.
- Holmes LB, Driscoll S, Atkins L. Genetic heterogeneity of cebocephaly. *J Med Genet* 1974;11:35–40.
- Khan M, Rozdilsky B, Gerrard JW. Familial holoprosencephaly. *Dev Med Child Neurol* 1970;12:71–6.
- Begleiter ML, Harris DJ. Brief clinical report. Holoprosencephaly and endocrine dysgenesis in brothers. *Am J Med Genet* 1980;7:315–8.
- Burck U, Karsten RH, Kitschke HJ. Occurrence of cyclopia, myelomeningocele, deafness and abducens paralysis in siblings. *Am J Med Genet* 1982;11:443–8.
- Dallaire L, Fraser FC, Wiglesworth FW. Familial holoprosencephaly. *Birth Defects* 1971;7(7):136–42.
- Cantu JM, Fragoso R, Garcia-Cruz D, Sanchez-Corona J. Dominant inheritance of holoprosencephaly. *Birth Defects* 1978;14(6B):215–20.
- Ardinger HH, Bartley JA. Microcephaly in familial holoprosencephaly. *J Craniofac Genet Dev Biol* 1988;8:53–61.

- 11 Jaramillo C, Brandt SK, Jorgensen RJ. Autosomal dominant inheritance of the DeMyer sequence. *J Craniofac Genet Dev Biol* 1988;8:199-204.
- 12 Roach E, DeMyer W, Conneally PM, Palmer C, Merritt AD. Holoprosencephaly: birth data, genetic and demographic analyses of 30 families. *Birth Defects* 1975;11(2):294-313.
- 13 Saunders ES, Shortland D, Dunn PM. What is the incidence of holoprosencephaly? *J Med Genet* 1984;21:21-6.
- 14 Ellis R. On a rare form of twin monstrosity. *Trans Obstet Soc Lond* 1865;7:160-4.
- 15 Burck U, Hayek HW, Zeidler U. Holoprosencephaly in monozygotic twins - clinical and computer tomographic findings. *Am J Med Genet* 1981;9:13-7.
- 16 Corsello G, Buttitta P, Cammarata M, et al. Holoprosencephaly: examples of clinical variability and etiologic heterogeneity. *Am J Med Genet* 1990;37:244-9.
- 17 Hintz RL, Menking M, Sotos JF. Familial holoprosencephaly with endocrine dysgenesis. *J Pediatr* 1968;72:81-7.
- 18 deMorsier G. Median cranioccephalic dysraphias and olfactogenital dysplasia. *World Neurol* 1962;3:485-506.
- 19 Jones JL. *Smith's recognisable patterns of human malformation*. 4th ed. London: Harcourt Brace Jovanovich, 1988.
- 20 Berry SA, Pierpoint ME, Gorlin RJ. Single central incisor in familial holoprosencephaly. *J Pediatr* 1984;104:877-80.
- 21 Hattori H, Momoi M, Kataoka K, Mikawa H, Shiota K. Single central maxillary incisor and holoprosencephaly. *Am J Med Genet* 1987;28:483-7.
- 22 Fryns JP, Van den Berghe H. Single central maxillary incisor and holoprosencephaly. *Am J Med Genet* 1988;30:943-4.
- 23 Johnson VP. Holoprosencephaly: a developmental field defect. *Am J Med Genet* 1989;34:258-64.
- 24 Hennekam RCM, Van Noort G, de la Fuente FA, Norbruis OF. Agenesis of the nasal septal cartilage: another sign in autosomal dominant holoprosencephaly. *Am J Med Genet* 1991;39:121-2.
- 25 Cohen MM, Gorlin RJ. Genetic considerations in a sibship of cyclopia and clefts. *Birth Defects* 1969;5:113-8.
- 26 Lunt PW, Compston DAS, Harper PS. Estimation of age dependent penetrance in facioscapulohumeral muscular dystrophy by minimising ascertainment bias. *J Med Genet* 1989;26:755-60.