

SYNDROME OF THE MONTH

Nager acrofacial dysostosis

Marie T McDonald, Jerome L Gorski

Departments of Pediatrics and Communicable Diseases, University of Michigan Medical Center, Ann Arbor, MI 48109-0688, USA. M T McDonald

Department of Human Genetics, University of Michigan Medical Center, Ann Arbor, MI 48109-0688, USA. J L Gorski

Correspondence to Dr Gorski, Division of Pediatric Genetics, 3570 Medical Science Research Building II, Box 0688, University of Michigan Medical Center, Ann Arbor, MI 48109-0688, USA.

Nager acrofacial dysostosis (NAD) is an inherited disorder of facial, limb, and skeletal morphogenesis. The disorder was recognised as a specific entity by Nager and de Reynier in 1948,¹ but was probably first reported by Slingenberg in 1908.² Here we present a summary of 76 previously reported cases³⁻³⁹ with the addition of two new cases. In some families, NAD is inherited as a pleiotropic autosomal dominant condition with markedly variable penetrance and expressivity. However, the occurrence of affected sibs with normal parents suggests potential genetic heterogeneity and an additional autosomal recessive form.

Clinical features

The main clinical features consist of craniofacial, limb, and musculoskeletal anomalies. Less frequently, other malformations have also been reported. The common clinical features of NAD are summarised in the table.

CRANIOFACIAL

The facial features of NAD are distinctive; cardinal features include downward slanting palpebral fissures, malar hypoplasia, a high nasal bridge, micrognathia, and external ear defects (figs 1 and 2). Extension of scalp hair onto the cheeks, a reduced number of eyelashes, and lower lid colobomas occur less frequently. The most common external ear anomalies include external auditory canal stenosis and low set positioning. Posterior rotation and preauricular skin tags have been observed less frequently.^{10 15 16} Hearing loss is an important feature; it is typically bilateral, conductive, and of the order of 50 to 70 dB. Even in the absence of external ear anomalies, ossicular chain malformations may occur. The predominant oral findings include cleft palate and an absent soft palate. Cleft lip, velopharyngeal insufficiency, and foreshortening of the soft palate occur less frequently. Hypoplasia of the larynx or epiglottis occurs rarely.¹⁷ Temporomandibular joint fibrosis and ankylosis may occur.^{22 38}

LIMB DEFECTS

Limb anomalies are a cardinal sign of NAD and, in combination with the characteristic facial features, are diagnostic. Typical limb abnormalities include preaxial anomalies (hypoplastic or absent thumbs and radii) and proximal radioulnar synostosis (fig 3). Thumb anomalies are usually asymmetrical. Duplicated¹⁸ and triphalangeal thumbs^{6 8 9} may occur. Infrequent hand anomalies include syndactyly, clinodactyly, and camptodactyly. A variety of lower limb anomalies have been reported, including phocomelia,⁹ dislocated hips,^{17 21 22} talipes equinovarus, metatarsus varus,¹¹ and an absent tibia/fibula.^{9 16 19 20} Toe abnormalities include overlapping toes, syndactyly, isolated cases of absent toes,²³ hypoplastic toes,^{22 24} posteriorly placed hypoplastic halluces,¹⁰ hallux valgus,¹⁵ broad hallux,²⁶ dorsal angulation of the second toe,²⁶ and medial deviation of the toes.^{11 21} Limb reduction defects were a prominent feature in seven cases.^{9 10 16 20 25 27}

SKELETAL ANOMALIES

Abnormalities of the axial skeleton have included thoracolumbar scoliosis^{5 28} and cervical vertebral²⁶ and rib anomalies.^{3 17 28}

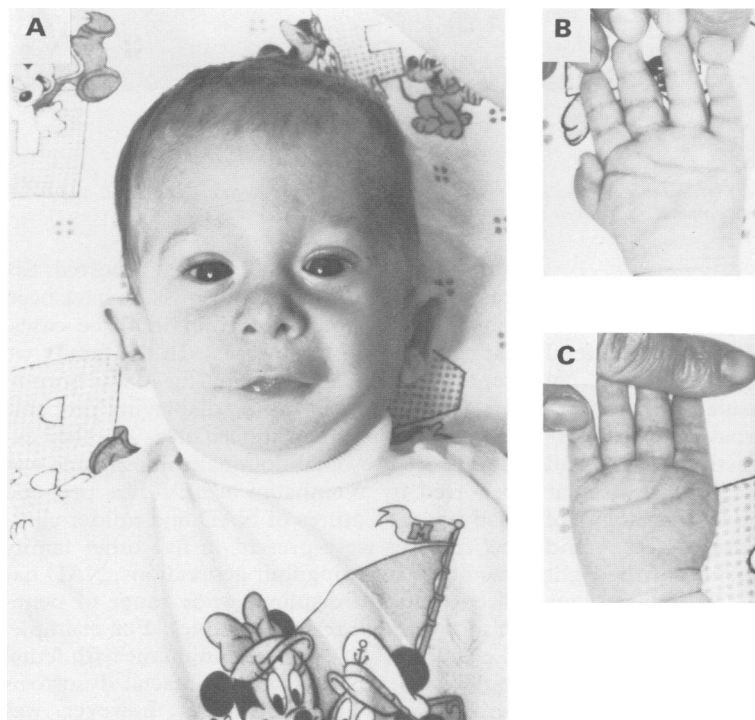


Figure 1 Photographs of proband's face (A) and hands (B,C) at 4 months of age. NAD features include downward slanting palpebral fissures, malar hypoplasia, a high nasal bridge, dysmorphic pinnae, a low set left ear, and micrognathia (A). The left thumb is hypoplastic and fixed in a flexed position (B); the right thumb is absent (C).

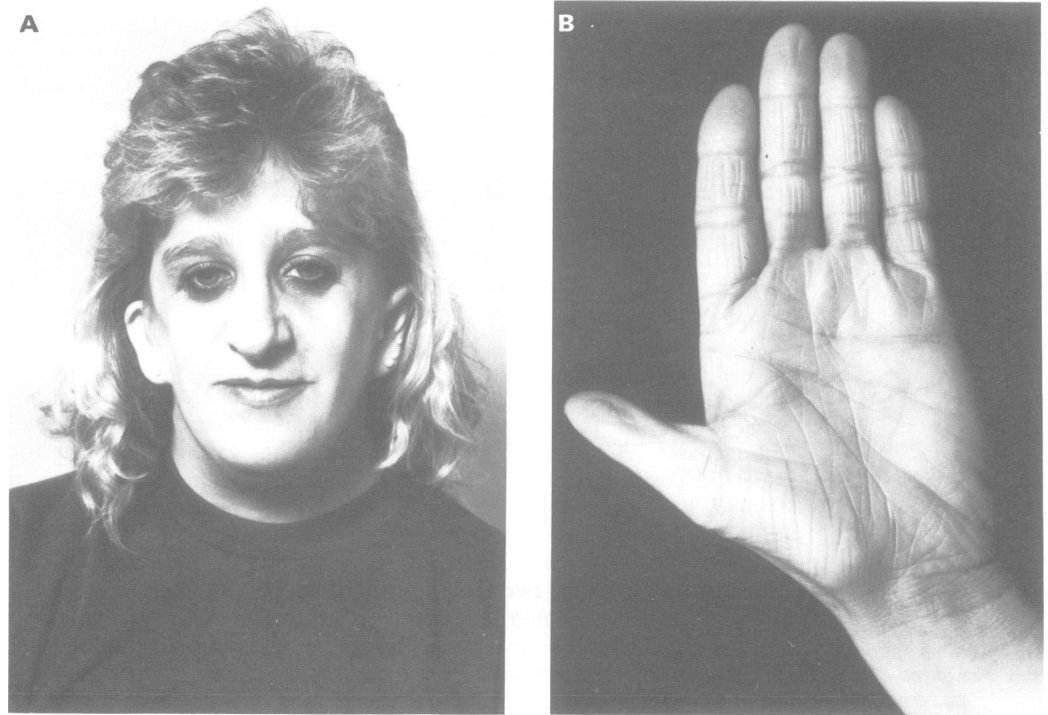

Figure 2 Photographs of the face (A) and left hand (B) of the proband's mother. NAD features include downward slanting palpebral fissures, malar hypoplasia, a high nasal bridge, dysmorphic pinnae, and a low set left ear (A); she had a repaired cleft palate (not shown). The left thumb is hypoplastic and fixed in extension; no flexion creases are present (B).

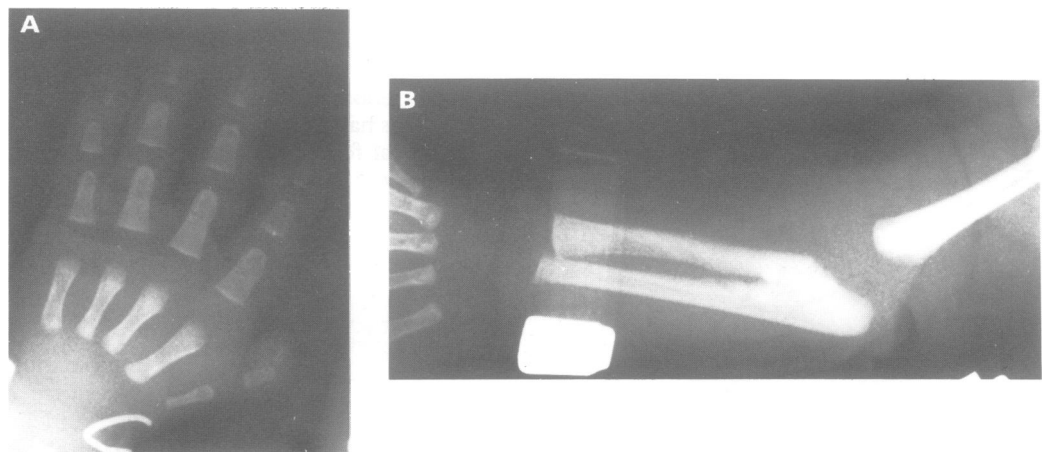


Figure 3 Radiographs of proband's left hand (A) and arm (B) at 4 months of age. The first metacarpal and phalanges are hypoplastic (A) and proximal radioulnar synostosis is present (B).

OTHER MALFORMATIONS

A variety of other structural anomalies have been reported less frequently. Genitourinary abnormalities have included vesicoureteral reflux,²⁸ unilateral renal agenesis,²⁵ external genital hypoplasia,^{11,16} duplicated ureter,¹⁶ and bicornuate uterus.^{16,27} Gastrointestinal abnormalities have included gastroschisis²⁹ and Hirschsprung's disease.¹¹ Cardiovascular malformations have included tetralogy of Fallot,^{20,30} a ventricular septal defect,¹⁶ and subvalvular muscular obstruction of the right ventricular outflow tract.⁸ Central nervous system anomalies have included microcephaly,^{11,24,28,31} aqueductal stenosis resulting in hydrocephalus,²⁰ and polymicrogyria.²⁰

Genetics

Most cases of NAD have been sporadic with no recognised affected family members. No

karyotypic abnormality has been reported. Six cases of parent to child transmission have been reported⁹⁻¹² (mother to child in three cases, father to son in three cases). In the family we report here, an affected son (fig 1) was born to an affected mother (fig 2), displaying probable autosomal dominant inheritance. Another example of autosomal dominant inheritance was reported by Weinbaum *et al.*¹³ The proband had typical features of NAD and milder clinical features were present in five other family members spanning four generations. NAD has been found to display a wide range of penetrance and expressivity (table). For example, Le Merrer *et al.*⁹ reported an infant with lethal NAD with severe mandibulofacial dysostosis and phocomelia. The mother, however, was relatively mildly affected with features including downward slanting palpebral fissures, malar hypoplasia, a hypoplastic right thumb, and a triphalangeal right thumb. In addition,

Primary clinical features of Nager acrofacial dysostosis (NAD).

Clinical features	Published cases*	Present cases†		Apparently autosomal recessive cases‡	Autosomal dominant cases§
		Proband	Mother		
<i>Craniofacial</i>					
Malar hypoplasia	67/67	+	+	7/7	13/13
Downward slanting palpebral fissures	61/61	+	+	6/6	12/12
Reduced number of eyelashes	20/25	+	–	1/3	5/6
Lower lid coloboma	15/30	–	–	3/3	1/5
High nasal bridge	43/44	+	+	4/4	4/4
Micrognathia	68/69	+	+	6/6	13/13
Cleft palate	26/36	–	+	2/2	5/6
Absent soft palate	14/14	–	–	–	–
Cleft lip	6/60	–	–	2/5	1/9
Extension of hair onto cheek	10/14	–	–	–	3/5
External ear defects	51/56	+	+	8/9	8/10
External auditory canal atresia	48/52	–	+	8/8	6/8
Low set ears	39/39	+	+	3/3	6/6
Conductive hearing loss	33/35	+	+	5/5	6/6
<i>Limb defects</i>					
Absent thumb	44/67	+	–	6/6	6/7
Hypoplastic thumb	33/69	+	+	4/4	11/11
Radial hypo/aplasia	34/34	–	–	5/5	3/5
Proximal radioulnar synostosis	16/19	+	–	5/6	2/2
<i>Other structural anomalies</i>					
Central nervous system	6				
Cardiovascular system	4			1	
Gastrointestinal tract	3				1
Genitourinary	7				1

* Clinical features previously reported in 76 cases of NAD.^{3–39}

† NAD family described in this report; affected family members include the proband (fig 1) and his mother (fig 2).

‡ Five previously reported families with normal parents and 2 affected sibs.^{3–7}

§ These eight families include the NAD family described in this report (figs 1 and 2) and seven previously reported cases showing vertical transmission.^{9–13}

Halal *et al*²⁸ described a child with typical NAD whose mother's features were limited to micrognathia. These case reports are most consistent with NAD being inherited as an autosomal dominant trait with variable penetrance and expressivity.

The occurrence of consanguinity in two cases^{16,31} and the observation of six families with normal parents and two affected sibs^{3–8} have suggested that NAD may also be inherited as an autosomal recessive trait. In the case reported by Byrd *et al*,⁸ the affected sibs were female monozygotic twins, an observation consistent with either autosomal recessive or autosomal dominant inheritance. As shown in the table, the apparently dominant and recessive forms of NAD have phenotypic overlap; the clinical features of the patients with a presumably autosomal recessive form of NAD were similar to those reported for affected family members showing autosomal dominant inheritance. No phenotypic features distinguished either group of patients. In addition, the clinical features of patients with an apparently sporadic form of NAD were indistinguishable from those of the inherited cases. Although these cases indicate that genetic heterogeneity is likely, it is not possible to exclude parental germline mosaicism⁴⁰ as a possible explanation for some of the cases attributed to an autosomal recessive trait.

Growth and development

Generally, growth was reported as normal. However, short stature was reported in 11 cases. In the 76 reported cases, development was reported as normal in 22 and delayed in four cases; isolated speech and language delays occurred in eight cases. No developmental details were available in 30 cases; 15 affected patients died in the perinatal period and 15 affected patients were reported as newborns or infants. In 10 cases, no details regarding de-

velopment were provided. Mental retardation was reported in two affected subjects.^{24,28} Developmental delays, particularly in the area of speech and language, were attributed to hearing loss, frequent admissions to hospital, and other medical problems.

Natural history and management

Fifteen affected subjects (20%) were stillborn or died in the neonatal period. Most of these were severely affected with facial clefting and severe limb reduction anomalies. Most of these cases had structural anomalies of the cardiovascular, gastrointestinal, or genitourinary systems. Respiratory distress, as a result of mandibular hypoplasia and palatal anomalies, contributed to the cause of death in nine of the 15 cases. Several surgical techniques have been used to maintain airway patency. Tongue–lip suturing, gavage feeding, gastrostomy, and tracheostomy have all been described in NAD patients; gastrostomy or gavage feeding was necessary in most of the reported cases. Measures taken to protect airway patency, such as tracheostomy and gastrostomy, may interfere with normal oral motor development and result in speech and language delays. Early audiological evaluations and speech therapy are recommended. A multidisciplinary team approach with the involvement of neonatology, paediatrics, otolaryngology, plastic surgery, dentistry, reconstructive hand surgery, and genetics best meets the many needs of the NAD patient. The prenatal diagnosis of NAD has been described.^{4,19}

Differential diagnosis

Mandibulofacial dysostosis (Treacher-Collins syndrome) and maxillofacial dysostosis have facial features closely resembling NAD but lack the limb abnormalities. Postaxial acro-

facial dysostosis syndrome^{41,42} can be differentiated from NAD by the involvement of the fifth digital ray of all four limbs and the high frequency of accessory nipples. The Genée-Wiedemann syndrome is characterised by postaxial limb involvement with involvement of the ulna and fibula, facial dysostosis, and cup shaped auricles. Wagner and Cole⁴³ reported a case of a male infant with a duplication of 2q31qter with some features suggestive of NAD, including downward slanting palpebral fissures, shallow orbits, posteriorly rotated ears, a hypoplastic mandible, and short radii; however, cardinal features of NAD, such as hypoplastic thumbs, cleft palate, and deafness, were not present. Although Fontaine syndrome⁴⁴ has some features in common with NAD, such as cleft palate and micrognathia, the hand and feet anomalies are different and consist of ectrodactyly and cleft hands and feet. Radial ray defects occur in a number of other syndromes such as Holt-Oram syndrome, VATER association, TAR syndrome, and Fanconi syndrome.

We thank the patient and family for their continued cooperation and Susan Williamson and Diane Voss for assistance in preparing the manuscript. This work was supported in part by the State of Michigan Department of Public Health Newborn Screening and Genetic Services Project to JLG.

- 1 Nager FR, de Reynier JP. Das Gehörorgan bei den angeborenen kopfmisbildungen. *Pract Otorhinolaryngol* 1948;10(suppl 2):1-128.
- 2 Slingenberg B. Misbildungen von extremitäten. *Virchow Arch (Pathol Anat)* 1908;193:1-91.
- 3 Chemke J, Mogilner B, Ben-Ithzhak I, Zurkowski L, Ophir D. Autosomal recessive inheritance of Nager acrofacial dysostosis. *J Med Genet* 1988;25:230-2.
- 4 Hecht J, Immken L, Harris LF, Malini S, Scott C. Brief clinical report: the Nager syndrome. *Am J Med Genet* 1987;27:965-9.
- 5 Walker F. Apparent autosomal recessive inheritance of the Treacher-Collins syndrome. *Birth Defects* 1974;10:135-9.
- 6 Richieri-Costa A, Gollop T, Colletto G. Brief clinical report: syndrome of acrofacial dysostosis, cleft lip/palate, and triphalangeal thumb in a Brazilian family. *Am J Med Genet* 1983;14:225-9.
- 7 Neidhart E. Die dysostosis mandibulofacialis (Franceschetti-Zwahlen-Klein syndrome) in kombination mit misbildungen der oberen extremitäten. Zurich, Inaug Diss, 1968.
- 8 Byrd LK, Rogers RC, Stevenson RE. Nager acrofacial dysostosis in four patients including monozygous twins. *Proc Greenwood Genet Center* 1988;7:30-5.
- 9 Le Merrer M, Cikuli M, Ribier J, Briard M. Acrofacial dysostosis. *Am J Med Genet* 1989;33:318-22.
- 10 Hall B. Nager acrofacial dysostosis: autosomal dominant inheritance in mild to moderately affected mother and lethally affected phocomelic son. *Am J Med Genet* 1989;33:394-7.
- 11 Aylesworth A, Lin A, Friedman P. Nager acrofacial dysostosis: male-to-male transmission in 2 families. *Am J Med Genet* 1991;41:83-8.
- 12 Kim HJ, Fragosa M, Chavez A. Nager syndrome with autosomal dominant inheritance. *Clinical Genetics Conference (Boston)* 1989:A39.
- 13 Weinbaum M, Russell A, Bixler D. Autosomal dominant transmission of Nager acrofacial dysostosis. *Am J Hum Genet* 1981;33:A93.
- 14 Klein D, König H, Tobler R. Sur une forme extensive de dysostose mandibulofaciale (Franceschetti) accompagnée de malformations des extremités. *Rev Oto-Neuro-Ophthalmol* 1970;42:432-40.
- 15 Lowry RB. The Nager syndrome (acrofacial dysostosis): evidence for autosomal dominant inheritance. *Birth Defects* 1977;13:195-220.
- 16 Kawira EL, Weaver DD, Bender HA. Acrofacial dysostosis with severe facial clefting and limb reduction. *Am J Med Genet* 1984;17:641-7.
- 17 Krauss C, Hassell L, Gang D. Brief clinical report: anomalies in an infant with Nager acrofacial dysostosis. *Am J Med Genet* 1985;21:761-4.
- 18 Giugliani R, Pereira CH. Nager acrofacial dysostosis with thumb duplication: report of a case. *Clin Genet* 1984;26:228-30.
- 19 Benson C, Prober B, Hirsh M, Doubilet P. Sonography of Nager acrofacial dysostosis syndrome in utero. *J Ultrasound Med* 1988;7:163-7.
- 20 Goldstein D, Mirkin D. Nager acrofacial dysostosis: evidence for apparent heterogeneity. *Am J Med Genet* 1988;30:741-6.
- 21 Meyerson M, Jensen K, Meyers J, Hall B. Nager acrofacial dysostosis: early intervention and long-term planning. *Cleft Palate J* 1977;14:35-40.
- 22 Meyerson M, Nisbet JB. Nager syndrome: an update of speech and hearing characteristics. *Cleft Palate J* 1987;24:142-51.
- 23 Jackson I, Bauer B, Saleh J, Sullivan C, Argenta L. A significant feature of Nager syndrome: palatal agenesis. *Plastic Reconstr Surg* 1989;84:219-26.
- 24 Palomeque A, Pastor X, Ballesta F. Nager anomaly with severe facial involvement, microcephaly, and mental retardation. *Am J Med Genet* 1990;36:356-67.
- 25 Pfeiffer RA, Stoess H. Acrofacial dysostosis (Nager syndrome): synopsis and report of a new case. *Am J Med Genet* 1983;15:255-60.
- 26 Jones G. Mandibulofacial dysostosis. *Ctr Afr J Med* 1968;14:193-200.
- 27 Schonenberg H. Die differential diagnose der radialem defektbildungen. *Padiatr Prax* 1968;7:455-67.
- 28 Halal F, Herrmann J, Pallister P, Opitz J, Desgranges MF, Grenier G. Differential diagnosis of Nager acrofacial dysostosis syndrome: report of four patients with Nager syndrome and discussion of other related syndromes. *Am J Med Genet* 1983;14:209-24.
- 29 Marden P, Smith D, McDonald M. Congenital anomalies in the newborn infant, including minor variations. *J Pediatr* 1964;64:357-71.
- 30 Thompson E, Cadbury R, Baraitser M. The Nager acrofacial dysostosis syndrome with the tetralogy of Fallot. *J Med Genet* 1985;22:408-10.
- 31 Burton B, Nadler H. Nager acrofacial dysostosis: report of a case. *J Pediatr* 1977;91:84-6.
- 32 Ruedi L. The surgical treatment of the atresia auris congenita: a clinical and histological report. *Laryngoscope* 1954;64:666-70.
- 33 Gellis S, Feingold M, Miller D. Picture of the month: Nager syndrome (Nager acrofacial dysostosis). *Am J Dis Child* 1978;132:519-20.
- 34 Yi-Che C. Mandibulofacial dysostosis. *Chin Med J* 1960;80:373-5.
- 35 Fernandez A, Ronis M. The Treacher-Collins syndrome. *Arch Otolaryngol* 1964;80:505-20.
- 36 Bowen P, Harley F. Mandibulofacial dysostosis with limb malformations (Nager acrofacial dysostosis). *Birth Defects* 1974;10:109-15.
- 37 Pfeiffer R. Associated deformities of the head and hands. *Birth Defects* 1969;5:18-34.
- 38 Golabi M, Melnicoe L, Vargervik K. Nager syndrome: report of seven new cases and a follow-up report of two previously reported cases. *Proc Greenwood Genet Center* 1985;4:127-38.
- 39 Danziger I, Brodsky L, Perry R, Nusbaum S, Bernat F, Robinson L. Nager acrofacial dysostosis: case report and review of the literature. *Int J Pediatr Otorhinolaryngol* 1990;20:225-40.
- 40 Hall JG. Review and hypotheses. Somatic mosaicism: observations related to clinical genetics. *Am J Hum Genet* 1988;43:355-63.
- 41 Miller M, Fineman R, Smith D. Postaxial acrofacial dysostosis syndrome. *J Pediatr* 1979;95:970-5.
- 42 Fineman R. Recurrence of the postaxial acrofacial dysostosis syndrome in a sibship: implications for genetic counseling. *J Pediatr* 1981;98:87-8.
- 43 Wagner SF, Cole J. Nager syndrome with partial duplication of the long arm of chromosome 2. *Am J Hum Genet* 1979;31:A116.
- 44 Fontaine G, Farriaux JP, Delattre P, et al. Une observation familiale du syndrome ectrodactylie et dysostose mandibulofaciale. *J Genet Hum* 1974;22:289-307.