

Sex linked valvular dysplasia

R A Newbury-Ecob, J M Zuccollo, N Rutter, I D Young

Abstract

A family is described in which three males have been affected by congenital valvular dysplasia of one or more heart valves, in one case leading to neonatal death. The pedigree is consistent with sex linked inheritance.

(J Med Genet 1993;30:873-4)

Congenital heart disease is aetiologically heterogeneous. Structural cardiac lesions may be the result of an isolated error of morphogenesis or part of a syndrome with extracardiac malformations. In a small number of cases the aetiology can be clearly identified as teratogenic, implicating drugs or in utero infections such as rubella, the result of an abnormal karyotype, or resulting from single gene disorders. For the majority of isolated congenital heart defects the polygenic model of inheritance is used. Studies have clearly shown an increased incidence of congenital heart disease in first degree relatives.¹

It is well recognised that mitral valve prolapse, which is present in approximately 5% of the general population, shows familial clustering with probable autosomal dominant inheritance.² Dominant inheritance of supravalvular aortic stenosis has also been described.³ Sex linked inheritance of a more generalised valvular dysplasia has been documented in a single family.⁴ We now report a second family showing evidence of a sex linked recessive valvular dysplasia.

Case reports

The family pedigree is illustrated in the figure.

PATIENT 1 (IV·1)

A 26 year old woman, whose husband was healthy and unrelated, had an uneventful pregnancy until an ultrasound scan at 36 weeks by dates showed an abnormal fetal heart with

dilatation of the right atrium and right ventricle, along with a small left atrium and left ventricle. No aortic or mitral valves could be visualised and it was felt that this combination of features was suggestive of the hypoplastic left heart syndrome. No extracardiac abnormalities could be detected.

In view of the poor outlook for the baby labour was induced at 37 weeks and proceeded to a normal delivery of a live male infant weighing 2640 g. At birth the baby was not asphyxiated (Apgar scores of 8 at one minute and 9 at five minutes) and on examination at 11 hours the baby had no dysmorphic features. There was no evidence of cyanosis although he was mildly tachypnoeic. The cardiac apex was prominent and the praecordium bulging. Cardiac output was poor with decreased brachial and femoral pulses. A moderate systolic murmur was audible at the left sternal edge together with an apical gallop rhythm.

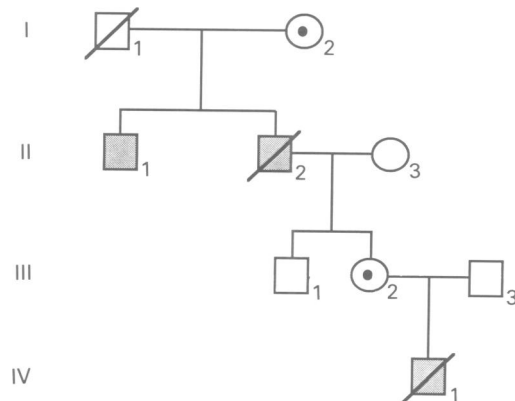
Postnatal echocardiography confirmed the severity of the cardiac lesion, showing dilatation of the right atrium, right ventricle, and pulmonary artery. The left atrium was of normal size while the mitral valve showed abnormal thickening. The left ventricle was small with a hypoplastic aortic root. There was evidence of left ventricular outflow obstruction and a small atrial septal defect.

The baby gradually developed severe cardiac failure and died at 24 hours of age. Necropsy showed an enlarged heart with massive dilatation of the right atrium, hypertrophy and dilatation of the right ventricle, a normal left atrium, and small left ventricle. There was an atrial septal defect with a short septum primum. All four valves were abnormal. The tricuspid and mitral valves had oedematous and irregular cusps. The chordae were short and irregular. The aortic and pulmonary valves were bicuspid but also showed thickening and oedema of the cusps. The aortic ring was stenotic. The great vessels, aortic arch, and descending aorta were normal. There were no extracardiac abnormalities.

PATIENT 2 (II·2)

The maternal grandfather also suffered from congenital heart disease. He was asymptomatic until the age of 25 years. He then developed progressive breathlessness and at the age of 41 years he was referred for triple valve replacement and closure of a persistent foramen ovale with a provisional diagnosis of Ebstein's anomaly, mitral, aortic, and tricuspid valve disease, and gross cardiomegaly. There was no history of rheumatic fever.

At surgery the mitral and aortic valves were incompetent showing mucinous degeneration with secondary calcification. They were re-



The family pedigree.

Department of
Clinical Genetics, City
Hospital, Hucknall
Road, Nottingham
NG5 1PB, UK.
R A Newbury-Ecob
I D Young

Department of
Histopathology,
University Hospital,
Nottingham, UK.
J M Zuccollo

Department of Child
Health, University
Hospital, Nottingham,
UK.
N Rutter

Correspondence to
Dr Newbury-Ecob.

Received 11 January 1993.
Revised version accepted
7 April 1993.

placed with Bjork Shiley prostheses. The abnormal tricuspid valve was replaced with a pig xenograft. Unfortunately, despite a good cardiac response to surgery with a marked reduction in heart size, he became oliguric and died of renal failure eight weeks postoperatively.

Necropsy confirmed dilatation of both ventricles and atria, the right more than the left. The anterior wall of the right atrium was thin and poorly formed.

PATIENT 3 (II·1)

The brother of patient 2 was investigated for chest pains and breathlessness at the age of 30 and was diagnosed as having mitral valve prolapse. Cardiac catheterisation showed a parachute mitral valve.

Eight years later he experienced occasional episodes of palpitations and was reinvestigated. On examination he had the characteristic midsystolic click and late systolic murmur of mitral valve prolapse. Echocardiography showed a degree of prolapse of both the mitral and aortic valves with minimal enlargement of the left atrium. The interventricular septum was thin and contracted poorly and the right and left ventricles were of similar size. Neither patient 3 (II·1) nor his brother, patient 2 (II·2), had a history of rheumatic fever in childhood.

PATIENT 4 (III·2)

The mother of the baby herself had been investigated for a murmur which was first noted at the age of 3 years. During pregnancy this was reinvestigated and on the basis of electrocardiography and echocardiography concluded to be of no significance.

PATIENT 5 (III·1)

The brother of patient 4 is healthy and recent cardiac examination showed no abnormality.

Discussion

Within this family three males have been affected by cardiac valvular dysplasia and in at least one this was congenital in origin. The family pedigree is clearly consistent with sex linked inheritance. A similar family was reported in 1969 by Monteleone and Fagan⁴ who documented variable valvular involvement in five males, as summarised in the table. A sixth male had died at the age of 25 years as a result of ill defined 'congenital heart disease'. This family pedigree was also consistent with sex linked recessive inheritance with no examples of male to male transmission.

The basic pathology appears to be a mucinous degeneration of the valve leaflets. This was confirmed in both of the dead males in our family and in case III·1 in the family of Monteleone and Fagan.⁴ The clinical course varies according to the number of valves involved and the degree of dysplasia. Patient 1, who died shortly after birth, was the most severely affected with quadrivalvular dysplasia and hypoplasia of the left ventricle. In contrast, patient 3 was almost asymptomatic at the age of 38 years with only mild involvement of his mitral and aortic valves. Similar variation in severity was noted in the family of Monteleone and Fagan.⁴

Myxomatous degeneration of heart valves may be associated with clinical evidence of connective tissue abnormalities, for example, in Marfan syndrome.⁵ No stigmata of this or any other connective tissue disorder were found in this family. Examples of sex linked genes causing structural abnormalities limited to the heart are extremely rare. The only other report of which we are aware is that of Soltan and Li⁶ who in 1974 described a family in which four males had dextrocardia in association with other variable cardiac anomalies, which included transposition of the great arteries, ventricular septal defect, and pulmonary atresia. The family now reported suggests that generalised valvular dysplasia can also rarely result from a mutation on the X chromosome.

Valvular involvement in sex linked valvular dysplasia.

Case	Age (y)	Valvular insufficiency			
		Aortic	Mitral	Tricuspid	Pulmonary
Monteleone and Fagan ⁴					
III-1	29*	+	+	+	
III-2	15*	+	+		
III-7	12	+	+	+	
III-9	7		+		
IV-1	8/12*		+		
Present report					
II-1	44	+	+		
II-2	41*	+	+	+	
IV-1	24 hours*	+	+	+	+

* Age at death.

- 1 Nora JJ, Nora AH. Update on counseling the family with a first degree relative with a congenital heart defect. *Am J Med Genet* 1988;29:137-42.
- 2 Devereux RB, Brown WT, Kramer-Fox R, Sacha I. Inheritance of mitral valve prolapse: effect of age and sex on gene expression. *Ann Intern Med* 1982;97:826-32.
- 3 Eisenberg R, Young D, Jacobson B, Boito A. Familial supra-aortic stenosis. *Am J Dis Child* 1964;108:341-7.
- 4 Monteleone PL, Fagan LF. Possible X-linked congenital heart disease. *Circulation* 1969;39:611-14.
- 5 Read R, Thal AP, Wendt MD. Symptomatic valvular myxomatous transformation (the floppy valve syndrome). A possible forme fruste of the Marfan syndrome. *Circulation* 1965;32:897-910.
- 6 Soltan HC, Li MD. Hereditary dextrocardia associated with other congenital heart defects: report of a pedigree. *Clin Genet* 1974;5:51-8.