

## 46,XX/69,XXX diploid-triploid mixoploidy with hypothyroidism and precocious puberty

I E Järvelä, M K Salo, P Santavuori, R K Salonen

### Abstract

**We report a 20 month old female patient with diploid-triploid mixoploidy (46,XX/69,XXX) syndrome with hypothyroidism and precocious puberty. The triploid cell line was only expressed in the fibroblast culture and comprised the majority (95%) of the cells. Chromosome analysis of the fetal blood sample and peripheral blood sample were normal. The patient shows typical features of full triploidy (growth and severe mental retardation, cranial and facial dysmorphism, complete syndactyly of fingers 3/4, partial syndactyly of toes 2/3) and facial but no body asymmetry. At the age of 5 months central hypothyroidism and precocious puberty were diagnosed. Thin pigmented streaks were visible on the wrists and legs of the patient at the age of 16 months. This is the first patient reported so far with 46,XX/69,XXX mixoploidy suffering from hypothyroidism and precocious puberty.**

(*J Med Genet* 1993;30:966-7)

Triploidy is the most frequent chromosome aberration in first trimester spontaneous abortions.<sup>1</sup> Living patients are rare as most of them die during the first hours or days. There are around 20 reports of diploid-triploid mosaicism.<sup>2-8</sup> Severe intrauterine growth retardation, facial or body asymmetry, syndactyly of fingers 3 and 4, characteristic dysmorphic facies, and mental retardation are the main symptoms. Abnormal genitalia are one of the major abnormalities in males expressing diploid-triploid mixoploidy and luteinising hormone insufficiency has been discussed as a causative mechanism.<sup>3</sup> Eight previous reports of females suffering from 46,XX/69,XXX mixoploidy are known to us with no genital or hormonal abnormalities.

### Case report

The patient was the product of a 34 week gestation of a 24 year old gravida 1, para 1 mother whose pregnancy was complicated by uterine haemorrhage at 17 weeks. The chromosomes of the fetus were analysed from a cord blood sample at 30 weeks of gestation because of intrauterine growth retardation (IUGR) and were normal. No structural abnormalities were detected in the fetus on repeated ultrasound examinations. Delivery was carried out by caesarean section because of breech presentation and changes in cardiocography. Birth weight was 1310 g and length was 39 cm (-3.5th centile). Head circumfer-

ence was 30 cm (-1.5th centile). Apgar scores were 7 and 10. The placenta weighed 420 g with no abnormalities. At birth multiple congenital anomalies were noted including a narrow skull, small mandible, hypertelorism, short palpebral fissures, low set ears, high and narrow palate, narrow chest, complete syndactyly of fingers 3/4, and partial syndactyly of toes 2/3. A persistent ductus arteriosus was closed by indomethacin. The external genitalia were normal. There was slight facial asymmetry but none of the body (fig 1).

On x ray slender bones and relatively short proximal phalanges were noted. Abdominal ultrasound indicated normal kidneys, gall bladder, liver, and pancreas. EEG after birth was normal. On cranial ultrasound a severe midline defect was found. There was absence of the septum pellucidum and the posterior part of the corpus callosum confirmed by CT and MRI scans. Neurological development was strikingly delayed with hypotonia and areflexia. After birth the child had feeding difficulties for 5 months. Repeated chromosome analysis on peripheral blood was normal as were the chromosomes of the parents.

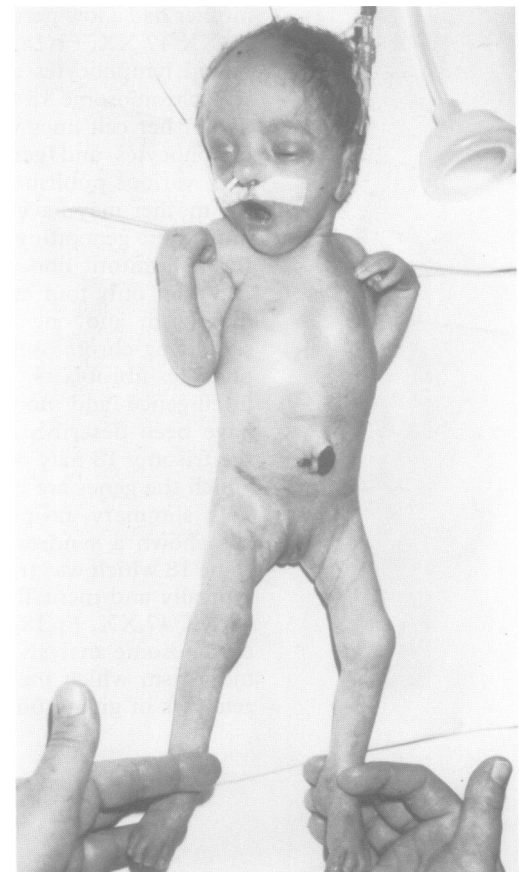


Figure 1 The proband soon after birth.

Department of  
Medical Genetics,  
Helsinki University  
Hospital, Helsinki,  
Finland.

I E Järvelä

Department of  
Paediatrics, Helsinki  
University Hospital,  
Helsinki, Finland.

M K Salo  
P Santavuori

Laboratory of  
Prenatal Genetics,  
Department of  
Obstetrics and  
Gynaecology, Helsinki  
University Hospital,  
Helsinki, Finland.  
R K Salonen

Correspondence to  
Dr Järvelä, The Rayne  
Institute, University College  
London, Department of  
Paediatrics, University  
Street, London WC1E 6JJ.

Received 3 February 1993.  
Revised version accepted  
25 June 1993.

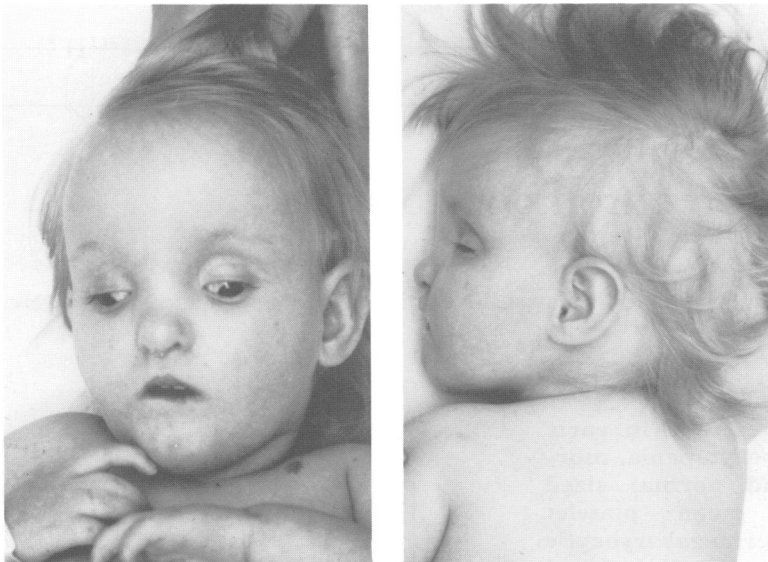


Figure 2 The proband at the age of 19 months.

At the age of 5 months the patient was investigated because of vaginal bleeding. She had enlarged breasts, but no pubic hair or other visible signs of precocious puberty. Ultrasound showed an enlarged uterus and active left ovary (one cyst, diameter 11 mm). Serum oestradiol concentration was markedly increased (145 pmol/l, normal <75 pmol/l) and the responses of luteinising (LH) and follicle stimulating hormones (FSH) to gonadotrophin releasing hormone were pubertal (peak concentrations of LH 23.4 (normal <10) and FSH 35.9 IU/l (normal <26)). A diagnosis of central precocious puberty was made. Delayed response of thyrotrophin (TSH) releasing hormone (TSH concentrations at 20 and 60 minutes were 21.6 and 26.6 IU/l, respectively) showed central hypothyroidism. Serum free thyroxine concentration was 7 pmol/l (normal 9–20 pmol/l). Thyroxine substitution 25 µg daily was started, but the signs of precocious puberty and central activation of the hypophyseal-gonadal axis have gradually subsided without treatment.

Ophthalmological investigation showed divergent strabismus at the age of 8 months. At the age of 13 months atypical infantile spasms (with features of partial seizures) were noted. EEG showed hypsarrhythmia. With sodium valproate-vigabatrin medication the fits disappeared. From the age of 15 months the child has had frequent and severe respiratory and ear infections. At the age of 15 months the

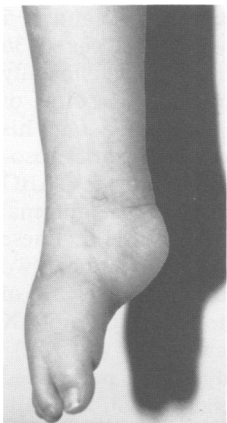

Figure 3 Thin streaky pigmentation on the leg of the proband.

facial asymmetry and dysmorphism were more distinct (fig 2) and thin streaky pigmentation was noticed on the wrists and legs of the patient (fig 3). A fibroblast culture from normal skin on the left arm showed diploid-triploid mosaicism in the majority of cells studied (28/30 cells). At follow up, the psychomotor development of the patient was clearly delayed, especially motor function. At the age of 23 months she responded to her environment but was not able to turn over.

## Discussion

Complete triploid pregnancies usually result in spontaneous abortions. The longest reported survival time has been 7 months.<sup>9</sup> Diploid-triploid mixoploidy is rarer and its origin is not well understood.<sup>8</sup> The clinical abnormalities are similar to complete triploidy but milder, and survival is much longer. The genital abnormalities of male patients suffering from diploid-triploid mixoploidy are well documented<sup>3-5</sup> but no reports concerning the genital and endocrinological findings of female patients are known to us so far. In complete triploidy (69,XXX) hypoplastic external genitalia, unicornuate uterus, and ovarian dysgenesis with few or no oocytes have been described in two fetuses.<sup>10</sup> Disorders of the CNS are common in these patients which may lead to abnormalities in the limbic system, hypothalamus, and pituitary gland, further affecting the adrenal glands and genitalia.

- 1 Boue J, Boue A, Lazar P. Retrospective and prospective epidemiological studies of 1500 karyotyped spontaneous human abortions. *Teratology* 1975;12:11-26.
- 2 Fryns JP, Viken L, Geutjens J, Marien J, Deroover J, Van den Berghe H. Triploid-diploid mosaicism in a deeply mentally retarded adult. *Ann Genet (Paris)* 1980;23:222-34.
- 3 Graham JM, Hoehn H, Lin MS, Smith DW. Diploid-triploid mixoploidy: clinical and cytogenetic aspect. *Pediatrics* 1981;68:23-8.
- 4 Blackburn WR, Miller WP, Superneau DW, Cooley NR Jr, Zellweger H, Wertelecki W. Comparative studies of infants with mosaic and complete triploidy: an analysis of 55 cases. *Birth Defects* 1982;18(3B):251-74.
- 5 Tharapel AT, Wilroy RS, Martens PR, Holbert JM, Summit RL. Diploid-triploid mosaicism: delineation of a syndrome. *Ann Genet (Paris)* 1983;26:229-33.
- 6 Pettenati MJ, Mirkin LD, Goldstein DJ. Diploid-triploid mosaicism: report of necropsy findings. *Am J Med Genet* 1986;24:23-8.
- 7 Meinecke P, Engelbrecht R. Fehlbildungssyndrom infolge inkompletter triploidie. *Monatschr Kinderheilkd* 1988;136:206-9.
- 8 Donnai D, Read AP, McKeown C, Andrews T. Hypomelanosis of Ito: a manifestation of mosaicism or chimerism. *J Med Genet* 1988;25:809-18.
- 9 Schinzel A. *Catalogue of unbalanced chromosome aberrations in man*. Berlin: de Gruyter, 1984.
- 10 Cunniff C, Jones KL, Benirschke K. Ovarian dysgenesis in individuals with chromosomal abnormalities. *Hum Genet* 1991;86:552-6.