

## Case reports

# Single maxillary central incisor in a girl with del(18p) syndrome

David J Aughton, Abdul A AlSaadi, David J Transue

### Abstract

**We present a girl with del(18p) syndrome and a single maxillary central incisor; she is only the second patient in whom this association has been reported.**

Del(18p) syndrome results from deletion of all or part of the short arm of chromosome 18 and is probably the second most frequent autosomal deletion syndrome. It is associated with a recognisable clinical phenotype, which includes some degree of holoprosencephaly in at least 10% of cases.<sup>1</sup> Single maxillary central incisor can be a mild manifestation of holoprosencephaly in some cases.<sup>2</sup> This finding has been reported only once previously in association with del(18p) syndrome.<sup>3</sup> Here we present a second affected child with del(18p) syndrome and single maxillary central incisor.

### Case report

The proband was the product of an uncomplicated term pregnancy; delivery was forceps assisted, and the intrapartum period was complicated only by meconium staining of the amniotic fluid. Apgar scores were 5 at one minute and 9 at five minutes. Birth weight was 2610 g (10th centile) and length was 45.75 cm (10th centile).

Early motor development was normal; however, acquisition of speech was delayed. Concern over statural growth when the proband was 3 years old

prompted endocrinological evaluation and routine chromosome analysis of peripheral blood. The karyotype was 46,XX,del(18p) in 48 of 50 cells analysed. Two cells had other abnormalities: in one, two small additional chromosomes were present, and in another an additional small submetacentric chromosome was present. A diagnosis of del(18p) syndrome was made. Parental karyotypes were normal.

She underwent further genetic evaluation at the age of 7 years. Her history was remarkable for thamuria, a single maxillary central incisor, and dental caries; her IQ was reportedly 64. Previous evaluation for diabetes mellitus was normal. Family history was remarkable only for cleft lip and palate in a first cousin once removed. Neither parent had a single maxillary central incisor and there was no known consanguinity.

On examination, she was 107 cm tall (<5th centile) and weighed 19.1 kg (5th centile). A single maxillary central incisor was evident (fig 1) and the teeth showed evidence of numerous dental interventions. The palate was intact and of normal contour. Further examination showed subtle dysmorphism (fig 1), including thick pinnae, a small pit anterior to the right pinna, a small nose, a long philtrum, bilateral fifth finger clinodactyly, bilateral single transverse palmar creases, two small café au lait spots, and fine axillary hair, without other signs of androgenisation.

Computed tomography of the cranium was normal, without evidence of holoprosencephaly or other midline defects. Further endocrinological evaluation included normal serum electrolytes, 24 hour urine volume, urine specific gravity, and urinary 17-ketosteroids (2.5 mg/24 hours). Growth velocity was normal. Anterior and posterior pituitary functions were normal, and there was no evidence of hypothalamic or pituitary dysfunction. Diabetes insipidus was thus considered unlikely, and the thamuria was considered more likely to be psychogenic. High resolution chromosome analysis of peripheral blood showed a 46,XX,del(18p) karyotype in each of 25 cells, without evidence of marker chromosomes (fig 2).

Division of Genetics, Department of Pediatrics, William Beaumont Hospital, 3601 West Thirteen Mile Road, Royal Oak, Michigan 48073, USA.

D J Aughton, D J Transue

Department of Anatomic Pathology, William Beaumont Hospital, Royal Oak, Michigan 48073, USA.  
A A AlSaadi

Correspondence to Dr Aughton.

Received for publication 10 October 1990.

Revised version accepted for publication 11 December 1990.

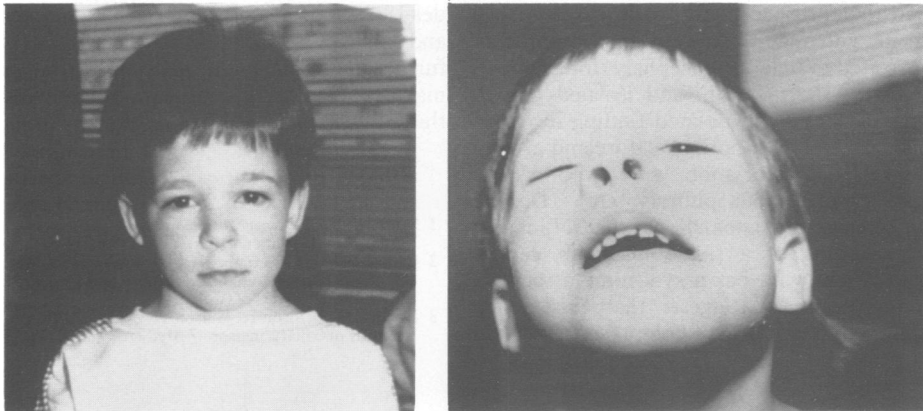


Figure 1 The proband at 7 years showing a single maxillary central incisor.

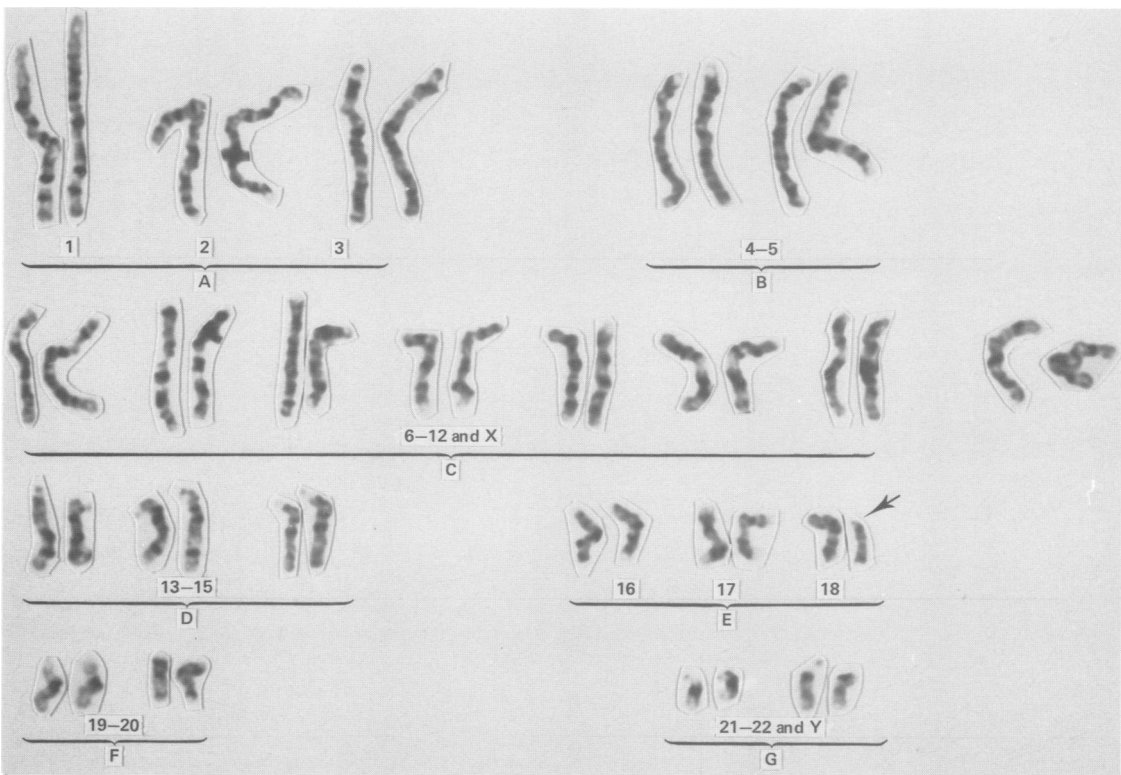


Figure 2 High resolution karyotype showing deletion of short arm of chromosome 18 (arrow).

**Discussion**

We have presented a girl with a single maxillary central incisor associated with del(18p) syndrome, an association reported only once previously.<sup>3</sup> Holoprosencephaly occurs in about 10% of cases of del(18p) syndrome<sup>1</sup>; however, no structural abnor-

malities of the CNS have been found in our patient, nor were such anomalies described in the previously reported patient with del(18p) syndrome and single maxillary central incisor. The latter can be a microform of holoprosencephaly (for example, in some cases of autosomal dominant holoprosencephaly). It is also

common in holoprosencephaly with severe facial dysmorphism, and may also occur in a number of settings unrelated to holoprosencephaly (for example, in subjects with short stature and isolated growth hormone deficiency; as an isolated finding in otherwise normal subjects with normal stature and growth hormone levels; in association with hypothalamic hamartoma and precocious puberty, etc).<sup>2</sup> Despite the absence of structural anomalies of the CNS in our patient, the finding of a single maxillary central incisor in a patient who has a syndrome associated with holoprosencephaly suggests that this dental anomaly may be a microform of holoprosencephaly in

del(18p) syndrome. Careful evaluation of the dentition and CNS of additional patients will be of value in further delineating the relationship between single maxillary central incisor and holoprosencephaly in this condition.

- 1 Schinzel A. *Catalogue of unbalanced chromosome aberrations in man*. Berlin: Walter de Gruyter, 1983:604-7.
- 2 Cohen MM Jr. Perspectives on holoprosencephaly. Part III. Spectra, distinctions, continuities, and discontinuities. *Am J Med Genet* 1989;34:271-88.
- 3 Dolan LM, Willson K, Wilson WG. 18p- syndrome with a single central maxillary incisor. *J Med Genet* 1981;18:396-8.