

Cranial hemihypertrophy and neurodevelopmental prognosis

J C S Dean, G F Cole, R E Appleton, J Burn, S A Roberts, D Donnai

Abstract

Three cases of congenital cranial hemihypertrophy are described. CT or ultrasound scans showed unilateral cerebral enlargement with dilatation of the ipsilateral ventricle. Seizures occurred in two patients and the neurodevelopmental outlook appears poor. These patients represent a poor prognosis subgroup of the congenital hemihypertrophies.

Congenital hemihypertrophy may occur as a solitary finding, or as a feature of a number of recognised syndromes, such as Proteus syndrome,¹ Klippel-Trenaunay-Weber syndrome,² and Beckwith-Wiedemann syndrome.³ The hemihypertrophy does not necessarily affect the full length of the body and nor need it be limited to one side. Rowe⁴ provided a subclassification into complex hemihypertrophy, simple hemihypertrophy, and hemifacial hypertrophy (table 1). The overall prevalence of mental handicap among patients with hemihypertrophy is said to be between 15 and 28%,⁵⁻⁷ but this includes patients whose hypertrophy may be limited to one limb or

Department of Medical Genetics, University of Aberdeen, Medical School Buildings, Foresterhill, Aberdeen AB9 2ZD.

J C S Dean

Department of Child Health, University of Aberdeen. G F Cole

Royal Victoria Infirmary, Newcastle upon Tyne. R E Appleton

Department of Human Genetics, University of Newcastle upon Tyne. J Burn

The Duchess of York Hospital, Manchester. S A Roberts

Regional Genetics Service, St Mary's Hospital, Manchester. D Donnai

Correspondence to Dr Dean.

Table 1 A subclassification of hemihypertrophy.

1 Complex Hemihypertrophy Involves an entire half of the body, or at least an arm and a leg. Enlarged parts may be all on the same side (complex ipsilateral hemihypertrophy) or found on both sides (complex contralateral hemihypertrophy).
2 Simple Hemihypertrophy Involves a single limb.
3 Hemifacial Hypertrophy Involves one side of the face. Enlarged area bounded superiorly by the frontal bone (not including the eye), inferiorly by the inferior border of the mandible, medially by the midline of the face, and laterally by the ear, the pinna being included in the hypertrophic area.

Modified from Rowe.⁴

even part of one limb (for example, macrodactyly). We report three infants with craniofacial involvement in order to contribute to knowledge of the neurodevelopmental implications in this subgroup.

Case reports

CASE 1

This was the first child of unrelated parents and there was no relevant family history. He was born at 36 weeks' gestation by emergency lower segment caesarian section (LSCS) for failure to progress in the second stage. Apgar scores were 2 and 5 at one and five minutes, respectively, and he was admitted to the Special Care Nursery for eight days with a diagnosis of perinatal asphyxia. His birth weight was normal, but the head circumference was >97th centile (table 2) and hemihypertrophy of the right side of the head

Table 2 Clinical features.

	Case 1	Case 2	Case 3
Pregnancy	Singleton	Singleton	Twin
Gestation (wk)	36	40	38
Mode of delivery	LSCS	SVD	SVD
HC at birth in cm (centile)	42 (>97th)	37 (90th)	33.5 (40th)
Birth weight in g (centile)	3320 (70th)	2920 (<10th)	2020 (<3rd)
Cranial hemihypertrophy	+	+	+
Ipsilateral ventricular dilatation	+	+	+
Pigmented/depigmented skin lesions	+	+	-
Seizures by age 3 mth	+	+	-
Developmental delay	+	+	+

LSCS=lower segment caesarian section. SVD=spontaneous vaginal delivery.

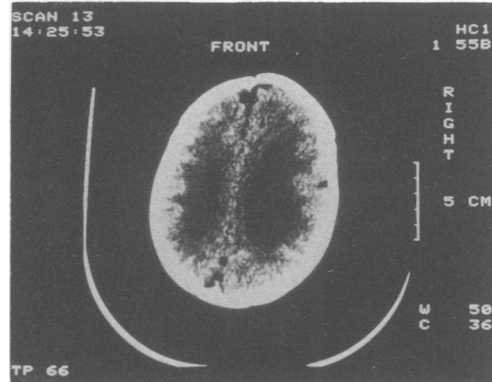
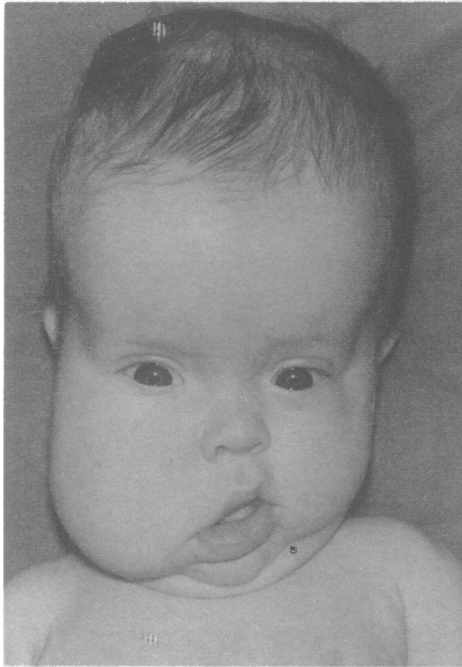


Figure 1 Case 1 aged 3 months and CT scan at 3 months.

was noted. CT scan of the head showed a small left intracranial haemorrhage and right ventricular dilatation. Generalised seizures began at 3 months of age (fig 1) and developmental delay was suspected. His head circumference was rising faster than the centile line and increasing ventricular dilatation was seen on CT scan of the head (fig 1). A right ventriculoperitoneal shunt was inserted.

At 6 months, diffuse lipomatosis of the right leg was noted, although leg lengths remained equal, and a depigmented patch was noted above the right knee.

At 11 months, he has marked developmental delay and is unable to lift his enlarged head from the horizontal plane.

Because of continuing growth in head circumference, and less than expected decrease in ventricular size, the ventriculoperitoneal shunt has been revised.

CASE 2

This was the second child of unrelated parents. Her brother is well and there is no relevant family history.

She was born at term by spontaneous vertex delivery after an uneventful pregnancy. Hemihypertrophy of the face was evident, affecting the left maxillary region, left ear, left side of the mandible, alveolar ridges, and left side of the tongue. Birth weight was just below the 10th centile and head circumference was on the 90th centile (table 2). There

was erythematous thickening of the skin of the left side of the face with striking demarcation in the midline (fig 2).

At 3½ months of age, she developed seizures and developmental delay became evident. The head circumference was rising faster than the centile line and CT scan (fig 2) showed enlargement of the left side of the brain and of the left lateral ventricle. The skin of the left side of the face was pigmented and eyelashes and eyebrows on the left were sparse. There was patchy hair loss of the left side of the scalp.

At 9 months, the overgrowth has progressed and the head circumference remains above the 95th centile at 50 cm. Development is delayed, although she can reach for and hold objects, particularly with the left hand.

CASE 3

This was the first of monozygotic twins delivered vaginally at 38 weeks' gestation. The parents are healthy and unrelated, and their previous child is well. There is no family history. His birth weight was well below the 3rd centile, but the head circumference was on the 40th centile (table 2). His twin brother weighed just below the 3rd centile and his head circumference was on the 10th centile.

The pregnancy had been uneventful. A routine fetal ultrasound scan at 16 weeks' gestation had indicated a biparietal diameter on the 90th centile in twin 1, with marked enlargement of the left lateral ventricle. Twin 2 had normal ventricles and a biparietal diameter on the 25th centile.

At delivery, twin 1 had marked hypertrophy of the left side of the head (fig 3), clinically more obvious in the lower face, and including the alveolar ridges. Cranial ultrasound showed marked dilatation of the left lateral ventricle, with slight dilatation of the right lateral and third ventricles. An organising haemorrhagic cast was present within the left lateral ventricle, suggestive of haemorrhage some weeks prenatally.

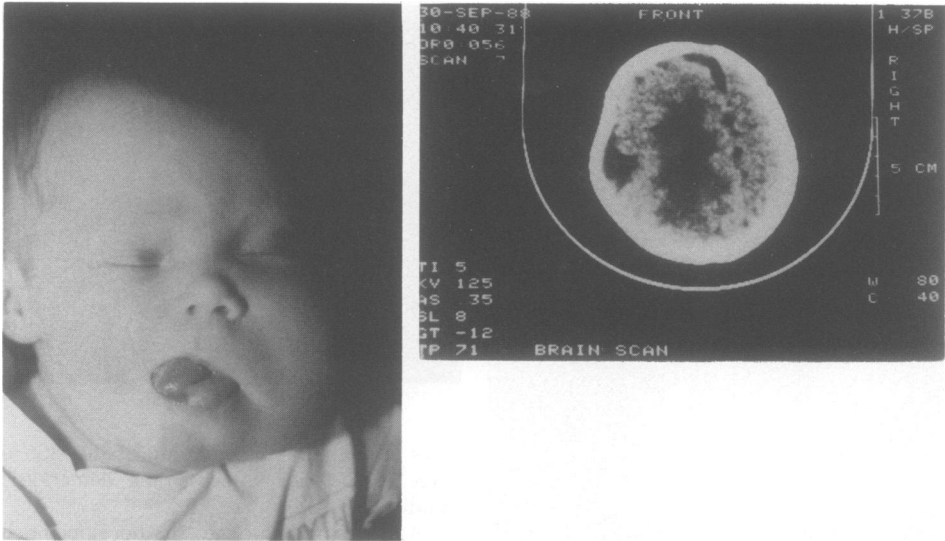


Figure 2 Case 2 newborn and CT scan at 3½ months.

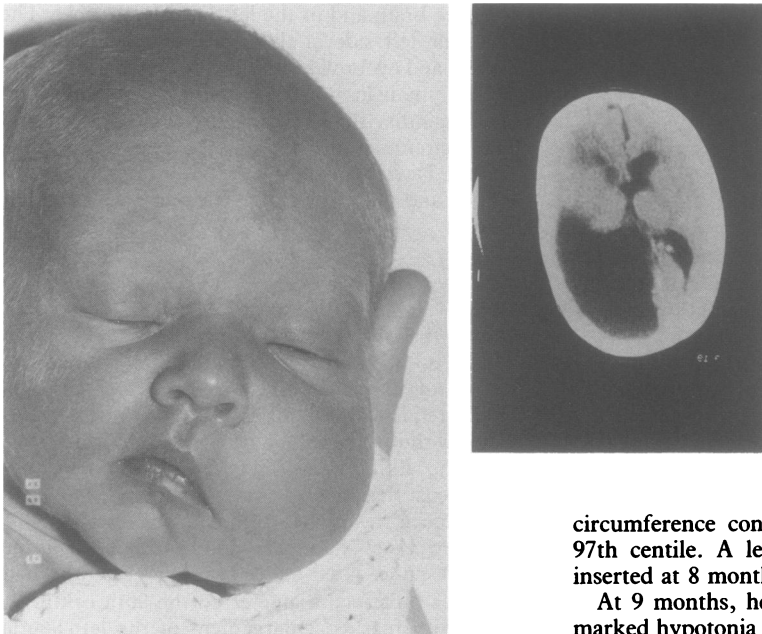


Figure 3 Case 3 newborn and CT scan at 3 months.

Twin 2 appeared entirely normal clinically and had normal cranial ultrasound findings. Blood group analysis suggested monozygosity.

At 3 months, he had poor head control and the head circumference was rising inappropriately. CT scan showed enlargement of the left side of the brain, with marked dilatation of the ipsilateral ventricle, particularly affecting the temporal horn (fig 3).

The rate of head growth slowed, but the head

circumference continued to deviate away from the 97th centile. A left ventriculoperitoneal shunt was inserted at 8 months of age.

At 9 months, he is developmentally delayed with marked hypotonia and failure to transfer objects, and is unable to sit without support. Visual attention is poor and he has a squint. Head control remains abnormal. The head circumference now appears to be rising parallel to the 97th centile.

Discussion

CLINICAL FINDINGS (TABLE 2)

Age at onset

Cranial hemihypertrophy was evident at birth in all

three patients, and in one patient (case 3), the biparietal diameter was on the 90th centile with unilateral ventricular dilatation by fetal ultrasonography from 16 weeks' gestation. The abnormal pattern of overgrowth is therefore evident from an early stage of development.

Physical findings

All tissue planes are affected by the hemihypertrophy, including cerebral substance, bone, soft tissue, and skin. There is a sharp demarcation in the midline, which is also seen in the tongue, dental ridges, and buccal mucosa. There is ventricular dilatation, particularly on the affected side, and evidence of cerebral hypertrophy.

Hyperpigmented and thickened skin changes were noted in case 2 at birth. A depigmented patch became evident in case 1 at the age of 6 months; no skin lesion has yet been found in case 3 at the age of 9 months.

Ventricular dilatation and IVH

Although two of our patients had evidence of perinatal intraventricular haemorrhage, it is unlikely that this was responsible for the ventricular dilatation. In case 1, the haemorrhage was in the contralateral ventricle and of a grade rarely causing ventriculomegaly. In case 3, the unilateral ventricular dilatation was already present at 16 weeks' gestation, five months before the observed haemorrhage.

Management of the ventricular dilatation

The rapidly enlarging heads and CT scan findings in all three children suggested unilateral hydrocephalus. However, in case 1, the insertion of a VP shunt did not influence the rate of head growth, and in case 3 the rate of head growth had slowed before the insertion of the VP shunt. It is premature to comment on the effect of the VP shunt on the subsequent pattern of head growth in case 3. It is possible that the early increase in head circumference represents hemimegalencephaly rather than raised intracranial pressure. Continued monitoring of the head circumferences in the three patients will clearly be important.

Neurodevelopment

All three patients showed delayed development. Cases 1 and 2 developed seizures at around 3 months of age, although in case 1 perinatal asphyxia may have been contributory.

hypertrophy since an early description by Meckel in 1822.⁸ Where the hemihypertrophy includes the cranium, mental retardation and seizures appear more common. Rowe's classification does not include a category for patients such as ours with a cranial hemihypertrophy and, unfortunately, many of the earlier clinical descriptions are incomplete and list 'facial' asymmetry as a feature rather than commenting on the rest of the head. Recent reports in oral and facial surgery publications, such as that of Horswell *et al.*,⁹ indicate that the hemifacial hypertrophy of Rowe⁴ does occur without cerebral involvement. In the light of the cases reported here, it seems likely that if hemihypertrophy extends to the cranial contents, producing a hemimegalencephaly,¹⁰ then neurodevelopmental prognosis may be poor, and the frequency of retardation may be higher than the 15 to 28% reported for congenital hemihypertrophy generally. Conversely, if hemimegalencephaly is absent, the prognosis for intellect may well be excellent. It is therefore important to consider the possibility of cranial hemihypertrophy (or hemimegalencephaly) in any infant with a suggestive appearance and arrange appropriate investigation (cranial ultrasound or CT scan).

CRANIAL HEMIHYPERTROPHY AND SYNDROME DIAGNOSIS

The facial appearances of our patients might be mimicked by several syndromes, between which there is considerable overlap. The absence of cavernous haemangiomas and other vascular anomalies excludes Klippel-Trenaunay-Weber syndrome, and coupled with the lack of enchondromata makes Mafucci syndrome equally unlikely.¹¹ In Bannayan syndrome,¹² the macrocephaly is usually symmetrical, and although hemihypertrophy can be a feature of Beckwith-Weidemann syndrome, there are no other physical characteristics to suggest this diagnosis.

Haberlund encephalocraniocutaneous lipomatosis (ECCL)¹³ and Proteus syndrome¹⁴ remain to be considered. Although one published case of the former bears a close facial resemblance to our cases,¹⁵ the CT scan findings are quite distinct. In ECCL, on the same side as the dermatological and osseous abnormalities is found a porencephalic cyst with cerebral atrophy.^{16, 17} At necropsy, cerebral and meningeal lipomatosis with micropolygyria have also been described.¹³ In our cases, however, the cerebral substance appears unilaterally hypertrophied, with ipsilateral dilatation of the lateral ventricle, and this corresponds more closely to the findings in those cases of Proteus syndrome where cranial hemihypertrophy or intellectual deficit and seizures were reported.¹⁸⁻²⁰ In this context, it is worth noting that although intellect is said to be usually normal in Proteus

HEMIHYPERTROPHY AND NEURODEVELOPMENT

There have been many reports of congenital hemi-

syndrome, in 29 cases where adequate details were reported,¹⁴⁻²⁵ eight had psychomotor delay and, of these, six had clinical cranial hemihypertrophy or CT scan findings similar to those in our patients. Other features in favour of Proteus syndrome are the depigmented and raised pigmented skin lesions of cases 1 and 2, although against this diagnosis is the absence of exostoses and of the characteristic gyrfiform palm or sole lesions. Our patients are probably still young enough that such lesions might yet develop.

The markedly disparate CT scan findings in Proteus syndrome and ECCL noted here are of some interest in the light of the suggestion by Wiedemann and Burgio²⁶ that ECCL may be "a more circumscribed form of Proteus syndrome".

AETIOLOGY

Familial cases of hemihypertrophy are virtually unknown⁵ and it is generally accepted that the condition is sporadic (unless the hemihypertrophy is a manifestation of a hereditary disorder, such as neurofibromatosis). Case 3 supports this impression, being one member of a discordant monozygotic twin pair.

It is known that asymmetrical growth may be a feature of mosaicism and it has been argued that Proteus syndrome may result from somatic mutation²⁷ giving rise to cell lines with abnormal growth patterns. Such a hypothesis would be attractive for hemihypertrophy generally, and to achieve regional hypertrophy affecting tissues of endodermal, mesodermal, and ectodermal origin, the mutation must presumably occur before the differentiation of these tissue layers. Case 3 showed abnormal growth from 16 weeks, but the mutation would have occurred long before this. In those cases of true complete hemihypertrophy, the change might have occurred at the two cell stage, and in cases of more localised hypertrophy, correspondingly later in development. The hypothesis of somatic mutation in a growth regulating gene may be supported by the association of Wilms' tumour with hemihypertrophy.²⁸

Whatever the aetiology, the three cases reported here serve to illustrate the poor neurodevelopmental prognosis associated with cranial hemihypertrophy, in distinction from facial hemihypertrophy, as defined by Rowe.⁴

Early diagnosis may help in providing more accurate prognosis and hence better counselling for the parents. This is particularly so as there may be a great desire for cosmetic plastic surgery, a treatment which should be deferred until the probable neurological outcome is clear. From the relatively limited published reports available, it seems likely that similar cerebral abnormalities may be present in those with intellectual deficit in both 'congenital hemihypertrophy' and in

Proteus syndrome. Further studies are needed to clarify this and the nature of the abnormal growth that is the hallmark of these patients.

- 1 Gorlin RJ. Proteus syndrome. *J Clin Dysmorphol* 1984;2:8-9.
- 2 Viljoen DL, Klippel-Trenaunay-Weber syndrome (angio-osteohypertrophy syndrome). *J Med Genet* 1988;25:250-2.
- 3 Wiedemann HR, Grosse KR, Dibbern H. Exomphalos-macroglossia-gigantism syndrome. In: *An atlas of characteristic syndromes*. London: Wolfe Medical Publications, 1986:82-3.
- 4 Rowe NH. Hemifacial hypertrophy: review of the literature and addition of four cases. *Oral Surg* 1962;15:572-87.
- 5 Gorlin RJ, Meskin LH. Congenital hemihypertrophy: review of the literature and report of a case with special emphasis on oral manifestations. *J Pediatr* 1962;61:870-9.
- 6 Ringrose RE, Jabbour JT, Keele DK. Hemihypertrophy. *Pediatrics* 1965;36:434-48.
- 7 Morris JV, MacGillivray RC. Mental defect and hemihypertrophy. *Am J Ment Defic* 1955;59:645-51.
- 8 Meckel JF. *Ueber die seitliche Asymmetrie in tierischen Korper; Anatomische physiologisches Beobachtungen und Untersuchungen*. Halle: Renger, 1822:147.
- 9 Horswell BB, Holmes AD, Barrett JS, Hookey SR. Primary hemihypertrophy of the face: review and report of two cases. *J Oral Maxillofac Surg* 1987;45:217-22.
- 10 Kalifa GL, Chiron C, Sellier N, et al. Hemimegalencephaly: MR imaging in five children. *Radiology* 1987;165:29-33.
- 11 Beighton P. *Inherited disorders of the skeleton*. Edinburgh: Churchill Livingstone, 1988:118-9.
- 12 Bannayan GA. Lipomatosis, angiomatosis and macrencephalia. A previously undescribed congenital syndrome. *Arch Pathol* 1971;92:1-5.
- 13 Haberland C, Perou M. Encephalocraniocutaneous lipomatosis. *Arch Neurol* 1970;22:144-55.
- 14 Wiedemann HR, Burgio GR, Aldenhoff P, Kinze J, Kaufmann HJ, Schirg E. The Proteus syndrome. *Eur J Pediatr* 1983;140:5-12.
- 15 Wiedemann HR. Syndrome of encephalocraniocutaneous lipomatosis. In: *An atlas of characteristic syndromes*. London: Wolfe Medical Publications, 1986:234-5.
- 16 Fisham MA, Chang CSC, Miller JE. Encephalocraniocutaneous lipomatosis. *Pediatrics* 1978;61:580-2.
- 17 Sanchez NP, Rhodes AR, Mandell F, Mihm MC. Encephalocraniocutaneous lipomatosis: a new neurocutaneous syndrome. *Br J Dermatol* 1981;104:89-96.
- 18 Tibbles JAR, Cohen MM. The proteus syndrome: the Elephant Man diagnosed. *Br Med J* 1986;293:683-5.
- 19 Malamitsi-Puchner A, Kitsioui S, Bartsocas CS. Brief clinical report. Severe Proteus syndrome in an 18 month-old boy. *Am J Med Genet* 1987;27:119-25.
- 20 Costa T, Fitch N, Azouz EM. Proteus syndrome: report of two cases with pelvic lipomatosis. *Pediatrics* 1985;76:984-9.
- 21 Temtamy SA, Rogers JG. Macroductyly, hemihypertrophy, and connective tissue nevi: report of a new syndrome and review of the literature. *J Pediatr* 1976;89:924-7.
- 22 Cohen MM, Hayden PW. A newly recognised hamartomatous syndrome. In: O'Donnell JJ, Hall BD, eds. *Penetrance and variability in malformation syndromes*. New York: Alan R Liss for The National Foundation—March of Dimes. Birth Defects 1979;XV(SB):291-6.
- 23 Mucke J, Willgerodt H, Kunzel R, Brock D. Variability in the Proteus syndrome: report of an affected child with progressive lipomatosis. *Eur J Pediatr* 1985;143:320-3.
- 24 Viljoen DL, Nelson MM, de Jong G, Beighton P. Proteus syndrome in Southern Africa: natural history and clinical manifestations in six individuals. *Am J Med Genet* 1987;27:87-97.
- 25 Clark RD, Donnai D, Rogers J, Cooper J, Baraitser M. Proteus syndrome: an expanded phenotype. *Am J Med Genet* 1987;27:99-117.
- 26 Wiedemann HR, Burgio GR. Encephalocraniocutaneous lipomatosis and Proteus syndrome. *Am J Med Genet* 1986;25:403-4.
- 27 Happle R. Cutaneous manifestations of lethal genes. *Hum Genet* 1986;72:280.
- 28 Miller RW, Fraumeni JF, Manning MD. Association of Wilms' tumour with aniridia, hemihypertrophy and other congenital malformations. *N Engl J Med* 1964;270:922-7.