

---

## Syndrome of the month

---

Edited by D Donnai and R Winter

# Focal dermal hypoplasia (Goltz syndrome)

I K Temple, P MacDowall, M Baraitser, D J Atherton

Goltz *et al*<sup>1</sup> reported three females in 1962 with a mesoectodermal condition which they called focal dermal hypoplasia (FDH); this rare, multisystem condition is now often referred to as Goltz syndrome. In an extensive review of published reports by Gorlin *et al*<sup>2</sup> in 1963, 11 previously described cases were found, the first in 1921 by Jessner.<sup>3</sup> Although the cutaneous features predominate in most reports and have given the condition its name, characteristic abnormalities are also frequently present in the nails, hair, skeletal system, and eyes.

A total of 88% of reported cases has been female<sup>4</sup> and X linked dominant inheritance with lethality in males has been proposed as the likely mode of inheritance.<sup>5</sup>

### Incidence

Approximately 175 cases of FDH have now been reported. The clinical features are now well recognised and single female cases are no longer reported. The incidence is, however, likely to be underestimated as mildly affected subjects may go unrecognised. Indeed, when reviewing familial cases, none of the more mildly affected relatives had been diagnosed correctly before the birth of a more severely affected child.

---

Department of Clinical Genetics, Hospitals for Sick Children, Great Ormond Street, London WC1N 3JH.  
I K Temple, M Baraitser

Department of Paediatric Dermatology, Hospitals for Sick Children, Great Ormond Street, London WC1N 3JH.  
P MacDowall, D J Atherton

Correspondence to Dr Temple, Department of Clinical Genetics, Institute of Child Health, 30 Guilford Street, London WC1N 1EH.

---

### Clinical aspects

The clinical features have been well reviewed by Goltz *et al*<sup>6</sup> and Warburg<sup>7</sup> in 1970 and by Hall and Terezhalmay<sup>4</sup> in 1984, who described the findings reported in 125 published cases.

A feature of this disorder is the diversity of organ involvement and variation in severity. Findings vary from easily overlooked mild skin atrophy to severe limb deformity and life threatening complications. Skin involvement has been present in all but two of reported cases,<sup>8</sup> and is usually regarded as essential for the diagnosis. It remains possible that undiagnosed gene carriers occur with non-cutaneous features alone (table).

### SKIN

Typical cutaneous abnormalities are almost invariably present from birth. Initially, the most prominent type of lesion comprises pink or red, angular, atrophic macules, which may be slightly raised or depressed, and which often show reticulate grouping (fig 1). The lesions may be a few millimetres or several centimetres across. Occasionally they are blistered or eroded at birth,<sup>8,9</sup> and, in such cases, they have occasionally been described as cutis aplasia. Telangiectasia is commonly present. In racially pigmented skin, the lesions may be hypo- or hyperpigmented rather than erythematous. These lesions generally have a rather obvious and highly characteristic linear and asymmetrical distribution, and they may be found on any part of the body. The linear patterning follows Blaschko's lines,<sup>10</sup> and is often most prominent on the legs, especially the thighs, on the forearms, and on the cheeks where single lines often radiate from the angle of the mouth (figs 2 and 3). The intensity of the erythema tends to fade with age, so that the atrophic areas eventually appear white.

Soft, pinkish-yellow to brown saccular nodules provide the second characteristic type of skin lesion in FDH; these are the so called 'fat herniations' (fig 4).

Features in reported cases of focal dermal hypoplasia, comparing reviews compiled by Goltz *et al*<sup>6</sup> in 1970, Hall and Terezhalmay<sup>4</sup> in 1984, and the present review of 91 reported cases (which includes patients from the 1970 and 1984 reviews).

Features	Goltz <i>et al</i> <sup>6</sup> (1970) (n=41) (%)	Hall and Terezhalmay <sup>4</sup> (1984) (n=125) (%)	Review of published reports (1989) (n=91) (%)
Female	94	88	85
Skin atrophy	84	62	86
Pigmentation anomalies	51	51	72
Fat herniations	34	46	63
Papillomata	—	44	50
Nail dystrophy	37	41	54
Alopecia: complete or partial	42	30	26
Teeth: enamel defects	17	17	33
Syndactyly	68	60	71
Hypoplasia of digits	46	34	38
Osteopathia striata	—	24	20
Asymmetry of body	24	31	31
Eye coloboma	24	14	32
Microphthalmia	10	12	20
Hearing impairment	5	8	11
Short stature	—	—	14
Mental retardation	7	4	15



Figure 1 Linear erythematous lesions in the popliteal fossa of a 10 year old girl with FDH.




Figure 2 A 10 year old girl with typical FDH. Note the erythematous streaks radiating from the angle of the mouth. In addition there is a right sided coloboma of the iris. The left eye is a prosthesis. Note the broad nasal tip.

These can occur anywhere, but they are perhaps most commonly found on the limbs, particularly in the popliteal and antecubital fossae. They may appear at any time during childhood.

The third characteristic type of skin lesion is a raspberry-like papilloma which can appear at any time

during the patient's life. Such lesions may be multiple. They occur most frequently at junctions between mucosa and skin, on or around the lips, in the vulval and perianal areas, and around the eyes, but they may be seen at other sites, including the ears (both on the pinnae and in the middle ears), the fingers and toes,

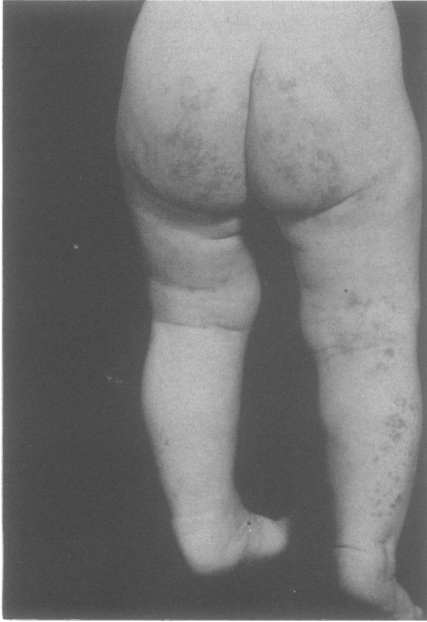

Figure 3 An 18 month old girl with FDH, with asymmetrical linear lesions following the lines of Blaschko.

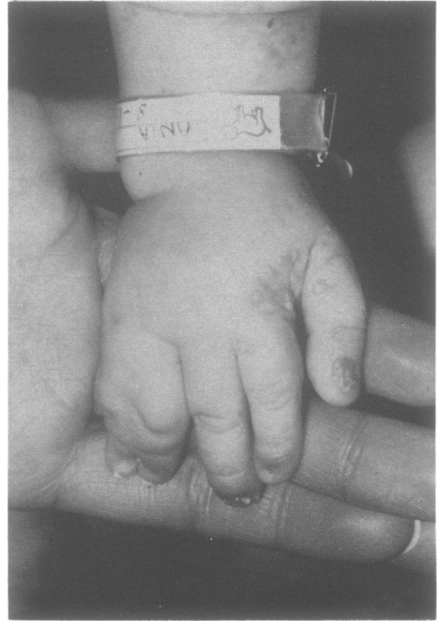

Figure 5 Nail dystrophy and syndactyly of digits 4 and 5.

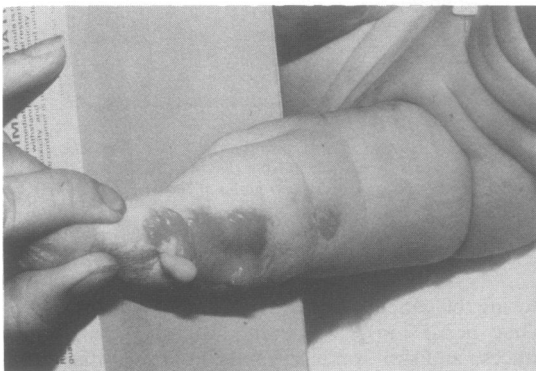the groin and umbilicus, inside the mouth (on the gums and at the base of the tongue), and even in the oesophagus.<sup>11</sup>

In addition, there is a tendency for mild generalised xerosis associated with a degree of pruritus, which can be a troublesome symptom, and some patients are photosensitive.

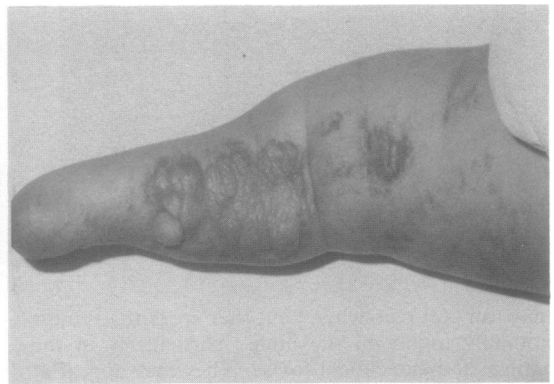Histology of the first two types of skin lesion shows marked reduction in the thickness of the dermis, with attenuation of the collagen fibres. Fat cells extend

virtually to the epidermis, interspersed among which may be strands of dermal connective tissue.<sup>6, 12</sup> The epidermis appears normal.

Electron microscopy shows numerous fine filamentous structures in the dermis, believed to represent immature collagen,<sup>13</sup> and it is possible that while collagen synthesis may occur at a normal rate,<sup>14</sup> the collagen does not form mature bundles in the normal way. Multilocular fat cells have been seen ultrastructurally in the lesional fat, and these are



(a)



(b)

Figure 4 (a) Lipomatous nodules. The areas were erythematous with glistening lesions soon after birth. (b) Appearance by 4 months.

considered to be an immature form of adipocyte.<sup>15</sup> There is debate as to whether the defect is primarily an atrophy of the dermis, with secondary fat 'herniation', or a complex developmental abnormality of connective tissue causing both dermal hypoplasia and the development of fat hamartomata.<sup>12</sup> The frequent presence of dermal elements, including collagen and elastin fibres, below the superficially situated fat, and the ultrastructural demonstration of immature adipocytes within this fat, tend to support the latter view.

The histological features of the raspberry-like papillomata closely resemble those of the angiofibromata of tuberous sclerosis and those of the so called solitary fibrous papule of the nose, with acanthosis and papillomatosis of the epidermis, and dilated capillaries in the dermal core.

#### HAIR

The hair is frequently somewhat sparse and brittle. Localised areas of absence of hair are not uncommon in the scalp and in the pubic area.

#### NAIL CHANGES

Dystrophy or onychia occurs when nails are contiguous with linear skin lesions (fig 5).

#### SKELETAL SYSTEM

Findings in the skeletal system are variable and usually asymmetrical. The hands and feet are affected in 60 to 70% of reported cases. Abnormalities include syndactyly, absence or hypoplasia of digits, also ectrodactyly and polydactyly, in any combination. The spectrum includes absence of the whole or part of an extremity. A 'lobster claw' type of deformity is perhaps particularly characteristic (fig 6). Asymmetry in the size and shape of the face, trunk, or limbs has

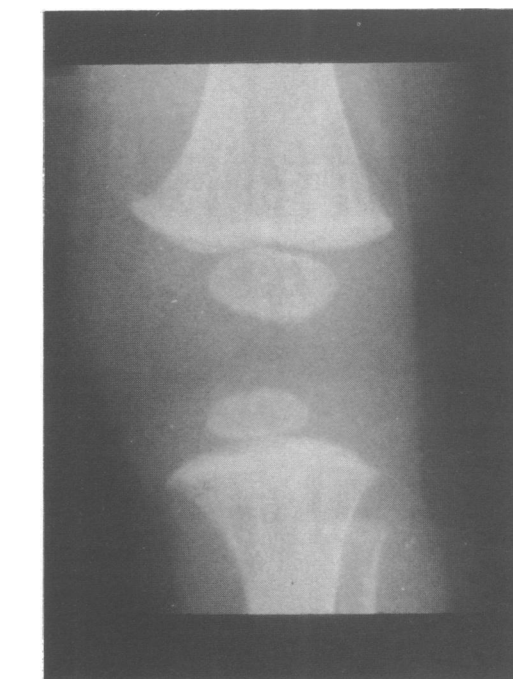

Figure 7 Osteopathia striata in the metaphyses of the tibia and femur at the knee of a 1 year old patient with FDH.

been reported in 30% of cases, and scoliosis in 15 to 20%.

X rays can be helpful. In 1972, Larregue *et al*<sup>15</sup> noted longitudinal striations in the metaphyses of long bones ('osteopathia striata') in nine patients (fig 7). This finding is not pathognomonic, but is found in approximately 20% of gene carriers and can be a useful feature, particularly if the condition is suspected in minimally affected subjects. Vertebral anomalies

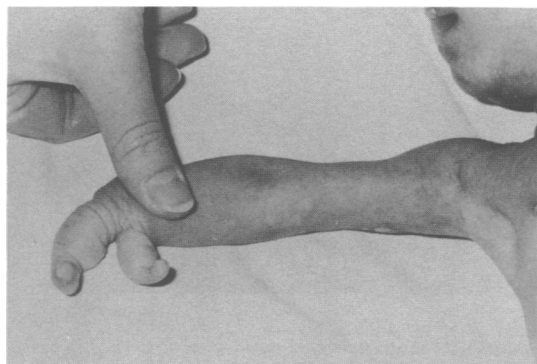

Figure 6 Typical 'lobster claw' deformity of the right hand.

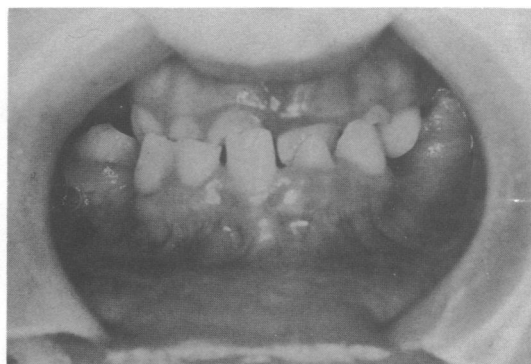

Figure 8 Irregular teeth in a 10 year old girl with FDH.

including spina bifida occulta and clavicular dysplasia are additional findings.

#### TEETH

Anomalies of the teeth have been reported to occur in about 40% of patients. Enamel defects with caries are frequent. Anodontia, dental hypoplasia, delayed eruption, irregular spacing, malocclusion, and notched incisors occur (fig 8). The dental findings are well reviewed by Ureles and Needleman.<sup>16</sup> They noted that there may be palatal striations similar to the skin lesions. Less frequent features are cleft lip, cleft palate, notching of the alveolar ridge, and tongue clefts.

#### EYE

Ocular anomalies have been present in approximately 20% of reported cases, and may make a major contribution to the handicap associated with this condition. Classically, defects affect the anterior chamber and include coloboma of the iris and aniridia, but more severe involvement has included choroidoretinal colobomata, microphthalmos, and anophthalmos (fig 9). Strabismus is a common finding. Eye involvement tends to be asymmetrical. Despite quite severe abnormalities visual acuity is often remarkably well maintained. Epiphora is a tiresome problem described in several patients.

#### FACE

The facial features are typical and are illustrated in fig 10. The ears are thin and protruding, often simple, low set, and sometimes asymmetrical (fig 11). The nose has a narrow bridge and a broad nasal tip, sometimes with a unilateral notch of the ala nasi. The chin is pointed. Asymmetry of the face with mild hemihypertrophy has been described.

#### OTHER FEATURES

##### *Renal anomalies*

Structural defects including horseshoe kidney<sup>6</sup> and mild cystic dysplasia not picked up by renal ultrasound can occur.

##### *Herniae*

Exomphalos is a well recognised complication, which may be related to abdominal skin defects. Similarly, inguinal and epigastric herniae and other herniae at the sites of cutaneous hypoplasia can occur (fig 12). Hiatus herniae are an important cause of failure to thrive in some patients.

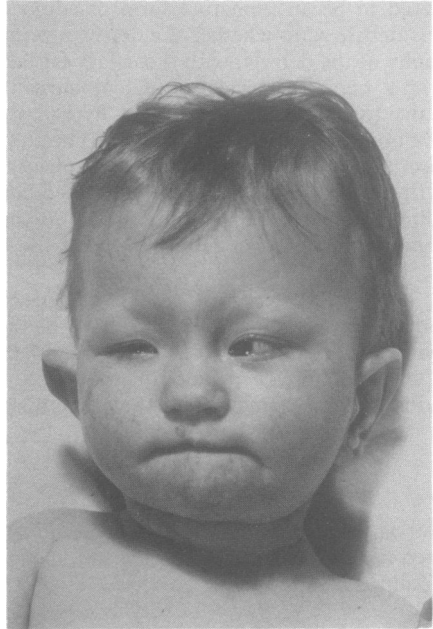


Figure 9 There is bilateral microphthalmia, more marked on the right. In addition the ear deformity is characteristic.

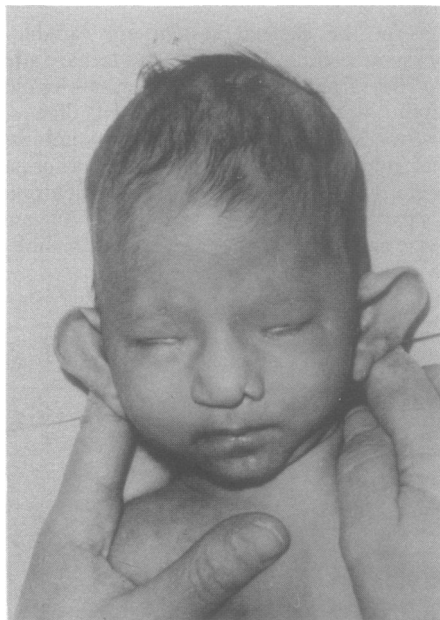

Figure 10 Typical facial features of focal dermal hypoplasia in a 6 week old baby including the broad nasal tip with a notch of the ala nasi on the left. The ears are simple and low set. There is bilateral microphthalmos.

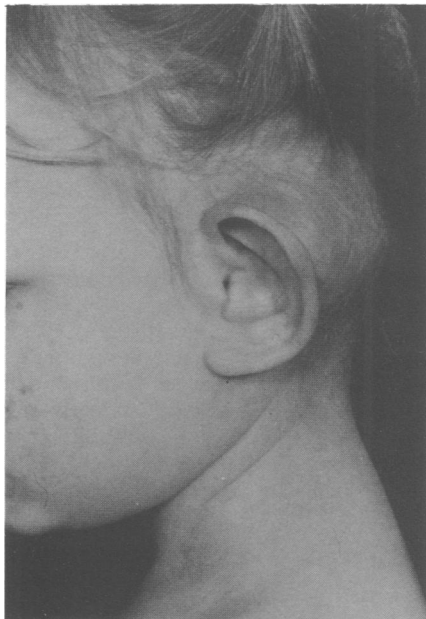


Figure 11 The pinnae are thin and protrude.

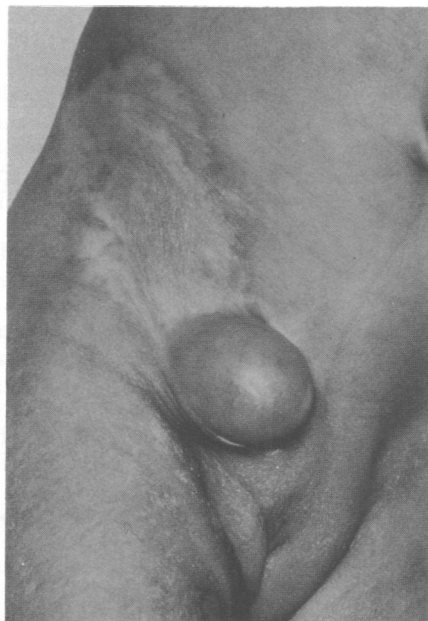

Figure 12 Bowel herniation requiring surgery in a hypoplastic area in the lower abdomen of a 6 week old girl with FDH.

#### Deafness

Combined sensorineural and conductive hearing loss has been described in about 10% of reported cases. Cochlear dysplasia shown by CT scan can occur.

#### Infections

A number of patients have been described with recurrent tonsillitis requiring tonsillectomy. Recurrent respiratory infections, conjunctivitis, otitis media, and urinary tract infections are a management problem in some patients. No dysfunction of immunity has been described, but few have been extensively investigated.

#### Intelligence

IQ is often normal. Approximately 15% of reported cases are mentally retarded but as these represent the most severely affected cases, this may be an overestimate. Microcephaly is a good indicator of subsequent poor intellectual outcome. IQ can be underestimated if sensory deprivation is not appreciated.

#### Natural history and management

Several of the more severely affected children fail to thrive. Problems such as gastro-oesophageal reflux and urinary tract infection must be excluded, but in many cases there is no obvious explanation. Short stature in combination with a thin habitus is a feature of many patients.

Skin lesions are not a major therapeutic problem as the redness of early lesions tends to fade with age, but facial lesions may be a cosmetic worry. Pruritus can be troublesome and should not be overlooked. Papillomata, particularly around the mouth, may be unsightly and can be excised or ablated with cautery or cryotherapy; unfortunately they may recur.

Orthopaedic and plastic surgical advice should be sought early with regard to limb deformities. Amputation and artificial limbs may prove the best option in some cases.

Careful visual assessment is needed before enucleation of an obviously small, deformed eye, as visual acuity can be surprisingly good.

Dental management is important and education regarding caries is imperative.

Although developmental delay is more likely in more severely affected children, the degree cannot accurately be predicted and is independent of any of the other features of FDH.

Precise prenatal diagnosis is not available, but skeletal abnormalities can be sought by careful ultrasound examination. However, the clinical manifestations of the disorder are so variable that prognosis regarding intellectual development and vision is difficult to predict, whether such skeletal abnormalities are present or not.

As with many multisystem conditions, families often find it easier if one physician takes overall responsibility and coordinates the involvement of the various specialities. The majority of patients can lead

a normal life. Where reported, menses have occurred at a normal age.

### Differential diagnosis

#### INCONTINENTIA PIGMENTI

A history of cutaneous vesiculation and verrucous lesions, and persisting 'splashed' pigmentation differ from the red linear areas of skin atrophy in FDH. Skin biopsy is highly characteristic in the vesicular and verrucous phases, and shows pigmentary incontinence in the pigmented lesions. Eye findings most characteristically involve the posterior chamber, but microphthalmos is the end stage of any severe eye defect and this can cause confusion. A higher proportion of patients have convulsions and neurological deficit.

#### DELETION OF Xp22.2

Four patients have been described with microphthalmos, acute weeping linear skin lesions of the face and neck that healed to become hyperpigmented streaks, and normal intelligence.<sup>17 18</sup> The skeletal system in these patients was normal, other than mild skin syndactyly, as were teeth and hair. All were shown to have a deletion of the short arm of the X chromosome, involving band Xp22.2.

#### ADAMS-OLIVER SYNDROME

This variable autosomal dominant condition comprises an association of scalp and skull bone aplasia with distal limb reductions. The skin and eyes are normal.

#### ROTHMUND-THOMSON SYNDROME

Skin findings include atrophy, telangiectasia, and pigmentary disturbance, but lesions do not appear until at least 3 months of age, and are not linear. Skin biopsy can differentiate the two conditions, as in Rothmund-Thomson syndrome epidermal changes predominate. The condition is autosomal recessive.

#### NAEVUS LIPOMATODES SUPERFICIALIS

##### (HOFFMANN-ZURHELLE)

This is a developmental abnormality of the skin comprising localised groups of soft fleshy nodules, most commonly on the lower trunk, and generally present at birth. Histologically they are similar to the lipomatous nodules of FDH, but none of the other characteristic abnormalities seen in FDH will be present.

#### APLASIA CUTIS CONGENITA

This is a disorder in which areas of skin are absent at

birth. Such lesions may closely resemble those seen in focal dermal hypoplasia. However, the number of lesions is usually small, being solitary in the majority of cases, and the other abnormalities seen in FDH will be absent.

### Inheritance

About 95% of all reported cases are sporadic,<sup>14</sup> but the condition is thought to be genetic as other affected members have been found in some families.<sup>1 19-25</sup> To explain the marked preponderance of females, X linked dominant inheritance with lethality in hemizygous males has been proposed. A high incidence of miscarriage in some families has been reported,<sup>6</sup> and there has been no reported case of transmission from father to son. A high mutation rate would be expected in this type of inheritance, which would at least partially account for the high observed rate of sporadic cases. Many authors support this mode of inheritance,<sup>5 7 23 26 27</sup> suggesting that random X inactivation results in functional X mosaicism, accounting for the asymmetrical and variable findings in skin, bones, and soft tissues. To substantiate the hypothesis, more familial cases need to be described and the sib and offspring numbers analysed.

Rare male cases are found in most of the more well established X linked dominant conditions. FDH in males could reflect half chromatid mutations. If the mutation occurred early enough in the developing embryo, the gonads would also be involved and this might explain reports of father to daughter transmission.<sup>22</sup> In keeping with this hypothesis, reported affected males have always been the first affected person in their families.

It seems surprising that more cases have not been reported describing the offspring of known patients with FDH. In non-familial female cases, there remains a possibility that the mutation is a somatic X mutation resulting in a mosaic situation where the offspring risks depend on whether the ova carry the mutation.

The majority of karyotypes reported in lymphocyte cultures from affected subjects are normal. Zuffardi *et al*<sup>28</sup> reported an affected girl with a deletion of 9q (9q33-qter) owing to a balanced maternal translocation (4;9)(q35;q32). No skin chromosome karyotypes have been recorded. So few families have been described that no linkage data are available.

We would like to thank the families for helping us with this article.

1 Goltz RW, Peterson WC, Gorlin RJ, *et al*. Focal dermal hypoplasia. *Arch Dermatol* 1962;86:708-17.

2 Gorlin RJ, Meskin LH, Peterson WC, *et al*. Focal dermal hypoplasia syndrome. *Acta Derm Venereol (Stockh)* 1963;43:421-40.

- 3 Jessner M. Breslau dermatologische Vereinigung. *Arch Dermatol Syph* 1921;133:48.
- 4 Hall EH, Terezhalmay GT. Focal dermal hypoplasia syndrome, case report and literature review. *J Am Acad Dermatol* 1983;9:443-51.
- 5 Wettke R, Kanter G. X-linked dominant diseases with lethality in hemizygous males. *Hum Genet* 1983;64:1-23.
- 6 Goltz RW, Henderson RR, Hitch JM, et al. Focal dermal hypoplasia syndrome. *Arch Dermatol* 1970;101:1-11.
- 7 Warburg M. Focal dermal hypoplasia. *Acta Ophthalmol* 1970;48:525-36.
- 8 Ayme S, Fraser FC. Possible examples of the Goltz syndrome (focal dermal hypoplasia) without linear areas of skin hypoplasia. *Birth Defects* 1982;18(3B):59-65.
- 9 Daly JF, Vermont R. Focal dermal hypoplasia. *Cutis* 1968;4:1354-9.
- 10 Jackson R. The lines of Blaschko. *Br J Dermatol* 1976;95:349-59.
- 11 Brinson RB, Schuman BM, Mills LR, et al. Multiple squamous papillomas of the oesophagus associated with Goltz syndrome. *Am J Gastroenterol* 1987;82:1177-9.
- 12 Howell JB. Nevus angioliomatosis versus focal dermal hypoplasia. *Arch Dermatol* 1969;92:238-48.
- 13 Tsuji T. Focal dermal hypoplasia: an electron microscopic study of skin lesions. *J Cutan Pathol* 1982;9:271-81.
- 14 Uitto J, Bauer EA, Santa-Cruz DJ, et al. Focal dermal hypoplasia: abnormal growth characteristics of skin fibroblasts. *J Invest Dermatol* 1980;75:170-5.
- 15 Larregue M, Maroteaux P, Michel Y, et al. L'osteopathie striée, symptôme radiologique de l'hypoplasie dermique en aires. *Ann Radiol (Paris)* 1972;15:287-95.
- 16 Ureles SD, Needleman HL. Focal dermal hypoplasia syndrome (Goltz syndrome): the first dental case report. *Pediatr Dentistry* 1986;8:239-44.
- 17 Al-Gazali LI, Mueller RF, Caine A, et al. An XX male and two t(X;Y) females with linear skin defects and congenital microphthalmia: a new syndrome at Xp22.3. *J Med Genet* 1988;25:638-9A.
- 18 Temple IK, Hurst JA, Hing S, Butler L, Baraitser M. De novo deletion of Xp22.2-pter in a female with linear skin lesions of the face and neck, microphthalmia, and anterior chamber eye anomalies. *J Med Genet* 1990;27:56-8.
- 19 Fryns JP, Dhondt F, Lindemans L, et al. Focal dermal hypoplasia (Goltz syndrome) in a male. *Acta Paediatr Belg* 1978;31:37-9.
- 20 Wodnainsky P. Über die formen der kongenitalen poikilodermie. *Arch Klin Exp Dermatol* 1957;205:331-42.
- 21 Atherton DJ, Hall M. Focal dermal hypoplasia syndrome. *Clin Exp Dermatol* 1979;5:249-52.
- 22 Burgdorf WHC, Dick GF, Milton D, et al. Focal dermal hypoplasia in a father and daughter. *J Am Acad Dermatol* 1981;4:273-7.
- 23 Ruiz-Maldonado R, Carnevale A, Tamayo L, et al. Focal dermal hypoplasia. *Clin Genet* 1974;6:36-45.
- 24 Weschler CA, Papa CM, Habermann F, et al. Variable expression in focal dermal hypoplasia. *Am J Dis Child* 1988;142:297-300.
- 25 Champion RH. Focal dermal hypoplasia. *Br J Dermatol* 1975;31(suppl 2):70-1.
- 26 Fjellner BO. Focal dermal hypoplasia in a 46XY male. *J Dermatol* 1979;18:812-5.
- 27 Happle R, Lenz W. Striations of bones in focal dermal hypoplasia: manifestation of functional mosaicism? *Br J Dermatol* 1977;96:133-8.
- 28 Zuffardi O, Maraschio P, Tupler R, et al. Region 9q33-qter includes a locus for Goltz-like syndrome but not for AK<sub>1</sub> and nail-patella syndrome. *Clin Genet* 1988;34:423A.