

# Miller syndrome (postaxial acrofacial dysostosis): further evidence for autosomal recessive inheritance and expansion of the phenotype

A L Ogilvy-Stuart, A C Parsons

## Abstract

**A sibship with postaxial acrofacial dysostosis syndrome (Miller syndrome) is reported. In addition to the characteristic facial and limb defects, previously undescribed anomalies, including midgut malrotation, gastric volvulus, and renal anomalies, are recorded.**

Miller syndrome is a rare, well defined malformation syndrome. The craniofacial abnormalities are similar to those of the Treacher Collins syndrome. The limb defects predominantly involve the postaxial ray, with a wide range of severity, and to a lesser extent the preaxial ray.

The syndrome was first described as a complete clinical entity by Miller *et al*<sup>1</sup> in 1979. They described four previously published cases, one with additional follow up information, in addition to two further cases. Since then, eight further cases have been described<sup>2-6</sup> and we have details of other cases from a personal communication.

Recurrence of the syndrome in a sib of the opposite sex with unaffected parents reported by Fineman<sup>2</sup> in 1981 has implicated autosomal recessive inheritance for this disorder. In one of the cases the parents were distantly related (fifth cousins).

We report similarly affected sibs who, in addition to the classic features of Miller syndrome, have midgut malrotation, gastric volvulus, and renal tract anomalies, thus lending weight to an autosomal recessive mode of inheritance and expanding the reported features of the syndrome.

---

**Department of Paediatrics, Taranaki Base Hospital, New Plymouth, New Zealand.**  
A L Ogilvy-Stuart, A C Parsons

Correspondence to Dr Ogilvy-Stuart, Christie Hospital and Holt Radium Institute, Wilmslow Road, Withington, Manchester M20 9BX.

---

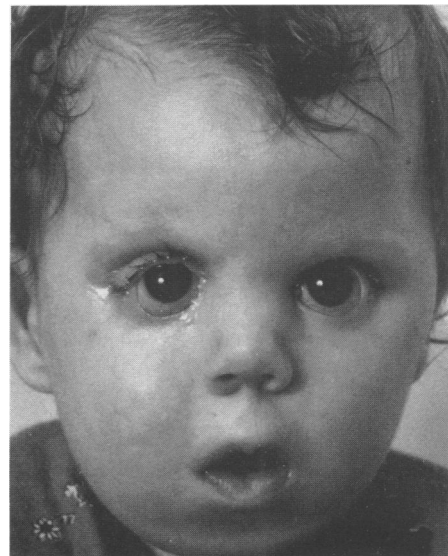
Received for publication 17 December 1990.  
Revised version accepted for publication 19 February 1991.

## Case reports

### CASE 1

This girl is the second daughter born to unrelated Caucasian parents. The first child is apparently entirely normal. At the time of delivery the mother was 26 years old and the father 29 years. The pregnancy was uncomplicated and no drugs were taken. She was born at term by lower section caesarian section for failure to progress. The Apgar score at one and five minutes was 8. No resuscitation was required. At birth her weight was 3160 g (25th centile), length 46 cm (less than the 10th centile), and the head circumference 34 cm (25th centile).

The following facial abnormalities were noted: micrognathia, malar hypoplasia, small shallow orbits with bilateral proptosis, downward slanting palpebral fissures, colobomas of both upper eyelids with incomplete closure, corneal exposure, and lower lid deficiency with ectropion (fig 1a). There was a cleft



*Figure 1a Case 1. Facial features after frontal advancement; note lower lid ectropion.*

palate. The ears were hypoplastic with middle ear hypoplasia.

Both upper limbs were shortened with symmetrical absence of the fifth digits (fig 1b). Radiographs at 4 years of age showed shortening of the left humerus and marked shortening and modelling of the radius and ulna bilaterally. Only four rays were present in the hands with modelling deformities of the metacarpals (fig 1c).

The lower limbs were of normal length. There were four rays in the right foot with syndactyly of the big and second toes. There were three rays in the left foot, with a tiny accessory bone present laterally (fig 1d).

Accessory nipples were present bilaterally. The spleen was easily palpable. Chromosome karyotype was 46,XX. Severe hearing loss at mid and high frequencies was suggested by brainstem evoked responses at 2 weeks and 6 months of age. A conduction loss and normal inner ear function was indicated at 13 months by air conduction testing.

A number of surgical procedures (tarsorrhaphies, cleft palate repair, grommet insertion, eyelid grafting, and frontal advancement) were performed in the first 17 months of life by a multidisciplinary surgical team to improve both appearance and function. During the first, difficult, anaesthetic, previously undiagnosed choanal atresia was discovered.<sup>7</sup>

At 3 years of age she was admitted with symptoms of gastrointestinal obstruction. Abdominal radiographs showed gross distension of the stomach (fig 1e). A barium meal the next day showed only mild gastric distension and active peristaltic waves in the

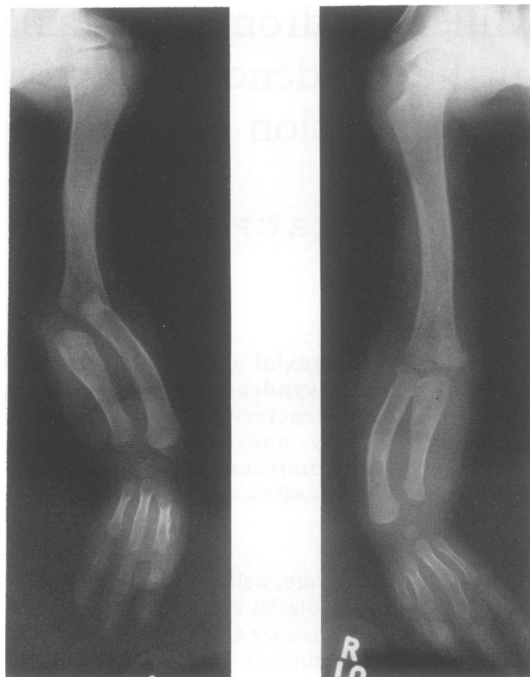

Figure 1c X ray of both upper limbs showing hypoplastic ulna and bowing of the radius bilaterally.

proximal small bowel. She settled on conservative treatment. The spleen was readily palpable.

Two weeks later she developed further symptoms of gastrointestinal obstruction. Gastroscopy showed a large atonic stomach and she proceeded to laparotomy. The operative findings were a large mobile

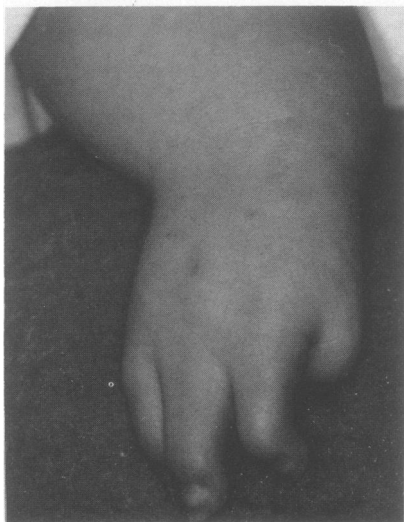

Figure 1b Hand and wrist; note absent fifth ray.

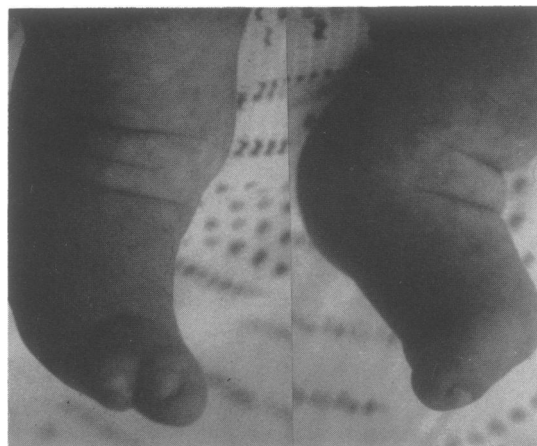

Figure 1d Both feet; note absent digits and syndactyly.

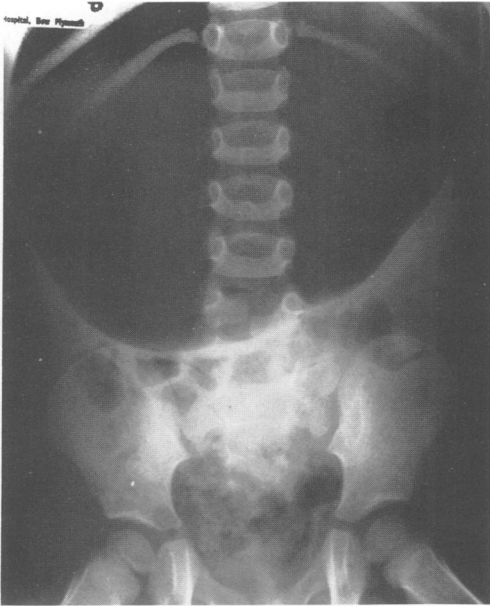

Figure 1e Abdominal x ray showing gastric dilatation owing to torsion.

stomach, not attached to the diaphragm. The spleen was attached to the greater curvature of the stomach but had no attachments to the kidney or diaphragm. There was malrotation of the fourth part of the duodenum. Ladd's bands were divided, and the small bowel made to lie on the right side of the peritoneal cavity.

She has been managed by a multidisciplinary team including the development therapist. Her development has been delayed, mainly as a result of her physical handicaps rather than intellectual impairment. At 9 months she was performing at a 7 month level, and at 2 years she was walking independently, but unable to stand still because of poor balance on narrow based feet with absent toes. She had good fine motor skills and an unorthodox pincer grip using two fingers. Speech improved in parallel with her hearing, after palatal repair.

Now at 4 years of age she attends kindergarten and is on a level with her peers. Her vision is normal and hearing is good with aids. She has excellent understanding of language but is dysphonic.

#### CASE 2

This boy, the younger brother of case 1, was born at 39 weeks' gestation by elective caesarian section. The pregnancy was uneventful. The parents had received genetic counselling and been given a recurrence risk of 25%.

Ultrasound scans at 16, 29, and 33 weeks' gestation failed to show any abnormalities. The humeral length of 4.05 cm was not disproportionate in relation to the femoral length of 5.75 cm at the 29 week scan.

His condition at birth was good. Birth weight was 3330 g (40th centile), length 47 cm (less than 10th centile), and head circumference 34.5 cm (25th centile). It was immediately apparent that he had Miller syndrome. The features were severe micrognathia, malar hypoplasia, downward slanting palpebral fissures with colobomas of the upper eyelids, and deficiencies of the lower lids. The soft palate was cleft, and the ears were cup shaped, but the middle ear was normal. Two small skin defects were noted on the cheeks lateral to the outer canthi (fig 2a, b).

The right humerus was shortened and thickened on x ray. The forearm bones on both sides were thickened with synostosis proximally. On the left, the fifth ray was absent with syndactyly of the third and fourth digits. On the right the thumb was absent and only three rays were present. There was syndactyly of the third and fourth digits (fig 2d).

The legs were of normal length. Only the first and second rays on the right foot were present, with syndactyly of the two toes. The fourth and fifth rays were missing on the left with syndactyly of the first, second, and third toes.

He had a small penis and cryptorchidism (fig 2c). Chromosome karyotype was normal 46,XY.

He initially required no respiratory support but on day 3 of life developed purulent nasopharyngeal

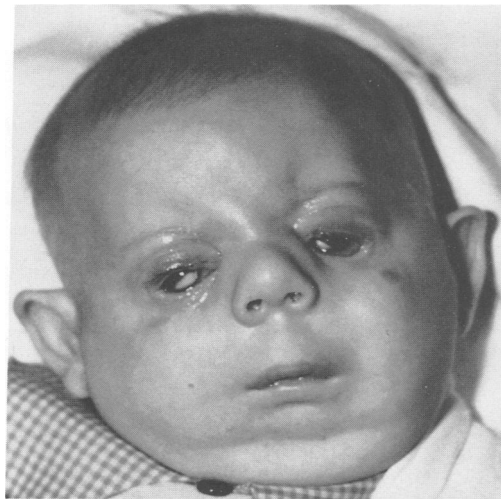


Figure 2a Case 2. Facial features; frontal view showing lower lid ectropion, micrognathia, corneal scarring, and skin defects on cheeks.

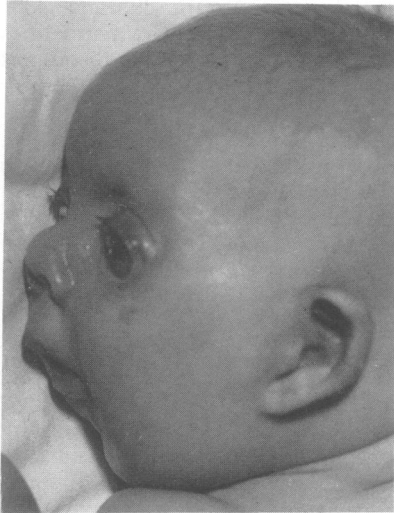

Figure 2b Facial features, side view; note micrognathia and cup shaped ears.

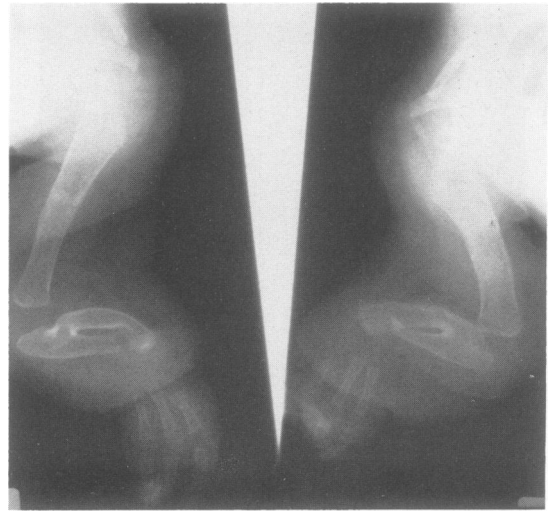


Figure 2d X ray of both upper limbs; note synostosis of radius and ulna.

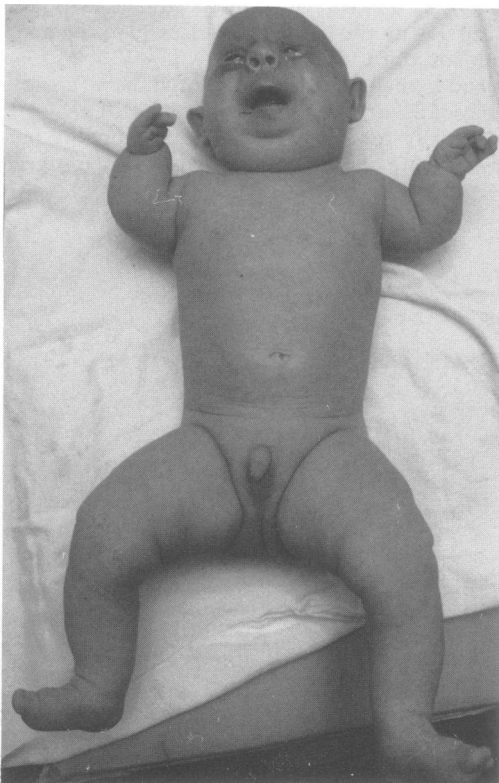


Figure 2c General view; note limb proportions with shortening of forearms and hypoplastic scrotum.

secretions and marked respiratory distress, necessitating nasopharyngeal intubation. Extubation proved difficult but was achieved nursing him prone with his head suspended above the mattress using stockinet taped around his head and attached to the ceiling of the incubator. On resolution of the intercurrent illness he was managed in a Pierre-Robin frame.

On day 6 a systolic murmur was noted, but no other cardiovascular signs. CXR, ECG, and 2D echocardiography were normal.

At 3 weeks of age he developed a urinary tract infection. Renal ultrasound showed moderate hydronephrosis. Micturating cystourethrogram showed bilateral vesicoureteric reflux with a clubbed collecting system on the right (fig 2e). Subsequent recurrent urinary infections (including *pseudomonas*), despite prophylactic antibiotics, have occurred and reimplantation of the right ureter is planned.

He unfortunately developed bilateral corneal ulcers. Subsequent scarring is out of the central visual axis.

Developmentally there has been some delay in some areas owing to his physical defects and early prolonged hospitalisation. Despite the corneal ulcers his vision is probably normal. Although brainstem evoked responses eliminated all but a mild hearing loss at 6 weeks, distraction testing at 10 months indicated moderate hearing loss on the left and mild loss on the right. Tympanometry suggested a left sided effusion.

His growth has fallen away on the centile charts. At 7 months his head circumference is on the 3rd

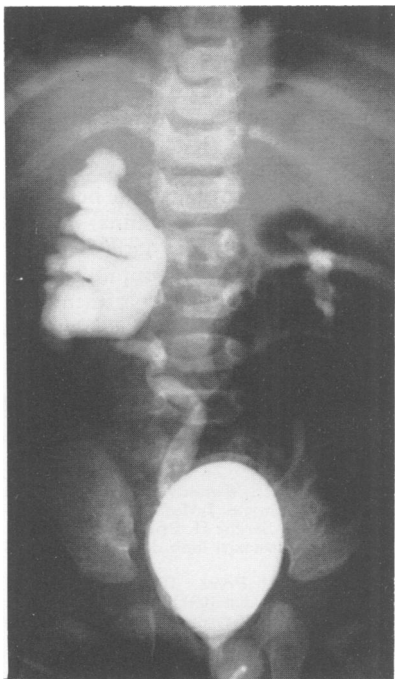


Figure 2e Micturating cystourethrogram showing bilateral vesicoureteric reflux and hydronephrosis.

centile and his length and weight are less than the 3rd centile.

Because of his airways obstruction, palate repair will be deferred until 12 to 18 months of age. The degree of malar hypoplasia is less severe compared with his sister and will probably not require plastic surgical intervention although release of the syndactyly is planned.

The degree of phimosis and cryptorchidism may require surgical intervention.

### Discussion

The two children described have the typical facial and limb features of postaxial acrofacial dysostosis syndrome. The limb defects are predominantly postaxial ray deficiencies (all four limbs of case 1, and both feet and left hand of case 2). In case 2, the right hand deficiency is preaxial with absence of the thumb. The deformities in both children are asymmetrical. The humerus is shortened in one arm in each case. The forearm bones are all shortened and in case 2 there is synostosis proximally.

Both cases have micrognathia with cleft palate, malar hypoplasia, and downward slanting palpebral fissures. The ears are hypoplastic, with a conductive

loss in both children. Case 1 had accessory nipples, but these were not present in case 2. The auscultatory features of the murmur in case 2 are suggestive of a small ventricular septal defect.

Case 1 had features not previously described in this syndrome including malrotation of the fourth part of the duodenum and a large mobile stomach which underwent volvulus. Similarly, case 2 had skin defects lateral to the outer canthi on each cheek, and bilateral vesicoureteric reflex with hydronephrosis and clubbed calyces. He also had cryptorchidism. These latter features may represent an expansion of the recognised phenotypic expression of Miller syndrome.

In both cases, chromosomal analysis was normal, and the occurrence in sibs of the opposite sex of unaffected parents, as in the family previously described,<sup>2</sup> lends weight to an autosomal recessive mode of inheritance.

The main disorders which must be distinguished from postaxial acrofacial dysostosis syndrome described by Miller are Treacher Collins syndrome and Nager syndrome. The Genée-Wiedemann syndrome encompasses Miller syndrome.

In Treacher Collins syndrome, which is usually dominantly inherited, the facial dysmorphism is similar, but the limb anomalies are not part of the syndrome. In Nager AFD syndrome, malar hypoplasia, downward slanting palpebral fissures, micrognathia, and auricular deficiency are all features, but the limb anomalies are preaxial and confined to the upper limbs.

The Genée-Wiedemann syndrome as described by Lewin and Opitz<sup>9</sup> is autosomal recessive with multiple congenital abnormalities. The facial features are of acrofacial dysostosis. Lower limb anomalies vary from hypoplasia of the fifth toes to total absence of the fibulae and polydactyly. Upper limb defects may result in phocomelia with a hypoplastic pectoral girdle. Other features include supernumerary vertebrae and other vertebral segmentation and rib defects, congenital heart disease, accessory nipples, single umbilical artery, and absence of a hemidiaphragm. This syndrome may be associated with mental retardation, which is not a feature of the syndrome described by Miller.

A report by Robinow *et al*<sup>9</sup> of a case of Robin sequence with pre- and postaxial oligodactyly in a mother and son has been suggested as another case of Miller syndrome by Meinecke and Wiedemann.<sup>10</sup> In view of the uncertainty of the classification the case has not been included in the table. It may represent a dominantly inherited phenocopy. In addition, a further case of postaxial acrofacial dysostosis has been described by Hauss-Albert and Passarge.<sup>11</sup> This case had microcephaly and profound mental retardation which may be attributed to perinatal or postnatal hypoxia. The precise classification

Comparison of the clinical features of previously reported cases of Miller syndrome and the present cases.

Manifestation	Previous reports	Case 1	Case 2
Sex	9M,6F (1 not specified)	F	M
<b>Craniofacial</b>			
Malar hypoplasia	16	+	+
Coloboma of eyelids	7	+	+
Downward slanting palpebral fissures	9	+	+
Ectropion	10	+	+
Hypoplastic, cup shaped ears	14	+	+
Hearing deficit	3	+	+
Micrognathia	14	+	+
Cleft lip/palate	12	+	+
Choanal atresia		+	-
<b>Limb</b>			
Postaxial limb deficiency	16	+	+
Syndactyly	4	+	+
Abnormal ulna/radius	8	+	+
Low arch dermatoglyphics	3	+	+
<b>Cardiac</b>			
Congenital heart disease	6	-	+
<b>Other</b>			
Accessory nipples	6	+	-
Midgut malrotation		+	
Renal tract anomalies			+
Cryptorchidism	1		+

of this case is unclear and has not been included as a case of Miller syndrome.

In conclusion, postaxial acrofacial dysostosis syndrome is rare and is apparently inherited as an autosomal recessive trait. The predominant features are Treacher Collins-like facies and limb deficiencies, although the heart, gastrointestinal tract, urinary tract, and skin may also be involved. It is associated with normal intelligence, and the syndrome has now been described in an adult.<sup>4</sup> This

report lends weight to Miller syndrome having autosomal recessive inheritance and emphasises the recognised features of the syndrome as well as expanding these features. It also indicates some of the management problems encountered in the care of these children.

We would like to acknowledge the help of Professor Mac Gardner and Dr Dian Donnai in the preparation of this manuscript, Dr Maria Hrycelak of Illinois, USA for contributing unpublished information, the photo and graphic department of Taranaki Base Hospital for the illustrations, and the family of the patients for their cheerful cooperation.

- 1 Miller M, Fineman R, Smith DW. Postaxial acrofacial dysostosis syndrome. *J Pediatr* 1979;95:970-5.
- 2 Fineman RM. Recurrence of the postaxial acrofacial dysostosis syndrome: implications for genetic counseling. *J Pediatr* 1981;98:87-8.
- 3 Donnai D, Hughes HE, Winter RM. Postaxial acrofacial dysostosis (Miller) syndrome. *J Med Genet* 1987;24:422-5.
- 4 Fryns JP, Van den Berghe H. Brief clinical report. Acrofacial dysostosis with postaxial limb deficiency. *Am J Med Genet* 1988;29:205-8.
- 5 Chrzanoska KH, Fryns JP, Krajewska-Walasek M, Wisniewski L, Van den Berghe H. Phenotype variability in the Miller acrofacial dysostosis syndrome. Report of two further patients. *Clin Genet* 1989;35:157-60.
- 6 Barbuti D, Orazi C, Reale A, Paradisi C. Postaxial acrofacial dysostosis or Miller syndrome. *Eur J Pediatr* 1989;148:445-6.
- 7 Richards M. Miller's syndrome. Anaesthetic management of postaxial acrofacial dysostosis. *Anaesthesia* 1987;42:871-4.
- 8 Lewin SO, Opitz JM. Fibular a/hypoplasia: review and documentation of the fibular development field. *Am J Med Genet* 1986; 2 (suppl):215-38.
- 9 Robinow M, Johnson GF, Apesos J. Robin sequence and oligodactyly in mother and son. *Am J Med Genet* 1986;25:293-7.
- 10 Meinecke P, Wiedemann H-R. Robin sequence and oligodactyly in mother and son - probably a further example of the postaxial acrofacial dysostosis syndrome. *Am J Med Genet* 1987;27:953-6.
- 11 Hauss-Albert H, Passarge E. Postaxial acrofacial dysostosis syndrome with microcephaly, seizures and profound mental retardation. *Am J Med Genet* 1988;31:701-3.