

The non-deletion α thalassaemia/mental retardation syndrome: further support for X linkage

D Donnai, J Clayton-Smith, R J Gibbons, D R Higgs

Abstract

It has previously been suggested that the non-deletion form of the α thalassaemia/mental retardation syndrome may be an X linked disorder. We describe four brothers with this syndrome in whom the diagnosis was first suspected because of their characteristic clinical features, although these varied somewhat from one sib to another. The diagnosis was confirmed in each case by showing Hb H inclusions in a proportion of their red blood cells. The identification of four similarly affected boys in this pedigree is consistent with an X linked pattern of inheritance. In support of this, very rare Hb H inclusions could be found in the red blood cells of the mother and one sister who both share some facial features with the affected boys and are presumably carriers of this disorder. This pedigree thus provides further evidence that this is an X linked syndrome and indicates the clinical and haematological variability that may exist even within a single affected family.

In 1990, Wilkie *et al*¹ described five unrelated patients with mild haemoglobin H (Hb H) disease associated with severe mental retardation. Four of these patients were phenotypic males and one a child who, despite having an XY karyotype, had ambiguous genitalia at birth and has been reared as a female. These subjects have a distinctive phenotype with severe developmental problems and provisional data suggested that this syndrome is encoded on the X chromosome.

Regional Genetics Service, St Mary's Hospital, Whitworth Park, Manchester M13 0JH.
D Donnai, J Clayton-Smith

MRC Molecular Haematology Unit, Institute of Molecular Medicine, John Radcliffe Hospital, Oxford OX3 9DU.

R J Gibbons, D R Higgs

Correspondence to Dr Donnai.

Received for publication 26 June 1991.
Accepted for publication 10 July 1991.

We report a family in which four severely handicapped boys have phenotypic similarities to the previously described patients.¹ The parents and both sisters of the boys have normal intellect. However, the mother and one of the two sisters have some similar, albeit milder, phenotypic and haematological findings to the affected males. This report lends further support to the hypothesis that the non-deletion α thalassaemia/mental retardation syndrome is an X linked disorder.

Case reports

CASE 1

Case 1 is a 15 year old male who has severe mental retardation. He was the second child born in the family, the older sister being entirely normal. He was born at term weighing 3090 g. He was hypotonic and there were significant feeding problems in the first six months. A coronal hypospadias was noted.

He had delayed motor milestones, sitting at 21 months and walking at 3 years 3 months. He has not achieved bowel or bladder control and has no speech. At the age of 9 years 11 months (fig 1), his height was 121.1 cm (<3rd centile), and his OFC was 49.9 cm (<3rd centile). The inner canthal distance (ICD) was 3.2 cm (>75th centile), outer canthal distance (OCD) 9.1 cm (>75th centile), and interpupillary distance (IPD) 5.2 cm (50th centile). He has a right convergent squint and mild midfacial hypoplasia with a short nose, short philtrum, and a narrow bifrontal area with a metopic ridge. His upper central incisors are large and widely separated. He has tapering fingers. His features have coarsened with time and he has made little developmental progress over the past five years. At present he has recurrent episodes of cyanosis which are associated with apnoea and are not thought to be owing to seizures. Cardiological assessment is normal.

CASE 2

Case 2 was the third child born in the family. His birth weight was 3890 g. He had no feeding difficulties and was described as 'stiff' as a baby. His development has been severely retarded and an assessment at a chronological age of 10 months

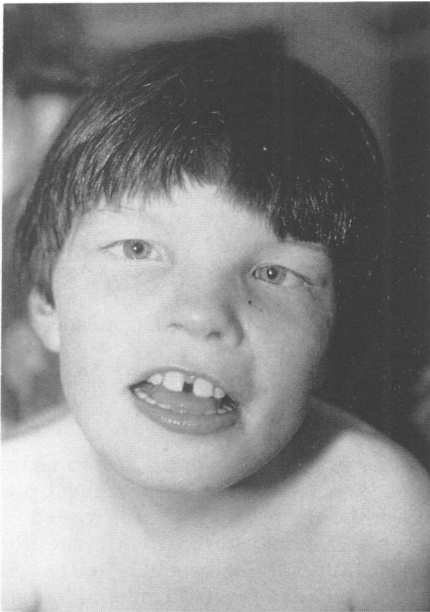


Figure 1 Case 1 at 9 years 11 months. Note the midfacial hypoplasia and marked spacing of central incisors.

showed a mental age of 5 months. He sat at 3 years of age and took his first steps at 3½ years of age. He has no speech and no bowel or bladder control.

On examination at 8 years 8 months (fig 2), his height was 114 cm (<3rd centile), OFC 49.8 cm

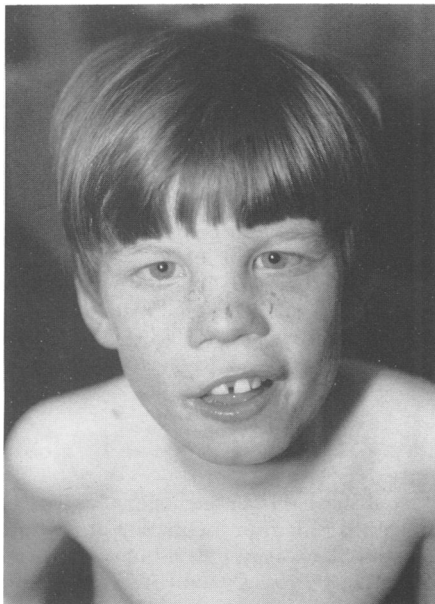


Figure 2 Case 2 at 8 years 8 months.

(<3rd centile), ICD 4 cm (>97th centile), OCD 9.5 cm (>97th centile), and IPD 5.8 cm (97th centile). He has a low forehead with a widow's peak, a broad nasal bridge, midfacial hypoplasia, and small, low set ears. He has large upper incisors which are widely spaced, a small umbilical hernia, and tapering fingers. He has no genital abnormality. Like his brother, his facial features have coarsened with age.

CASE 3

Case 3 was the fifth child born in the family (a sister born between cases 2 and 3 is developmentally normal). He was born at term weighing 2750 g. There were feeding difficulties in the first few months, but tube feeding was not required. At 12 months his length was on the 3rd centile, OFC 46 cm (25th centile), ICD 3.7 cm (>97th centile), OCD 8.8 cm (>97th centile), and IPD 5.5 cm (>97th centile). He has a rounded face with a broad, depressed nasal bridge, marked midfacial hypoplasia (figs 3 and 4), a narrow forehead with a widow's peak, and a convergent squint. His ears are small and low set. He has undescended testes. He is described by his mother as being the most able of the affected boys. He walked at 2 years 8 months, and his general quotient at a chronological age of 17 months was between 50 and 60 with hearing and speech scored at only 36, but personal/social scored at 66. At the age of 6½ years he has two recognisable words and several Makaton signs.

CASE 4

The sixth child in the family is now 5 years of age. He was born at 38 weeks' gestation weighing 3080 g.

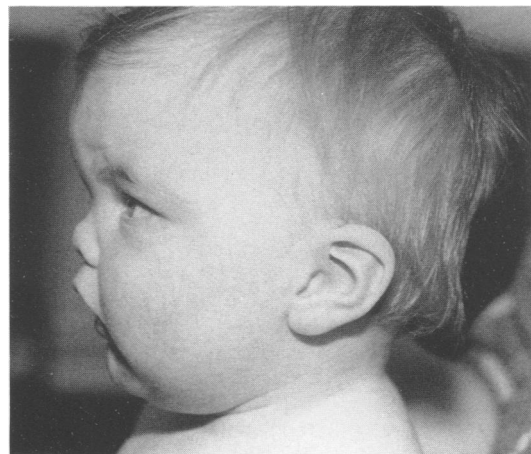


Figure 3 Case 3 at 20 months showing hypoplastic midface and posteriorly rotated ears.

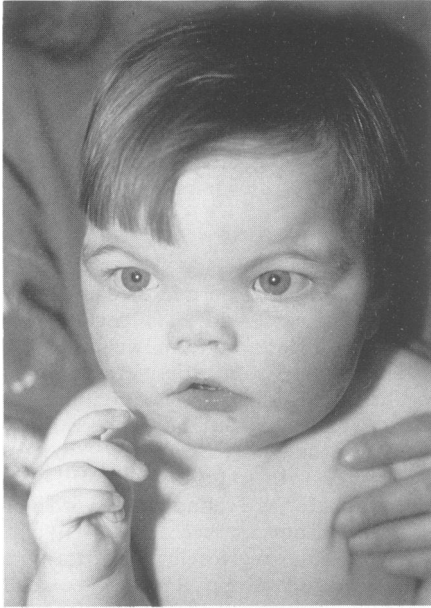


Figure 4 Case 3. There is marked hypertelorism and a cupid's bow appearance of the upper lip.

He was slow to feed, but smiled at 4 weeks of age. He was examined at 11 weeks of age by DD and noted to have less marked midfacial hypoplasia than his three affected sibs (fig 5). He was hypotonic. He has

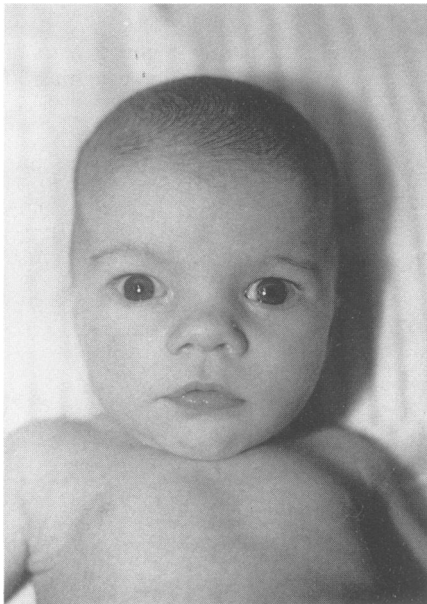


Figure 5 Case 4 at 11 weeks. Hypertelorism is present but the midfacial hypoplasia is less marked.

glandular hypospadias and a small umbilical hernia. His OFC was 37.8 cm (3rd to 10th centile), ICD 2.6 cm (75th to 97th centile), OCD 6.8 cm (75th centile), and IPD 4.5 cm (75th centile). He developed seizures at the age of 4 years which were intractable and were thought to represent an acute encephalitis. A CT brain scan was essentially normal and an electroencephalogram (EEG) was thought to be compatible with an acute encephalopathy. Carbamazepine was prescribed. A number of other seizures have subsequently occurred, especially in relation to fevers. His development has been slow, he walked at 3½ years of age, and has no speech.

Family study

PARENTS

The mother is a healthy woman of normal intellect who trained as a teacher. She developed petit mal epilepsy at the age of 16 which was treated initially with phenobarbitone, but currently she does not require medication. Her height is 160 cm and she has a broad, rounded face with mild midfacial hypoplasia. Her OFC is 55.2 cm (50th centile), ICD 3.1 cm (50th–75th centile), OCD 9.1 cm (50th–75th centile), and IPD 5.6 cm (50th–75th centile).

The father is a healthy science graduate who works in computer science. He has no relevant medical history. He is 193 cm tall, his OFC is 59.4 cm (>97th centile), ICD 3.6 cm (97th centile), OCD 10 cm (97th centile), and IPD 6.6 cm (>97th centile).

SIBS

The older sister (sib 1) is now 17½ years of age. She had normal developmental milestones and is of normal appearance and intellect, studying for A levels and expected to gain a university place.

The younger sister (sib 2) is 10½ years of age. She had normal developmental milestones, is of normal intellect, and making good progress at school. Her height is 147 cm (90th centile). Her OFC is 56 cm (>97th centile) and IPD 5.7 cm (75th to 97th centile). She has a similar facial appearance to her mother with a broad nasal bridge, round face, and mild midfacial hypoplasia with a short, broad nose.

Haematological investigations and α globin gene analysis

All four boys have Hb H inclusions visible on a peripheral blood film after incubation at room temperature with 1% brilliant cresyl blue. The proportion of affected cells varies widely (table) and only in case 3 is there sufficient Hb H to be detectable by haemoglobin electrophoresis. Rare Hb H inclusions

Haematological data of the family.

	Hb (g/dl)	MCV (fl)	MCH (pg)	Hb H + ve cells (%)	Hb H (%)
Case 1	13.5	83.6	27.3	2.8	0
Case 2	11.4	83.2	27.3	2.1	0
Case 3	10.3	75.6	23.2	10.0	1.5
Case 4	11.2	81.8	25.6	1.4	0
Mother	14.8	93.0	31.7	0.03	ND
Father	13.9	91.0	30.5	0.0	0
Sib 1	12.5	89.9	30.2	0.0	ND
Sib 2	13.4	84.3	28.2	0.04	ND

Hb H + ve cells (%) = proportion of red cells positive for Hb H inclusions after incubation with 1% brilliant cresyl blue. Hb H (%) = proportion of Hb H observed on Hb electrophoresis. ND = not determined.

were also noted in the boys' mother and their younger sister. Case 1 has a normal full blood count and indices. Cases 2, 3, and 4 have a mild anaemia. Case 3 has hypochromia and borderline microcytosis.

The α globin genotypes were determined in each family member using the probes $\alpha 1$ globin/*HBA1*,² $\psi\zeta 1$ /*HBZ1*,³ and α globin 3'HVR/*D16S85*.⁴ The α globin genotype in each case was $\alpha\alpha/\alpha\alpha$. A further observation was the independent assortment, in the boys, of the parental α globin 3'HVR alleles.

Discussion

The clinical features of the affected boys in this report are very similar to those of the previously reported patients¹ with the non-deletional form of the α thalassaemia/mental retardation syndrome (now referred to as the ATR-X syndrome⁵). Indeed, the diagnosis in this family was suggested by the facial characteristics in contrast to the five original cases that were ascertained haematologically. The four boys reported here provide examples of the facial appearances in this syndrome at different ages. In the two infants there is a relatively round face with midfacial hypoplasia. In the older boys, the facial features are more coarse with elongation of the face. There is growth deficiency of postnatal onset. The birth weights of all four boys fell within the normal range; however, the three older boys now have heights below the 3rd centile. This family also shows the intrafamilial variability of the clinical features of the syndrome, since only two of the four boys have hypospadias and two have marked hypertelorism, whereas the other two only have hypertelorism relative to their head size. Only one of the boys has words and Makaton signs for communication.

The haematological findings (table) confirm that all the affected boys have a similar mild form of Hb H disease as the five original cases¹ with the

percentage of Hb H positive cells seen on staining with brilliant cresyl blue ranging from 1.4% to 10%. The levels of Hb H are considerably less than those seen in classical mendelian Hb H disease and only case 3 had levels detectable by electrophoresis. The presence of normal haemoglobin and red cell indices in case 1 indicates that the diagnosis cannot be excluded on these criteria alone. Hb H inclusions were seen in the peripheral blood of the mother and younger sister and their carrier status, suspected on clinical examination, was therefore confirmed. Haematological findings in the older sister are entirely normal but further investigations are needed to confirm that she does not carry the ATR-X gene as carrier females may not always show Hb H inclusions.¹

The fact that there are four affected male sibs in this family born to normal parents is consistent with the original suggestion of an X linked disorder.¹ The independent assortment in cases 1 to 4 of the parental α globin 3'HVR alleles provides formal evidence against a mutation of the α globin complex contributing to this syndrome. Until the gene is localised it may be possible to use a combination of phenotype analysis and haematological analysis to identify some carriers. However, a negative haematological screen and a normal phenotype do not exclude the carrier status.

- 1 Wilkie AOM, Zeitlin HC, Lindenbaum RH, *et al.* Clinical features and molecular analysis of the α thalassaemia/mental retardation syndromes. II. Cases without detectable abnormality of the α globin complex. *Am J Hum Genet* 1990;46:1127-40.
- 2 Lauer J, Shen CKJ, Maniatis T. The chromosomal arrangement of human α -like globin genes: sequence homology and α -globin gene deletions. *Cell* 1980;20:119-30.
- 3 Proudfoot NJ, Gil A, Maniatis T. The structure of the human zeta-globin gene and a closely linked, nearly identical pseudogene. *Cell* 1982;31:553-63.
- 4 Jarman AP, Nicholls RD, Weatherall DJ, Clegg JB, Higgs DR. Molecular characterisation of a hypervariable region downstream of the human α globin gene cluster. *EMBO J* 1986;5:1857-63.
- 5 Wilkie AOM, Pembrey ME, Gibbons RJ, *et al.* The non-deletion type of α thalassaemia/mental retardation: a recognisable dysmorphic syndrome with X linked inheritance. *J Med Genet* 1991;28:724.