

# The Baller-Gerold syndrome: phenotypic and cytogenetic overlap with Roberts syndrome

S M Huson, C S Rodgers, C M Hall, R M Winter

## Abstract

A case is reported where the major clinical features of craniostenosis and radial aplasia led to an initial diagnosis of Baller-Gerold syndrome. Mild fibular hypoplasia on skeletal survey led to review of the diagnosis and the similarity of the facial phenotype to that of Roberts syndrome was noted. Chromosome analysis showed the premature centromere

separation characteristic of this condition. This case raises the question as to whether the Baller-Gerold syndrome can be considered as a distinct entity. It is suggested that cases diagnosed as having Baller-Gerold syndrome should have cytogenetic analysis and that known Roberts syndrome survivors are reviewed for signs of craniostenosis.

Kennedy Galton Centre, Northwick Park Hospital, Watford Road, Harrow, Middlesex HA1 3UJ.  
S M Huson, C S Rodgers, R M Winter

Department of Radiology, The Hospital for Sick Children, Great Ormond Street, London WC1N 3JH.  
C M Hall

Correspondence to Dr Winter.

The Baller-Gerold syndrome is a rare autosomal recessive condition characterised by the combination of craniostenosis and radial aplasia/hypoplasia. To our knowledge, only 10 cases<sup>1-7</sup> have been published in the world. In addition to the major syndrome features (both present in all cases), the cases have had a number of other features in common: these are summarised in the table. Cytogenetic analysis in the three cases<sup>5-7</sup> studied has been normal.

Roberts-SC phocomelia syndrome (hereafter referred to as Roberts syndrome) is also inherited as

Received for publication 16 October 1989.

Revised version accepted for publication 28 December 1989.

## Comparison of the major clinical features of Baller-Gerold and Roberts syndromes.

Feature	Roberts syndrome (Summary of cases reviewed in references 8 (n=19)*, 9 (n=24), and 10 (n=21))	Baller-Gerold syndrome (review of reported cases <sup>1-7</sup> )	Present case
Intellect	Mental retardation 11/17 survivors†	Mental retardation 7/11	Normal
Growth retardation	Prenatal onset 41/43	6/7 have height and weight less than 3rd centile for age	Height and weight less than 3rd centile
Facial	(1) Craniostenosis not reported, microcephaly 10/12‡ (2) Cleft lip + palate 39/57 (3) Capillary haemangioma 20/24† (4) Hypoplastic alae nasi 20/20† (5) Malformed ears 14/23§	(1) Craniostenosis 10/10 (2) Bifid uvula 1/10 (3) Facial haemangioma 2/5 (4) Hypoplastic alae nasi 1/3 (5) Malformed ears 5/9	(1) Bilateral coronal suture stenosis (2) Palate normal (3) Facial haemangioma at birth (4) Hypoplastic alae nasi (5) Ears normal
Upper limbs§	Hypoplasia/aplasia of Radius 36/36 Ulna 36/36 Humerus 22/35	Radial hypoplasia/aplasia 10/10	Radial hypoplasia
Lower limbs§	Hypoplasia/aplasia of Fibula 30/35 Tibia 28/35 Femur 23/35	No major abnormalities reported	Clinically normal but on x ray fibulae slender and hypoplastic with proximal shortening
Hair	Silvery-blond 8/19 survivors†	No abnormalities reported	Normal
Genitalia	Cryptorchidism 9/14§ Penile enlargement 13/24§	No genital abnormalities reported	Normal

\*Excluding cases reviewed in references 9 and 10. †From references 8 and 10 only. ‡From reference 10 only. §From references 9 and 10 only.

an autosomal recessive trait<sup>11</sup>; although still a rare malformation syndrome, it is more frequent than the Baller-Gerold syndrome and over 60 cases have been reported.<sup>8</sup> The major features are reduction deformities of all four limbs, more pronounced in the upper limbs, associated with orofacial abnormalities, most commonly cleft lip and palate. Other syndrome features are listed in the table. Approximately half of the reported cases have shown a characteristic cytogenetic abnormality with a 'puffed' appearance of the centromeres owing to premature centromere separation (PCS).<sup>11</sup>

We report a case in whom the major clinical features are compatible with the diagnosis of the Baller-Gerold syndrome, but who had a facial appearance similar to that seen in the milder cases of Roberts syndrome and in whom cytogenetic analysis showed PCS.

#### Case report

The proband was assessed when referred for genetic counselling at 26 years of age. She is the oldest child of non-consanguineous, Caucasian parents with two normal younger sibs. She had been born by vaginal delivery at term, after an uneventful pregnancy, with a birth weight of 2950 g. At birth she was noted to have brachycephaly owing to fusion of both coronal sutures (head circumference 33 cm, <3rd centile), bilateral radial hypoplasia with hypoplastic thumbs, and a forehead capillary haemangioma. Surgery had not been undertaken for the craniostenosis but hand function had been improved by splinting and a series of surgical procedures.

Apart from requiring ligation of a patent ductus arteriosus she had had no other major problems. Early

developmental milestones were normal and she had attended normal schools, although requiring remedial class education in secondary school. When seen she was working as a care assistant in an old people's home; her intellect was subjectively assessed to be at the lower end of the normal range.

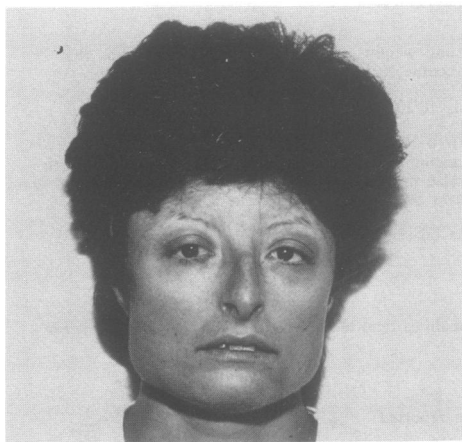On examination both height (147 cm) and head circumference (48.5 cm) were below the 3rd centile. Her skull was brachycephalic with a particularly flat forehead, high nasal bridge, and hypoplastic alae nasi giving a facial appearance similar to that seen in Roberts syndrome (fig 1a). Her forearms were short with radial deviation of the hands (fig 1b). She had short thumbs and biphalangal fifth fingers. The only abnormality of the lower limbs was mild 2/3 syndactyly. In view of the short stature a skeletal survey was undertaken.

#### RADIOLOGICAL FINDINGS

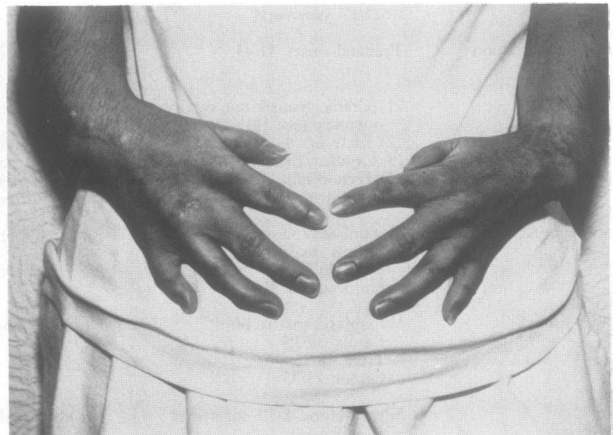
In addition to the craniostenosis (fig 2a) and radial hypoplasia (fig 2b), there were a number of less marked radiological abnormalities. The vertebral bodies in the lumbar region were abnormally modelled with a reduction of their AP diameters. In the lower limbs there was bilateral coxa valga and acetabular dysplasia with incomplete covering of the capital femoral epiphyses. The fibulae were slender and hypoplastic with proximal shortening (fig 2c) and the articular surfaces at the knees and ankles were featureless with loss of modelling. In the feet the middle phalanges were small or absent.

#### CYTOGENETIC ANALYSIS

Analysis of 30 G banded metaphases showed a normal

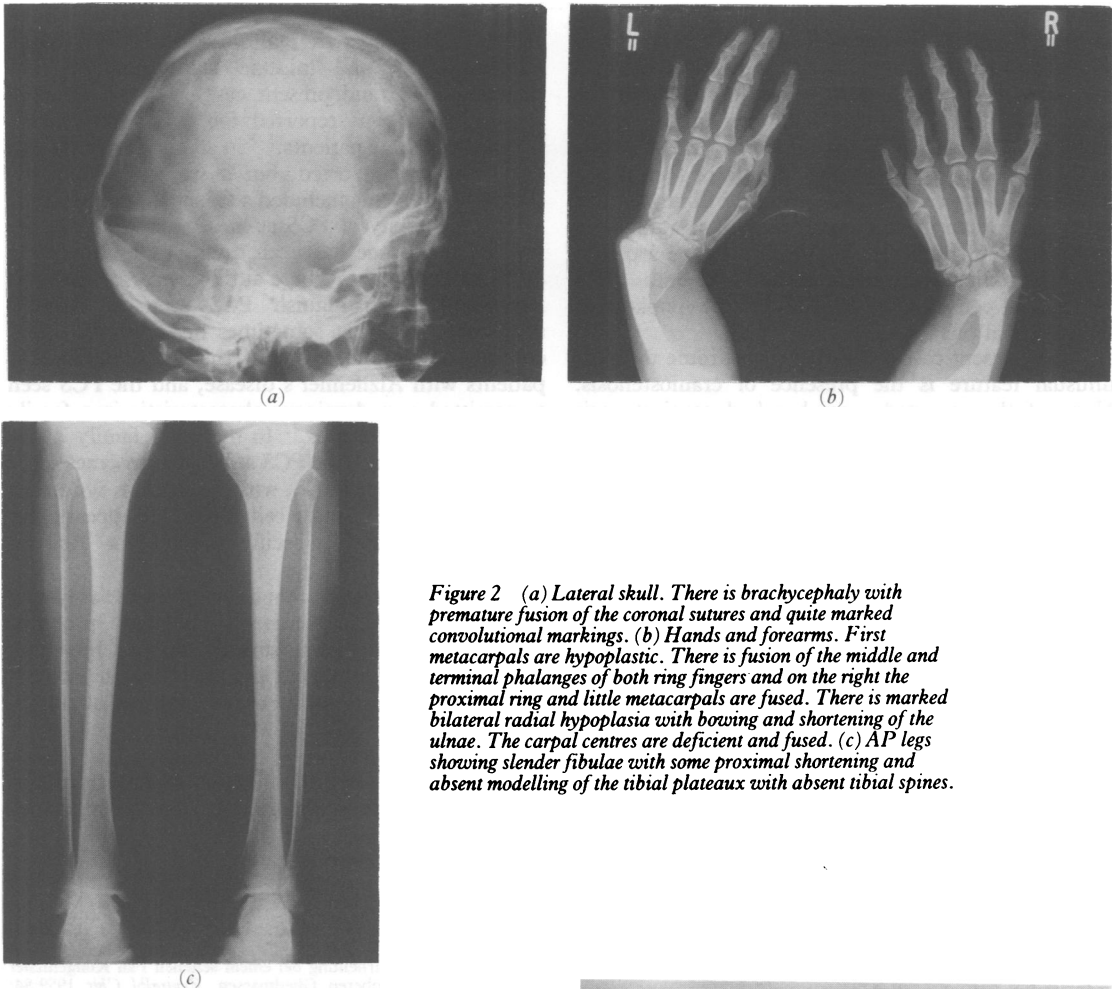


(a)



(b)

Figure 1 (a) Facial appearance of the patient at the age of 26 years. (b) Forearms of patient.

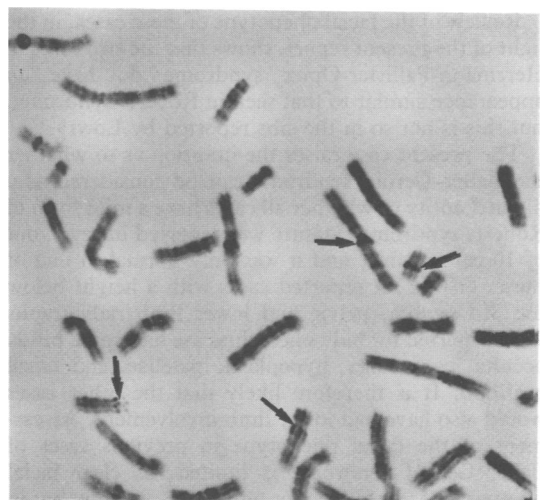

*Figure 2 (a) Lateral skull. There is brachycephaly with premature fusion of the coronal sutures and quite marked convolutional markings. (b) Hands and forearms. First metacarpals are hypoplastic. There is fusion of the middle and terminal phalanges of both ring fingers and on the right the proximal ring and little metacarpals are fused. There is marked bilateral radial hypoplasia with bowing and shortening of the ulnae. The carpal centres are deficient and fused. (c) AP legs showing slender fibulae with some proximal shortening and absent modelling of the tibial plateaux with absent tibial spines.*

female karyotype with apparently random chromosome gain in 13% of cells. PCS and heterochromatin puffing similar to that seen in Roberts syndrome were observed in G banded metaphases but were more marked in C banded preparations (fig 3). The centromeric regions of chromosomes 1, 9, and 16 and the acrocentric chromosomes were mainly involved.

**Discussion**

The initial clinical diagnosis in this case was Baller-Gerold syndrome and the skeletal survey was undertaken to investigate further the aetiology of short stature in this condition. The lower limb abnormalities on the skeletal survey led us to review the case, when the similarity of the facial phenotype to that of Roberts syndrome was noted and cytogenetic studies were undertaken. In view of the finding of PCS it is



*Figure 3 Partial C banded metaphase from the patient. Arrows indicate examples of PCS.*

felt that the case has a mild form of Roberts syndrome in which upper limb involvement is usually more severe and marked variation of the degree of limb involvement has been documented even within the same sibship.<sup>12,13</sup> The case with least limb involvement was reported by Petrinelli *et al*<sup>14</sup>; the diagnosis in this case was based on the finding of PCS and a typical facial appearance. The only limb abnormalities were mild forearm shortening with bony ankylosis owing to right humeroradial synostosis and a partial left humeroulnar synostosis; in the lower limbs there was medial convexity of the tibiae and hypoplasia of the proximal phalanges.

If the present case has Roberts syndrome then the unusual feature is the presence of craniostenosis. None of the reported cases has had craniostenosis although an abnormal skull shape (usually microbrachycephaly) is frequently noted. The authors are aware of one case<sup>15</sup> with otherwise typical features of Roberts syndrome who was noted to be microcephalic at birth and then developed premature stenosis of all cranial sutures. On review at 8 years the patient had a typical clover leaf skull abnormality and PCS was found on chromosome analysis. There are similar published cases that have been distinguished from either Roberts or Baller-Gerold syndromes because of the presence of craniostenosis or a different pattern of limb abnormalities. These include the single cases with craniostenosis, moderately severe symmetrical limb abnormalities, and cleft lip/palate reported by Herrmann *et al*<sup>16</sup> and Ladda *et al*,<sup>17</sup> which have been classified as having the Herrmann-Pallister-Opitz syndrome,<sup>18</sup> and the two male sibs with craniostenosis and bilateral fibular aplasia described by Lowry.<sup>19</sup> Chromosomes were reported in all cases as being normal, but it was not specifically stated whether C banded preparations were studied.

Review of the facial phenotype of these cases, in the light of the present report, shows that the two cases of Herrmann-Pallister-Opitz syndrome do have an appearance similar to that seen in Roberts syndrome, but this is not so in the sibs reported by Lowry.<sup>19</sup>

The present case raises the question as to whether the Baller-Gerold syndrome can be considered as a distinct entity or whether all cases have a mild form of Roberts syndrome. Stature was reported in seven out of 10 cases (table) and it was only normal in one of these. Of the six reported cases with a height below the 3rd centile, pelvic and lower limb radiographs were reported for only one<sup>7</sup>; this case had spina bifida occulta, coxa valga, hypoplastic patellae, and tarsal coalition. It is therefore likely that the other cases would also have had lower limb involvement. Assessment of the facial phenotype in previous cases of Baller-Gerold syndrome is limited, as clear facial photographs were given for only three patients, but in one of these<sup>1</sup> the facial phenotype appeared similar to that seen in our case and in Roberts syndrome. The

other Roberts syndrome features reported in the Baller-Gerold cases are malformed ears (5/9), hypertelorism (2/5), and midline facial capillary haemangioma (2/5 and present case). Finally, chromosome analysis was reported for only three Baller-Gerold syndrome patients,<sup>5-7</sup> in all of whom a normal karyotype was reported, but it was not specifically stated whether this included a C banded preparation.

The specificity of PCS as a diagnostic marker for Roberts syndrome has been discussed by Stanley *et al*<sup>20</sup> and Tomkins.<sup>21</sup> These authors stressed that it is important to distinguish PCS seen in Roberts syndrome from that sometimes described in the X chromosomes of older women, the X chromosomes of patients with Alzheimer's disease, and the PCS seen transmitted as a dominant characteristic in a family reported by Rudd *et al*.<sup>22</sup> In the latter family it was noted that although the PCS affected autosomes, only a few cells displayed PCS, while in Roberts syndrome PCS is observed in most cells. Thus, it appears that PCS is a relatively specific marker for Roberts syndrome.

We therefore suggest that cases diagnosed as having the Baller-Gerold or Herrmann-Pallister-Opitz syndromes should have cytogenetic analysis, including a C banded preparation, and that known Roberts syndrome survivors are reviewed for signs of craniostenosis.

We thank Dr R Gorlin for helpful discussions about this case and Mrs S Kingsley for typing the manuscript.

- 1 Baller F. Radiusaplasie und Inzucht. *Z Mensch Vererb-Konstit-Lehre* 1950;29:782-90.
- 2 Gerold M. Frakturheilung bei einem seltenen Fall Kongenitaler Anomalie der oberen Gliedmassen. *Zentralbl Chir* 1959;84: 831-4.
- 3 Greitzer LJ, Jones KL, Schnell BS, Smith DW. Craniosynostosis-radial aplasia syndrome. *J Pediatr* 1974;84:723-4.
- 4 Temtamy SA, McKusick VA. *The genetics of hand malformations*. New York: Alan R Liss, 1978.
- 5 Feingold M, Sklower SL, Willner JP, Desnick RJ, Cohen MM Jr. Clinical memoranda. Craniosynostosis-radial aplasia: Baller-Gerold syndrome. *Am J Dis Child* 1979;133:1279-80.
- 6 Anyane Yeboa K, Gunning L, Bloom AD. Baller-Gerold syndrome; craniosynostosis-radial aplasia syndrome. *Clin Genet* 1980;17:161-6.
- 7 Pelias MZ, Superneau DW, Thurmon TF. Brief clinical report: a sixth report (eighth case) of craniosynostosis-radial aplasia (Baller-Gerold) syndrome. *Am J Med Genet* 1981;10:133-9.
- 8 Robins DB, Ladda RL, Thieme GA, Boal DK, Emanuel BS, Zackai EH. Prenatal detection of Roberts-SC phocomelia syndrome: report of 2 sibs with characteristic manifestations. *Am J Med Genet* 1989;32:390-4.
- 9 Freeman MVR, Williams DW, Schimke RN, Temtamy SA, Vachier E, German J. The Roberts syndrome. *Clin Genet* 1974;5:1-16.
- 10 Herrmann J, Opitz JM. The SC phocomelia and the Roberts syndrome: nosologic aspects. *Eur J Pediatr* 1977;125:117-34.
- 11 Jones KL. *Smith's recognizable patterns of human malformation*. Philadelphia: Saunders, 1988.
- 12 Da Silva EO, Bezerra LHGE. The Roberts syndrome. *Hum Genet* 1982;61:372-4.
- 13 Parry DM, Mulvihill JJ, Tsui S, Kaiser-Kupfer MI, Cowan JM. SC phocomelia syndrome, premature centromere separation

- and congenital cranial nerve paralysis in two sisters, one with malignant melanoma. *Am J Med Genet* 1986;24:653-72.
- 14 Petrinelli P, Antonelli A, Marcucci L, Dallapiccola B. Premature centromere splitting in a presumptive mild form of Roberts syndrome. *Hum Genet* 1984;66:96-9.
  - 15 Holmes-Seidle M, Serés-santanaria A, Crocker M, Hall JG, Crouchman M. Brief clinical report. A sibship with Roberts syndrome/SC phocomelia. *Am J Med Genet* (in press).
  - 16 Herrmann J, Pallister PD, Opitz J. Craniosynostosis and craniosynostosis syndromes. *Rocky Mt Med J* 1969;66:45-56.
  - 17 Ladda RL, Stortzfus E, Gordon SL, Graham WP. Craniosynostosis associated with limb reduction malformations and cleft lip/palate: a distinct syndrome. *Pediatrics* 1978;61:12-5.
  - 18 Gorlin RJ, Pindborg JJ, Cohen MM Jr. *Syndromes of the head and neck*. New York: McGraw-Hill, 1976.
  - 19 Lowry RB. Congenital absence of the fibula and craniosynostosis in sibs. *J Med Genet* 1972;9:227-9.
  - 20 Stanley WS, Pai GS, Horger EO, Yongshan Y, McNeal KS. Incidental detection of premature centromere separation in amniocytes associated with a mild form of Roberts syndrome. *Prenat Diagn* 1988;125:565-9.
  - 21 Tomkins DJ. Premature centromere separation and the prenatal diagnosis of Roberts syndrome. *Prenat Diagn* 1989;9:450-1.
  - 22 Rudd NL, Teshima IE, Martin RE, Siskin JE, Weksberg R. A dominantly inherited cytogenetic anomaly: a possible cell division mutant. *Hum Genet* 1983;65:117-21.