

Multiple exostoses in a patient with t(8;11)(q24.11;p15.5)

R F Ogle, P Dalzell, G Turner, D Wass, M-Y Yip

Abstract

The occurrence of multiple exostoses in a carrier of a balanced translocation t(8;11)(q24.11;p15.5) is described. The breakpoint on chromosome 8 is at proximal q24.1 within the critical region reported for Langer-Giedion syndrome.

The dominantly inherited condition, multiple exostoses, has not been located definitively to any part of the genome. There is evidence to suggest that it may be located at 8q24.1.¹ This region is the site of the deletion associated with Langer-Giedion syndrome (LGS) and trichorhinophalangeal syndrome (TRP) type I.^{1,2} The difference between the former and the latter is the additional presence of multiple exostoses and mental retardation in LGS. This may be an example of a contiguous gene syndrome depending on the extent of the deletion in the region of 8q24.1.^{1,2} The multiple exostoses seen are identical in character, histology, and location to those in hereditary multiple exostoses (HME).³

We report a patient with a balanced reciprocal translocation t(8;11)(q24.11;p15.5) involving a break at 8q24.11 with only the clinical features of hereditary multiple exostoses, providing support for the gene location of multiple exostoses at 8q24.11.

Case report

A 40 year old woman from Sri-Lanka presented to our obstetric clinic at 16 weeks' gestation for prenatal testing for chromosomal abnormalities because

Medical Genetics Department, Prince of Wales Children's Hospital, Sydney, Australia.

R F Ogle, G Turner

Cytogenetics and Cell Biology Unit, Prince of Wales Hospital, Randwick, Sydney, NSW 2031, Australia.

P Dalzell, M-Y Yip

Department of Obstetrics and Gynaecology, Royal Hospital for Women, Sydney, Australia.

D Wass

Correspondence to Dr Yip.

of advanced maternal age. Her past obstetric history included the birth of a child in 1979 by caesarian section. The baby weighed 1500 g, was morphologically normal, but died at 3 days of age. The cause of death was unknown and no necropsy was performed. Her second pregnancy in 1982 resulted in a normal female at term. A detailed ultrasound in this third pregnancy was normal. However, on amniocentesis, an abnormal 'deleted' chromosome 8, possibly a derivative of a familial translocation, was detected. Urgent karyotyping of the patient and her husband showed an apparently balanced reciprocal translocation t(8;11)(q24.11;p15.5) in the patient (fig 1). She subsequently had a termination of pregnancy but no necropsy was performed. The fetus was therefore interpreted to have inherited the mother's derivative chromosome 8 with the fetal karyotype, 46,XY,der(8),t(8;11)(q24.11;p15.5) confirmed on karyotyping fetal tissue.

The patient was reviewed at the Genetic Clinic. She is 1.40 m tall and is of above average intelligence. Her past history included the removal of a bony lesion from her left proximal tibia. She was aware that she had a similar bony protuberance on the upper part of her right humerus which caused her no difficulty or discomfort. A skeletal survey showed multiple exostoses *without* coned shaped epiphyses (figs 2 and 3). Her facial features were unremarkable except for slightly upturned nares and the texture of her hair was normal. She had short toes with overlapping of the second and third and fourth and fifth toes. Her family history indicated five brothers and two sisters of average height with children of normal stature. The patient's only living daughter was of normal stature as were the patient's parents. These persons were not available for examination. The patient herself was unreceptive to further study and we were unable to obtain a photograph or any tissue to establish a cell line.

Discussion

The patient's skeletal abnormalities represent an example of classical hereditary multiple exostoses. She exhibits no other features of Langer-Giedion syndrome nor of trichorhinophalangeal syndrome type I. This patient is the first example of an association of multiple exostoses and a balanced

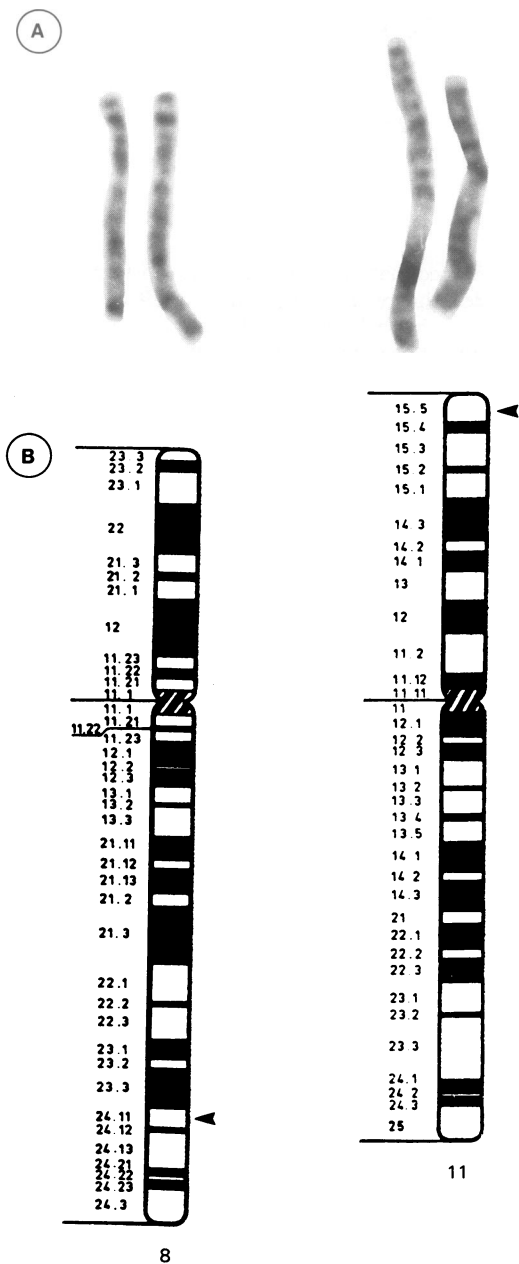


Figure 1(A) Chromosomes 8 and 11 involved in the reciprocal translocation in the patient. The derivative chromosomes are on the left. (High resolution studies by 10 µg/ml ethidium bromide, two hours before harvest.) (B) Diagrammatic illustration of the breakpoints.

reciprocal translocation involving chromosome 8. It is now increasingly evident that some apparently balanced reciprocal translocations are not without

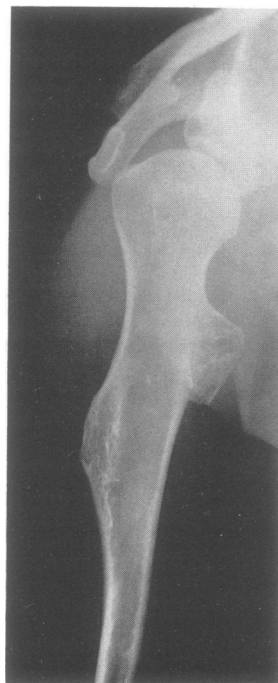

Figure 2 Right humerus illustrating two exostoses.

phenotypic effects.⁴ Most of the reported cases have been de novo and showed increased risks of congenital abnormalities or mental retardation or both, though familial translocations have not been uncommon.⁴ Our patient with a balanced translocation and breaks at 8q and 11p, but otherwise manifesting a normal phenotype except for multiple exostoses, supports the chromosome location for multiple exostoses to be within the 8q24.1 region.¹ The break on the derived chromosome 8 appeared to be at sub-band q24.11 with bands distal to it translocated to 11p. Presumably proximal sub-band q24.11 rather than q24.13, as proposed by Buhler *et al*¹ in their study of patients with 8q deletions, would be critical to the development of exostoses. The adverse effects of breaks and rejoinings in 'balanced' translocation rearrangements in causing phenotypic anomalies could involve (1) a deletion/duplication at the break-points, or (2) gene mutation, or (3) gene disruption, that is, loss of function of genes because of a 'position effect', or possibly (4) 'unmasking of recessive genes' disrupted in a translocation.⁴ It may well be that the combined involvement of bands 8q24.11 (even to the extent of a possible 'microdeletion' at the 8q breakpoint as defined in our patient) and 8q24.12 (mostly deletions) would be sufficient for expression of the LGS phenotype. This would support the findings of Bowen *et al*⁵ of an interstitial

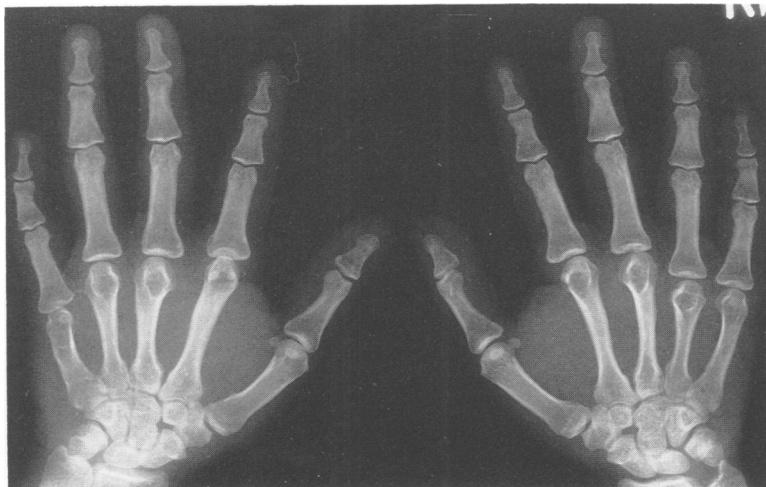

Figure 3 Hand radiographs without cone shaped epiphyses.

deletion 8q24.11→8q24.12 in a patient with characteristic LGS phenotype and that of Fennell *et al*⁶ whose two patients with terminal deletions distal to this, at 8q24.13, showed no obvious features of LGS.

The patient with a breakpoint at 8q allows multiple exostoses to be localised to 8q24.11 within the critical region for the causation of LGS,¹ though further evaluation at the molecular level will be required. Hall *et al*⁷ were unable to find any abnormalities in cells cultured from an exostosis. Results of families with HME when typed with DNA probes within the LGS region should further help to elucidate the multiple exostoses gene defect.⁸

1 Buhler EM, Buhler UK, Beutler C, Fessler R. A final word on the tricho-rhinophalangeal syndromes. *Clin Genet* 1987; 31:273-5.

2 Fryns JP, Van den Berghe H. 8q24.12 interstitial deletion in trichorhinophalangeal syndrome type I. *Hum Genet* 1986;74:1878-89.

3 Langer LO Jr, Krassikoff N, Laxova R, *et al*. The tricho-rhinophalangeal syndrome with exostoses (or Langer-Giedion syndrome): four additional patients without mental retardation and review of the literature. *Am J Med Genet* 1984;19:81-111.

4 Funderburk SJ, Spence MA, Sparkes RS. Mental retardation associated with 'balanced' chromosome rearrangements. *Am J Hum Genet* 1977;29:136-41.

5 Bowen P, Biederman B, Hoo JJ. The critical segment for the Langer-Giedion syndrome 8q24.11→q24.12. *Ann Genet (Paris)* 1985;4:224-7.

6 Fennell SJ, Benson JWT, Kindley AD, Schwarz MZ, Czepulkowski B. Partial deletion 8q without Langer-Giedion syndrome: a recognisable syndrome. *J Med Genet* 1989;26:167-71.

7 Hall JG, Wilson RD, Kalousek D, Beauchamp R. Familial multiple exostoses - no chromosome 8 deletion observed. *Am J Med Genet* 1985;22:639-40.

8 Ludecke HJ, Burdick R, Senger G, Claussen U, Passarge E, Horsthemke B. Maternal origin of a de novo chromosome 8 deletion in a patient with Langer-Giedion syndrome. *Hum Genet* 1989;82:327-9.