

LETTERS TO THE EDITOR

Pachygyria, joint contractures, and facial abnormalities: a new lethal syndrome

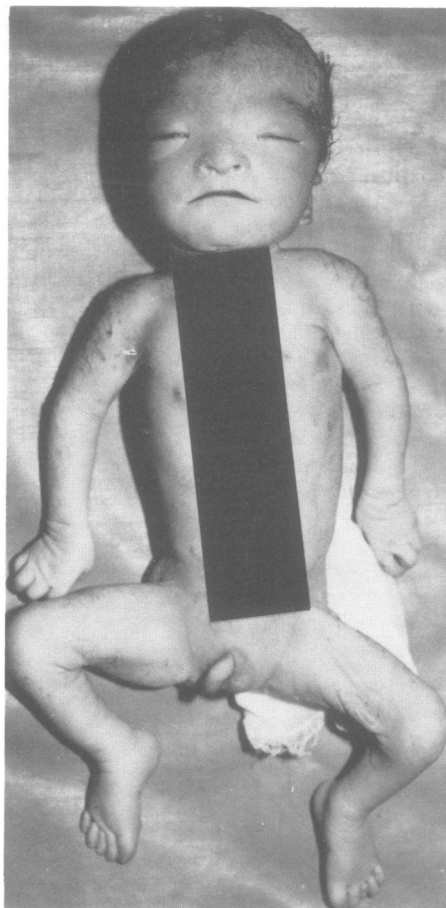
The recent article by Winter *et al*¹ entitled 'Unknown syndrome: pachygyria, joint contractures, and facial abnormalities', reminded us of a still-born baby we saw nine years ago.

The boy was stillborn after a 39 week pregnancy to a 25 year old gravida 2, para 1 mother and a 27 year old father, both healthy and unrelated. There was a 2 year old older brother who appeared normal. There was no history of medication, irradiation, or viral illness during the pregnancy. Bradycardia in the fetus was noted in the first stage of delivery, and heart beats stopped when the cervix dilated.

The baby (figure) weighed 1590 g (-4 SD), measured 41.5 cm (-3.9 SD), and had a head circumference of 27 cm (-4.3 SD). He had brachycephaly, a large anterior fontanelle, upsweep of the hair on the forehead, sparse median eyebrows, hyper-telorism, downward slanting palpebral fissures, infraorbital grooves, a depressed nasal bridge, hypoplastic alae nasi, a short philtrum, a large, carp shaped mouth with thin lips, and low set, slanted ears with a simple right earlobe. He had a cleft soft palate, redundant skin around the neck, retractile nipples, and a right undescended testis. The hands and feet were puffy with camptodactyly of the fingers and hyperconvex fingernails. The fifth fingers were short and incurved. The big toes were proximally positioned. Soft tissue syndactyly between the second and third toes was noted.

Dermatoglyphic studies showed the axial triradii in the *t* position on both hands and a simian crease on the left hand. Finger ridge patterns were whorl (W), W, radial loop, W and W on both hands. G banded chromosome analysis on cultured skin fibroblasts showed a 46,XY karyotype.

At necropsy, the lungs, kidneys, and spleen were all hypoplastic. The lungs together weighed 12.4 g, only a quarter of their normal weight of 50 g, the kidneys weighed 7 g (normal weight,



The patient at necropsy.

10 g), and the spleen weighed only 3 g (normal weight 10 g). On the other hand, the liver, heart, and adrenal glands were all heavier than normal, weighing 110 g, 9 g, and 6 g, respectively, about 1.5 times their normal weight. There was an atrial septal defect, a ventricular septal defect, and an overriding aorta. The liver and spleen showed marked extramedullary haematopoiesis with haemosiderin accumulation. The kidneys showed degenerative changes of the tubular epithelial cells with infiltration of neutrophils and calcification. The distal tubules were dilated. Permission for necropsy of the brain was not granted.

Our patient shared a number of features with the patient described by Winter *et al*.¹ They included a characteristic facial appearance, puffy hands,

camptodactyly, cutaneous syndactyly, and hypoplastic lungs and kidneys, although pachygyria was unproven in our patient. It seems that together they constitute a new, lethal malformation syndrome.

M TSUKAHARA, Y SUGIO, T KAJII
Department of Paediatrics, Yamaguchi
University School of Medicine, Ube,
Yamaguchi, Japan 755.

M TAKAHASHI
Department of Pathology, Yamaguchi
University School of Medicine, Japan.

M HIROTA, H KATO
Department of Obstetrics and Gynaecology,
Yamaguchi University School of Medicine,
Japan.

¹ Winter RM, Harding BN, Hyde J. Unknown syndrome: pachygyria, joint contractures, and facial abnormalities. *J Med Genet* 1989;26:788-9.