

## Tolosa–Hunt syndrome

### The dangers of an eponym

T. J. FOWLER, C. J. EARL, V. L. McALLISTER, AND W. I. McDONALD  
*From the Institute of Neurology, National Hospital for Nervous Diseases, London*

The syndromes arising from lesions of the orbital apex have received increasing attention in recent years. One of these, characterized by painful, acute ophthalmoplegia with or without involvement of the optic nerve and ophthalmic division of the trigeminal nerve, and responding promptly to steroid treatment, has come perhaps wrongly to be regarded as a distinct entity, often called the Tolosa–Hunt syndrome. In a single autopsied case there was a mass of granulation material around the carotid artery in the cavernous sinus (Tolosa, 1954). It is important to recognize, however, that many of the features of the syndrome occur with other types of pathological process occurring in the same region and for which steroids are not necessarily the proper treatment. Here we report two such cases in order to emphasize the need for full investigation of patients who do not precisely fit into the description of Tolosa (1954) and Hunt, Meagher, LeFever, and Zeman (1961).

#### Case reports

**Case 1, a 61-year-old film curator**, presented in January, 1972, with a 3-month history of worsening vertical diplopia. Within the last 3 weeks he had developed ptosis, blurred vision, pain in the right eye, and numbness of the forehead on that side.

24 and 18 months previously he had noticed two episodes of periorbital swelling on either side. These had been thought to be inflammatory in nature and both had settled after antibiotic treatment.

#### Examination

There was 2 mm. of right-sided proptosis with ptosis. The visual acuity was 6/24 in the right eye and 6/6 in the left. There was a central field defect in the right eye. The fundi were normal but the intraocular pressure was raised on the right to 34 mm.Hg. There was a partial right third nerve palsy with some pupillary dilatation, a complete right sixth nerve palsy, and some sensory impairment in the ophthalmic branch of the right trigeminal nerve.

The differential diagnosis included an aneurysm, inflammatory lesion, or neoplasm in the region of the orbital apex or cavernous sinus.

#### Investigations

The blood count was normal with an erythrocyte sedimentation rate of 5 mm. 1st hr, and negative Waaler–Rose, latex, and antinuclear factor tests. A glucose tolerance test was normal. The blood Wassermann reaction was negative. The cerebrospinal fluid showed no cellular excess but the protein was elevated (100 mg. per cent.). The electroencephalogram showed an excess of slow activity on the right side. The only abnormality on the skull *x* rays was an expanded right superior orbital fissure (Fig. 1). A right carotid angiogram was normal and an air encephalogram showed slight ventricular dilatation. A right orbital phlebogram showed failure of normal filling of the terminal part of the right superior ophthalmic vein (Fig. 2).

#### Treatment

It was thought that the most likely diagnosis was an inflammatory granuloma and he was started on prednisolone, 60 mg. daily; after 4 days his pain had eased. Within 2 weeks the external ocular movements had greatly improved and the visual acuity was now 6/18 in the right eye. The proptosis persisted as did the field defect which now appeared more supero-central. The elevated intraocular pressure was treated with 2 per cent. Pilocarpine eye drops. The steroid dose was gradually reduced to prednisolone 20 mg. daily, but 4 weeks after discharge he developed a 'flu-like illness and again complained of severe pain in the right eye with marked diminution in visual acuity.

#### Progress

On re-admission there was still 2 mm. proptosis on the right side but the visual acuity was reduced to hand movements. The supero-temporal field appeared to be lost and the patient showed an afferent pupillary defect. There was involvement of the right third, sixth, and ophthalmic branch of the trigeminal nerves.

The blood count was still normal, and two further erythrocyte sedimentation rates were 2 and 5 mm./1st hr.

#### Operation

Surgical exploration was performed by Mr. L. Walsh through a right frontal flap. On deroofting the orbit, firm tissue was found wrapped around the first division of the trigeminal nerve. Histologically this proved to be a malignant lymphoma.

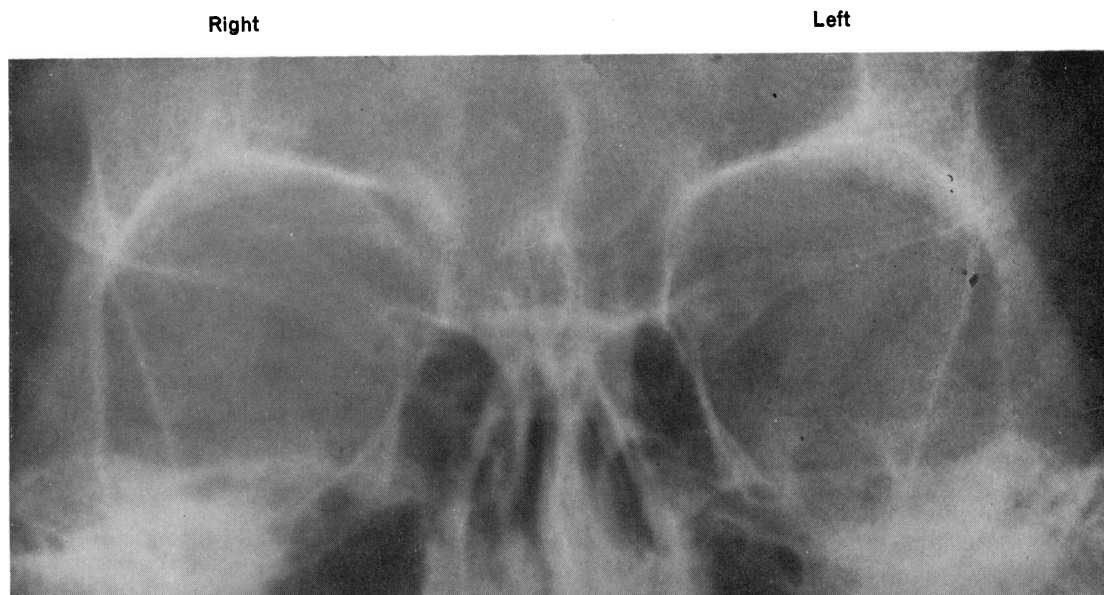


FIG. 1 *Widened superior orbital fissure on the right in Case 1. See text for details*

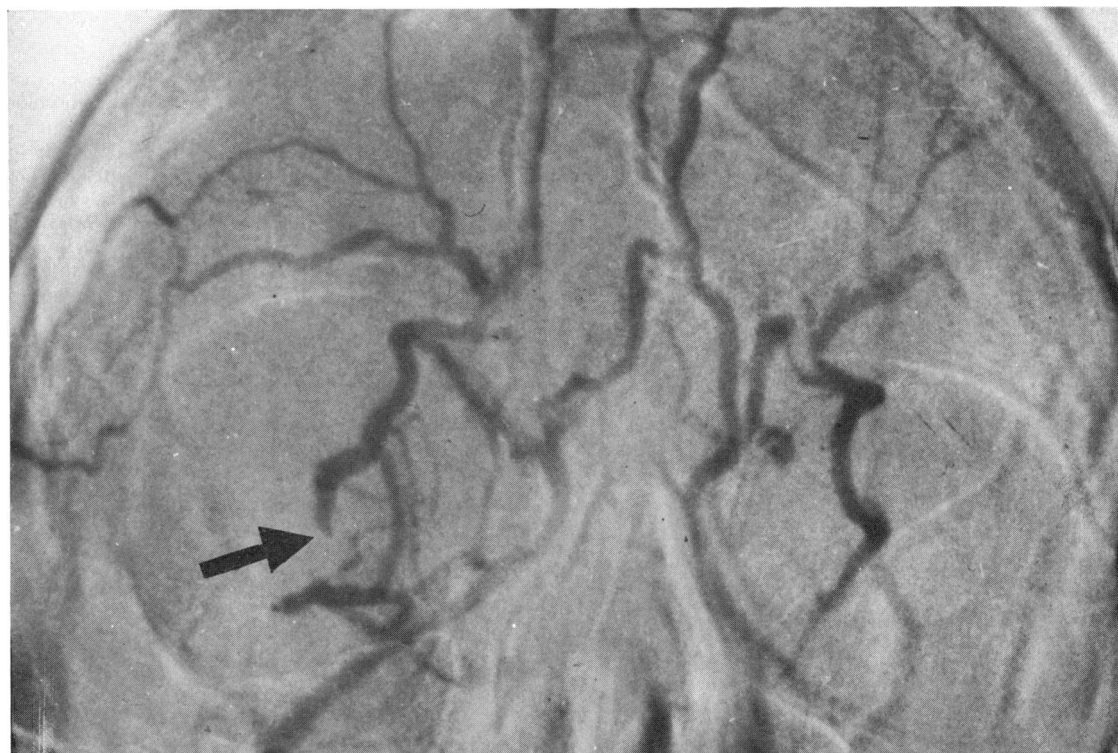


FIG. 2 *Orbital phlebogram, showing failure of filling of right superior ophthalmic vein in its distal part (arrowed) in Case 1*

Right

Left

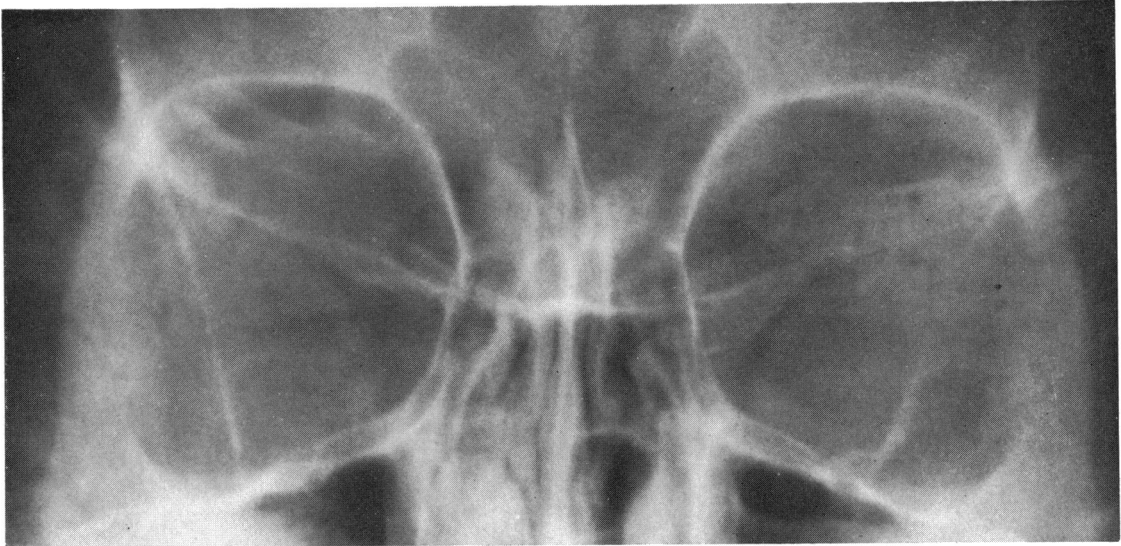

FIG. 3a Widened superior orbital fissure on the right in Case 2. See text for details

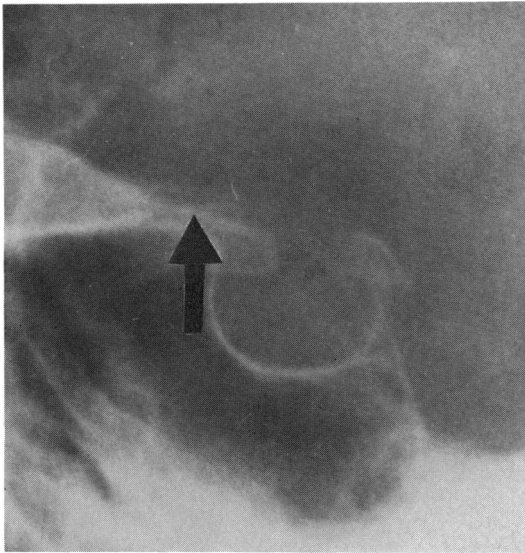


FIG. 3b Lateral view of the sella: right anterior clinoid process undercut and eroded (arrow)

#### Result

Postoperative radiotherapy was given to the orbit and afforded rapid relief of pain but the visual acuity remained at finger counting and there was complete ophthalmoplegia.

**Case 2, a 52-year-old housewife**, presented in May 1972, with a 5-day history of severe throbbing pain with swelling of the right eye. She had developed crampy abdominal pain accompanied by diarrhoea and vomiting 10 days previously. This pain and vomiting had persisted and the headache and then the ocular pain had followed. Most recently she had noticed some numbness around the right eye and diplopia.

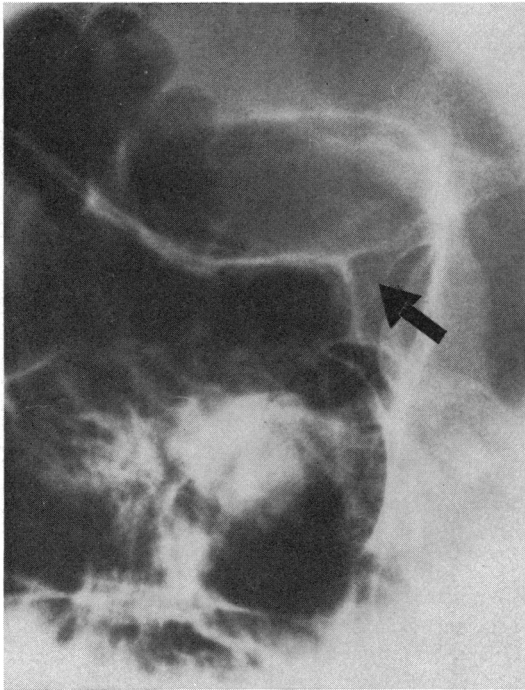
29 months previously she had developed pain behind the

right eye which settled spontaneously, but examination at Moorfields Eye Hospital 28 months previously had shown her to have a mild right lateral rectus palsy: the visual acuity then was 6/18. She had complained of horizontal diplopia accompanied by pain 11 months before which had settled after 3 months.

#### Examination

There was swelling of the right eye with ptosis. The corrected acuity was 6/12 in the right eye and 6/9 in the left. The fundi and fields were normal. There was a partial right third nerve palsy sparing the pupil, a complete right sixth nerve palsy, and partial involvement of the ophthalmic and maxillary branches of the trigeminal nerve on that

Right



Left

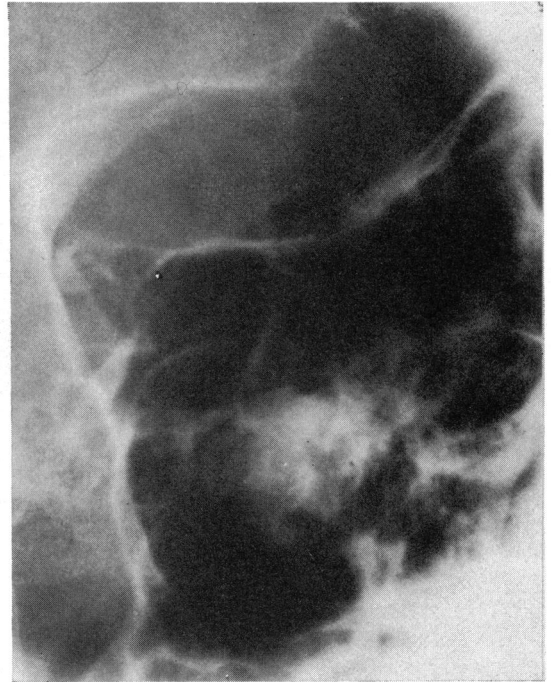


FIG. 4 Views of optic foramina in Case 2. Infero-lateral margin of the optic foramen eroded on right

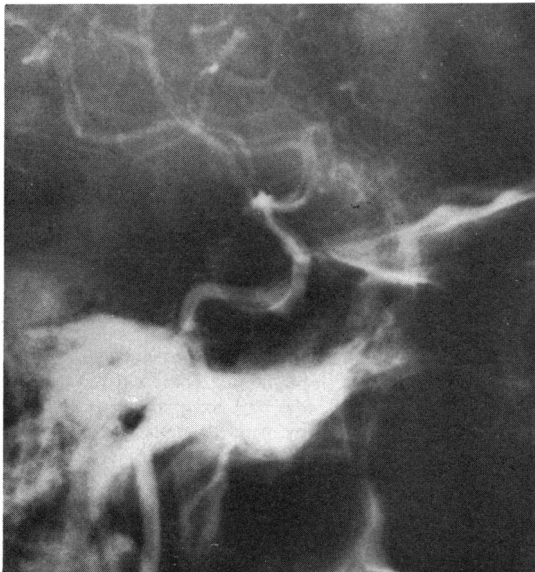


FIG. 5a Lateral view of arterial phase of right carotid arteriogram in Case 2. Note ragged appearance of artery in cavernous and supraclinoid parts

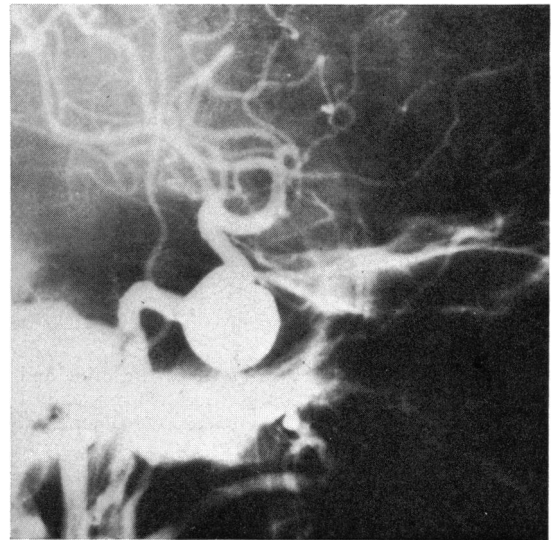


FIG. 5b Similar view of carotid arteriogram 12 weeks later, showing a large lobulated aneurysm arising from cavernous portion of carotid artery

side. The patient was distressed with pain and febrile, 99.6°F.

The differential diagnosis included a lesion in the cavernous sinus, either an aneurysm or perhaps secondary to a thrombotic lesion accompanying the systemic upset with fever and vomiting. Alternatives were an inflammatory granuloma or neoplasm.

#### Investigations

The blood count was normal with an erythrocyte sedimentation rate of 22 mm./1st hr. The blood cultures were sterile and agglutinins for *Brucella* and *Salmonella* negative. Rheumatoid screening and antinuclear factor tests and the blood Wassermann reaction were negative. Blood sugars were normal. The cerebrospinal fluid was normal (protein 40 mg. per cent.). Skull and orbital x rays showed erosion and undercutting of the right anterior clinoid process and erosion of the infero-lateral margin of the right optic foramen (Figs 3*b* and 4). The right superior orbital fissure was ill-defined and slightly expanded (Fig. 3*a*). To exclude an aneurysm a right carotid angiogram was performed; this showed a ragged narrowed segment of the cavernous and supraclinoid portions of the internal carotid artery which was thought compatible with granulomatous or neoplastic infiltration (Fig. 5*a*). An orbital phlebogram showed an obstruction at the distal end of the right superior ophthalmic vein with no filling of the right cavernous sinus.

#### Treatment

Initially she was given intravenous antibiotics and dexamethasone 16 mg. daily; subsequently the antibiotics were discontinued and the steroids maintained with prednisolone 60 mg. daily. By the fifth day of steroid treatment the pain had eased. The ophthalmoplegia improved slowly and steadily and the trigeminal sensory impairment improved. It was felt that this supported a diagnosis of an inflammatory granuloma although reservations were still held in view of the bone changes seen radiologically.

#### Progress

The steroids were gradually reduced, but on a dose of prednisolone 20 mg. daily the pain and swelling in the right eye recurred and she was re-admitted in August. She now had a proptosed right eye with corrected visual acuity of 6/6. She had a partial right third nerve palsy with some pupillary involvement. There was a complete right sixth nerve palsy but normal trigeminal sensation.

The blood count was normal and the erythrocyte sedimentation rate only 3 mm./1st hr. A repeat right carotid angiogram (12 weeks after the first) showed a large lobulated aneurysm arising from the cavernous part of the internal carotid artery (Fig. 5*b*). Subsequently the patient underwent ligation of the right common carotid artery; within half an hour of this the pain was relieved and later the proptosis disappeared and the ophthalmoplegia improved.

#### Discussion

Neither of these cases was quite typical of the Tolosa-Hunt syndrome, but on balance each was thought to

belong to this category because of the response to steroids. However, in both cases, the relief of pain (though gratifying to the patient) occurred after 4 to 5 days and not after the 24 or 48 hours characteristic of the Tolosa-Hunt syndrome (Smith and Taxdal, 1966; Mathew and Chandy, 1970), and in neither did the signs remit completely. Thomas and Yoss (1970), surveying 102 cases of the "parasellar syndrome" with painful ophthalmoplegia, pointed out that other types of pathology may be responsive to steroids, and cited a chordoma and giant cell tumour which responded well to such treatment.

Both our cases showed changes on the plain skull x rays with widening of the superior orbital fissure. In the second case there was undercutting and erosion of one anterior clinoid process (Fig. 3*b*) and erosion of the infero-lateral margin of the optic foramen (Fig. 4). These changes are strongly suggestive of an infraclinoid aneurysm and indeed this was the suspected diagnosis until the first angiogram was performed. This showed some irregular narrowing of the cavernous and supraclinoid portions of the internal carotid artery and some slight bulging of the anterior end of the cavernous portion (Fig. 5*a*). Narrowing of the intracavernous portion of the carotid artery has been described in cases of the Tolosa-Hunt syndrome (Tolosa, 1954; Lloyd, 1972; Sondheimer and Knapp, 1973; Hallpike, 1973).

However, the second carotid angiogram, 12 weeks later, showed a large lobulated aneurysm (1.5 × 2.5 cm.) arising from the cavernous portion of the internal carotid artery (Fig. 5*b*). Alpers and Ryan (1949) showed a large intracavernous carotid aneurysm which failed to fill at angiography and an explanation for the failure of filling may be the possible formation of thrombus within the aneurysm sac.

Other conditions may produce plain x-ray changes in the superior orbital fissure with widening, and Rischbieth and Bull (1958) suggested that the common lesions responsible were infraclinoid aneurysms, carotico-cavernous fistulae, pituitary tumours, meningiomata (sphenoid usually), and orbital tumours. They showed one case of an orbital granuloma with such widening of the fissure.

In addition to plain x-ray changes found in the routine and special views, carotid angiography may be necessary to exclude lesions such as aneurysms. Furthermore, orbital venography may also prove of major value in showing occlusion or displacement of the superior ophthalmic vein and failure of filling or encroachment of the cavernous sinus (Lloyd, 1972; Sondheimer and Knapp, 1973; Hallpike, 1973).

Tolosa-Hunt syndrome is not a pathological diagnosis and we should like to emphasize the observation of Thomas and Yoss (1970) that, in addition to inflammatory conditions, aneurysms and neoplasms may remit and relapse, particularly with steroid treatment. From our experience of these two, and

other more typical cases, we suggest that the diagnosis of Tolosa-Hunt syndrome should not be made without arteriography and venography, and that when there are atypical features—clinically, radiologically, or in response to treatment—the patient should be fully investigated.

### Summary

Two cases of painful ophthalmoplegia are described

which were initially thought to be examples of the Tolosa-Hunt syndrome. Both were partially responsive to steroid treatment. Subsequent investigations showed that in one case the condition was due to an aneurysm and in the other to a malignant lymphoma.

We are grateful to Mr. Duguid for referring Case 1 and Professor Barrie Jones for Case 2.

### References

- ALPERS, B. J., and RYAN, J. J. (1949) *J. nerv. ment. Dis.*, **109**, 220  
 HALLPIKE, J. F. (1973) *J. Neurol. Neurosurg. Psychiat.*, **36**, 486  
 HUNT, W. E., MEAGHER, J. N., LEFEVER, H. E., and ZEMAN, W. (1961) *Neurology (Minneapolis)*, **11**, 56  
 LLOYD, G. A. S. (1972) *Brit. J. Radiol.*, **45**, 405  
 MATHEW, N. T., and CHANDY, J. (1970) *J. neurol. Sci.*, **11**, 243  
 RISCHBIETH, R. H. C., and BULL, J. W. D. (1958) *Brit. J. Radiol.*, **31**, 125  
 SMITH, J. L., and TAXDAL, D. S. R. (1966) *Amer. J. Ophthalm.*, **61**, 1466  
 SONDHEIMER, F. K., and KNAPP, J. (1973) *Radiology*, **106**, 105  
 THOMAS, J. E., and YOSS, R. E. (1970) *Proc. Mayo Clin.*, **45**, 617  
 TOLOSA, E. (1954) *J. Neurol. Neurosurg. Psychiat.*, **17**, 300