

## Diabetic retinopathy with normal glucose tolerance

A. D. B. HARROWER AND B. F. CLARKE

*From the Diabetic and Dietetic Outpatient Department, Royal Infirmary, Edinburgh*

Various histological (Siperstein, Norton, Unger, and Madison, 1966; Siperstein, Unger, and Madison, 1968; Siperstein, Unger, and Madison, 1970) biochemical (Camerini-Davalos and Cole, 1970; Goto, Toyota, Takaku, Sato, and Irie, 1970), growth hormone (Soeldner, Sönksen, Gleason, and Boden, 1971) and insulin secretory (Cerasi and Luft, 1967) abnormalities have been reported in 'pre-diabetics' who, by definition, have normal standard glucose tolerance. Despite this, however, there have been only a few reports of typical diabetic complications, particularly retinal (Collens, Silverstein, and Dobkin, 1959; Levine, 1961; Linner, Svandborg, and Zelander, 1965; Johansen, 1969; Siperstein, 1969) or renal (Collens and others, 1959; Linner and others, 1965) angiopathy occurring in such subjects.

A patient who presented with typical diabetic exudative and proliferative retinopathy, but had normal standard glucose tolerance, is described. It was concluded that in such cases the diabetes was probably latent, the retinopathy being discovered during a period of natural or induced remission when glucose tolerance had reverted to normal.

### Case report

**A 62-year-old woman** was referred by her family doctor because of visual impairment which had developed gradually during the previous year. There had been no previous hospital admissions and apart from her presenting complaint she was asymptomatic. She had been obese since her teens, had not been known to be hypertensive, nor at any time in the past had she noted symptoms suggestive of diabetes mellitus. An older sister aged 71 years was a known maturity-onset diabetic attending the same clinic; she had been registered blind as a result of progressive exudative and proliferative diabetic retinopathy which had been present at diagnosis 10 years previously.

On examination, the patient was markedly obese, weighing 86.5 kg (standard weight 61 kg). She was hypertensive, with blood pressure 190/110 mmHg, but her general physical examination was otherwise unremarkable. The visual acuity was reduced to 6/18 in the

right eye and 6/36 in the left. Ophthalmoscopy revealed features characteristic of diabetic retinopathy with scattered microaneurysms and small discrete round 'blob' haemorrhages (particularly in the posterior polar regions of both retinae) and extensive clusters of yellowish, deep, hard exudates in the macular and perimacular regions. In addition, there was vitreous haze with a few small areas of neovascularization along the superior and inferior temporal vessels in the right eye and, in the left, a few areas of early neovascularization in relation to the superior temporal veins. There was also mild arterio-venous 'nipping' and a few superficial linear haemorrhages compatible with the hypertension. Unfortunately, because of vitreous haze it was not possible to take satisfactory photographs.

Laboratory investigations showed a normal two-hour postprandial blood glucose of 4.1 mmol/l (74 mg/100 ml) and full blood investigation—including haematology, blood urea, electrolytes, and uric acid—were all normal. Urine microscopy was normal and renal function satisfactory, there being no proteinuria, the creatinine clearances were 68 and 115 ml/min and the intravenous-pyelogram was normal. Chest radiology showed slight cardiac enlargement affecting the left ventricle, but the electrocardiogram was normal. Urinary vanillyl mandelic acid was normal and the urinary 17-hydroxycorticosteroid excretion was 20 mmol/day. Total plasma proteins were 73 g/l, albumin 40 g/l with a normal electrophoretic pattern. Immunoelectrophoresis of the globulins was normal, and tests for antinuclear factor were negative. Fasting cholesterol was 7 mmol/l, triglycerides 147 mmol/l, and free fatty acids 1050 mmol/l; a full clotting screen was normal. The standard oral glucose tolerance test, using a 50 g glucose load, which was repeated after an interval of seven days were both normal apart from a slight increase in the one-hour blood glucose value in the second test (Table I). Intravenous tolbutamide (Unger and Madison, 1958), and cortisone augmented glucose tolerance tests (Fajans and Conn, 1954) were likewise normal (Table I).

A renal biopsy showed, on light microscopy, hyaline changes in the arterioles compatible with hypertension, but, unfortunately the tissue obtained was inadequate for a satisfactory assessment of diabetes.

The hypertension was controlled with debrisoquine 45 mg daily and treatment was begun with clofibrate, 2.0 g daily, for the exudative element of the retinopathy (Duncan, Cullen, Ireland, Nolan, Clarke, and Oliver, 1968; Cullen, Town, and Campbell, 1974). During the subsequent three years there were vitreous haemorrhages in both eyes, and three years later the patient's visual acuity was reduced to counting fingers in the

**Table I** Blood glucose mmol/l (mg/100 ml) during tolerance tests of oral glucose, cortisone-augmented glucose, and tolbutamide

Oral glucose tolerance test (mmol/l (mg/100 ml))	Time (hours)						
	F	$\frac{1}{2}$	1	$1\frac{1}{2}$	2	$2\frac{1}{2}$	3
Test 1	5.0 (90)	9.7 (175)	7.7 (138)	3.8 (68)	2.7 (48)	—	—
2	4.9 (88)	8.4 (152)	11.4 (206)	8.1 (146)	5.3 (96)	4.0 (72)	2.7 (48)
<i>Cortisone-augmented glucose tolerance test</i>							
Test 1	5.9 (106)	11.3 (203)	10.8 (194)	7.7 (138)	4.7 (85)	4.0 (72)	2.7 (48)
2	6.4 (115)	12.5 (225)	11.1 (200)	5.1 (92)	5.1 (92)	—	—
<i>Tolbutamide tolerance test</i>							
	Time (minutes)						
	F	20	30				
Percentage decrease in blood glucose	5.0 (90)	3.6 (65)	3.1 (55)				
		28	38				

right eye but remained at 6/36 in the left despite two further vitreous haemorrhages. The Figure shows the current retinal appearances in the right eye with microaneurysms, haemorrhages, extensive hard exudates, and fibrosis. There had been a further vitreous haemorrhage in the left eye making photography impossible. The standing blood pressure is 200/100—180/90 mmHg and her weight has decreased by 12 kg. Random fasting and postprandial blood glucose values have been checked frequently and have remained well within the normal limits (range 3.6–5.8 mmol/l) (65–104 mg/100 ml) during this period and a repeated cortisone glucose tolerance test was similar to that obtained originally (Table I).

### Discussion

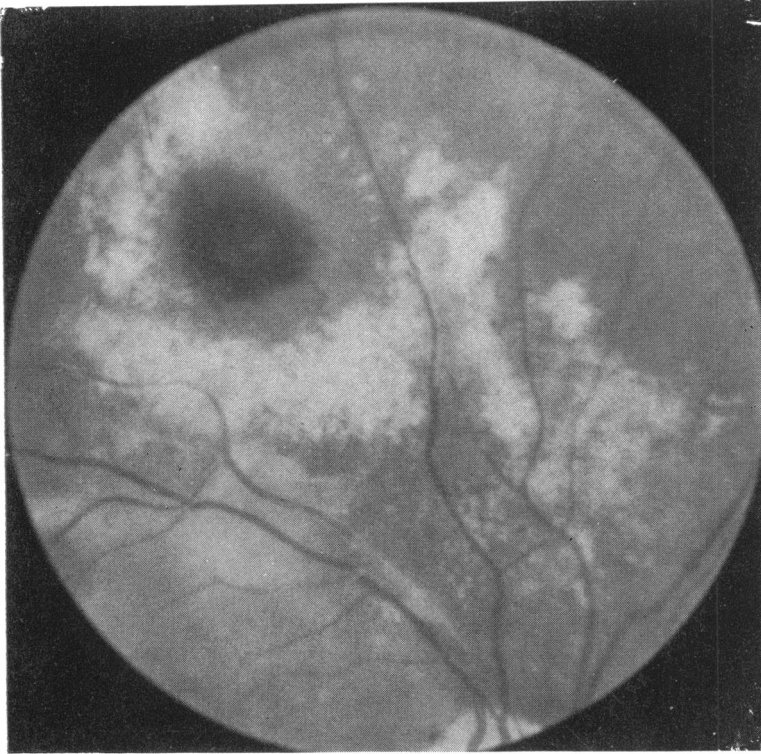
There is a paucity of reports of typical diabetic retinopathy in patients with normal glucose tolerance (Table II) which might be expected to occur more commonly if biochemical and histological abnormalities precede glucose intolerance as has been frequently observed (Siperstein and others, 1966, 1968, 1970; Cerasi and Luft, 1967; Camerini-Davalos and Cole, 1970; Goto and others, 1970; Soeldner and others, 1971).

Typical diabetic retinopathy at the time of diagnosis is, however, well recognized and has been variously reported as occurring in 4 to 15 per cent of patients (Waite and Beatham, 1935; Lawrence, 1951; Aarseth, 1953; Lundbaek, 1955; Kornerup, 1958; Pyke and Roberts, 1959; Soler, Fitzgerald, Malins, and Summers, 1969). In such cases the diabetes has probably been long standing and undiagnosed because of the mildness or absence of symptoms. Indeed, it has been calculated that for persons diagnosed over the age of 50 years, the mean length of time between the appearance of

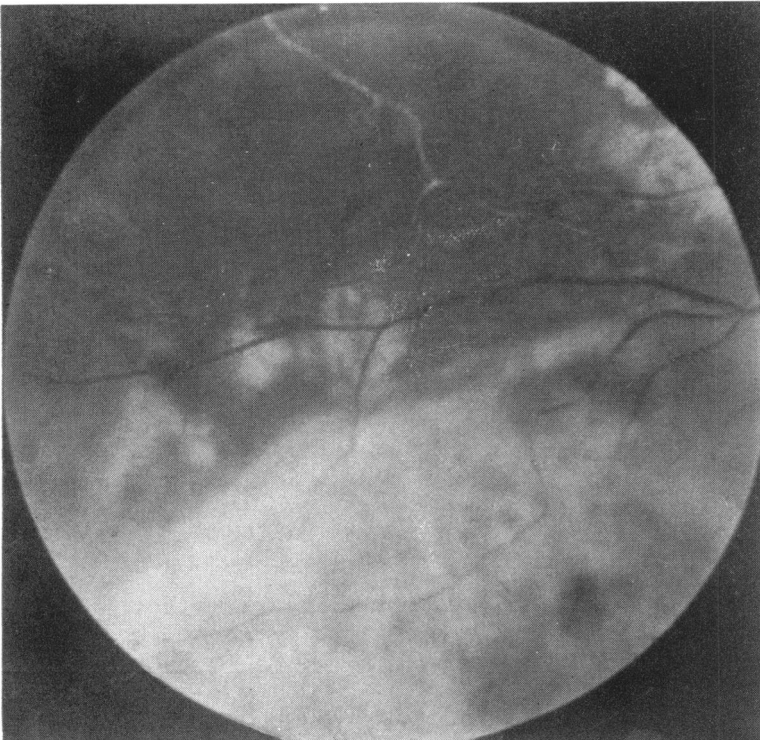
impaired carbohydrate tolerance and diagnosis is at least 10 years (Anderson, 1966).

There have been reports of minimal capillary basement membrane changes in various tissues such as ear lobe (Camerini-Davalos, 1965) and muscle (Siperstein and others, 1966, 1968, 1970) in 'pre-diabetics'. The demonstration of impaired insulin release in the close relatives of diabetics who have normal standard glucose tolerance (Cerasi and Luft, 1967), suggests that biochemical abnormalities may be present for some time before the development of overt diabetes and it is possible that the basement membrane changes are secondary to these. However, Bloodworth, Engerman, Camerini-Davalos, and Powers (1970) also using thigh muscle biopsies found no difference between the capillary basement membrane thicknesses in 'pre-diabetics' and their controls. Østerby (1970, 1972) failed to demonstrate significant basement membrane thickening in glomerular capillaries from recently diagnosed young diabetics, in whom the date of onset of diabetes could accurately be obtained. By studying successive renal biopsies during the next  $2\frac{1}{2}$  years, however, she showed a progressive increase in basement membrane thickness.

The patient we describe had a retinopathy which showed the typical combination and distribution of features characteristic of diabetes and with no evidence of veno-occlusive disease, hyper-viscosity syndromes, retinal vasculopathies, or other conditions known to produce changes which may resemble diabetic retinopathy. The fact that a sister, with confirmed diabetes, had similar retinal changes at diagnosis may indicate an enhanced familial predisposition to diabetic retinopathy. In such cases the patients are probably latent diabetics,



**FIGURE** *Retinal photographs showing microaneurysms, haemorrhages, hard exudates, and fibrosis in the right eye*



**Table II** *Reports of patients with normal glucose tolerance and typical diabetic retinopathy*

<i>Reference</i>	<i>Sex</i>	<i>Age</i>	<i>FH of diabetes</i>	<i>Retinal appearance</i>	<i>Other angiopathy</i>	<i>Comments</i>
Collens and others, (1959)	Male	42	Yes	Hard exudates, microaneurysms, haemorrhages	Nodular glomerulosclerosis	Obese. BP 180/100. Diabetes diagnosed 17 years before, but GTT normal at time of report. Abnormal cortisone-augmented GTT
Levine (1961)	Female	'early forties'	?	Haemorrhages proliferation	—	8 GTT ± cortisol. 1 abnormal
Linner and others, (1965)	Female	60	Yes	Microaneurysms and dot haemorrhage, small hard exudates	No typical diabetic features on renal biopsy	Normotensive
Johansen (1969)	Male	65	Yes	Microaneurysms blob haemorrhages and new vessels	Diffuse glomerulosclerosis	Diabetes diagnosed 5 years before when patient obese. GTT normal, but became abnormal after weight gain
Siperstein (1969)	Female	54	Yes	Microaneurysms and haemorrhages	Quadriceps muscle biopsy showed increased capillary basement membrane thickness	GTT normal on repeated testing
Present case	Female	62	Yes	Microaneurysms and blob haemorrhages hard exudates, new vessels	—	Obese. BP 190/110

in whom retinopathy has been discovered during a period of natural or induced remission when standard glucose tolerance has reverted to normal. In the patient described genetic predisposition, the exacerbating effect of hypertension (Kornerup, 1958; Hollenhorst, 1962; Field, 1970), and insulin resistance caused by obesity may have been contributory factors.

### Summary

A case is reported of a patient with typical diabetic

retinopathy, but with normal glucose tolerance. Previously reported cases are reviewed and it is concluded that in such patients the diabetes is probably latent, the retinopathy being discovered during a period of natural or induced remission.

We are grateful to Dr L. J. P. Duncan for permission to study this present case and for his advice and criticism.

Dr J. F. Cullen was helpful in the assessment and management of the retinal changes and Dr D. Thomson and Dr J. T. Ireland advised us on the renal biopsy material.

### References

- ANDERSON, T. W. (1966) *Diabetes*, **15**, 160  
AARSETH, S. (1953) *Acta med. scand.*, suppl. 281  
BLOODWORTH, J. M. B., ENGERMAN, R. L., CAMERINI-DAVALOS, R. A., and POWERS, K. L. (1970) 'Advances in Metabolic Disorders', suppl. 1. Early Diabetes, ed. R. A. Camerini-Davalos and H. S. Cole, p. 261. Academic Press, New York and London  
CAMERINI-DAVALOS, R. A. (1965) *Med. Clin. N. Amer.*, **49**, 865

- , and COLE, H. S. (1970) 'Advances in Metabolic Disorders', suppl. 1. Early Diabetes, ed. R. A. Camerini-Davalos and H. S. Cole, p. 321. Academic Press, New York and London
- CERASI, E., and LUFT, R. (1967) *Acta endocr. (Kbh.)*, **55**, 278
- COLLENS, W. S., SILVERSTEIN, J. N., and DOBKIN, G. B. (1959) *Ann. intern. Med.*, **50**, 1282
- CULLEN, J. F., TOWN, S. M., and CAMPBELL, C. J. (1974) *Trans. ophthalm. Soc. U.K.*, **95**, 554
- DUNCAN, L. J. P., CULLEN, J. F., IRELAND, J. T., NOLAN, J., CLARKE, B. F., and OLIVER, M. F. (1968) *Diabetes*, **17**, 458
- FAJANS, S. S., and CONN, S. W. (1954) *Ibid.*, **3**, 296
- FIELD, R. A. (1970) *J. Amer. med. Ass.*, **214**, 1126
- GOTO, Y., TOYOTA, T., TAKAKU, I., SATO, Y., and IRIE, M. (1970) 'Advances in Metabolic Disorders', suppl. 1, Early Diabetes, ed. R. A. Camerini-Davalos and H. S. Cole, p. 261. Academic Press, New York and London
- HOLLENHORST, R. W. (1962) *Trans. Amer. Acad. Ophthalm. Otolaryng.*, **66**, 166
- JOHANSEN, K. (1969) *Amer. J. Med.*, **47**, 487
- KORNERUP, T. (1958) *Acta ophthalm. (Kbh.)*, **36**, 87
- LAWRENCE, R. D. (1951) *Proc. roy. Soc. Med.*, **44**, 742
- LEVINE, R. (1961) *Surv. Ophthalm.*, **6**, 495
- LINNER, E., SVANDBORG, A., and ZELANDER, T. (1965) *Amer. J. Med.*, **39**, 298
- LUNDBAEK, K. (1955) *Acta med. scand.*, **152**, 53
- ØSTERBY, R. (1970) 'Advances in Metabolic Disorders', suppl. 1. Early Diabetes, ed. R. A. Camerini-Davalos and H. S. Cole, p. 261. Academic Press, London and New York
- (1972) *Diabetologia*, **8**, 84
- PYKE, D. A., and ROBERTS, D. ST. C. (1959) *Acta med. scand.*, **163**, 489
- SIPERSTEIN, M. D. (1969) 'Pathogenesis of Diabetes Mellitus', ed. E. Cerasi and R. Luft, p. 81. Almqvist and Wiksell. Förlag AB, Stockholm
- , NORTON, W., UNGER, R. N., and MADISON, L. L. (1966) *Trans. Ass. Amer. Phycns.*, **79**, 330
- , UNGER, R. H., and MADISON, L. L. (1968) *J. clin. Invest.*, **47**, 1973
- , ———, and ——— (1970) 'Advances in Metabolic Disorders', suppl. 1. Early Diabetes, ed. R. A. Camerini-Davalos and H. S. Cole, p. 261. Academic Press, New York and London
- SOELDNER, J. S., SÖNKSEN, P. H., GLEASON, R. E., and BODEN, G. (1971) 'The Action of Hormones, Genes to Population', eds P. P. Foa, M. L. Foa, and A. J. Whitby, p. 421. Thomas, Springfield, Ill.
- SOLER, M. G., FITZGERALD, M. G., MALINS, J. M., and SUMMERS, R. O. C. (1969) *Brit. med. J.*, **3**, 567
- UNGER, R. H., and MADISON, L. L. (1958) *J. clin. Invest.*, **37**, 627
- WAITE, J. H., and BEATHAM, W. P. (1935) *New Engl. J. Med.*, **212**, 367 and 429