

Corneal neovascularization treated with argon laser

PAUL M. H. CHERRY¹ AND ALEC GARNER²

From the Pocklington Eye Transplantation Research Unit, Toronto¹, and the Pathology Department, Institute of Ophthalmology, London²

Corneal neovascularization can be troublesome, especially in an eye which is to have a corneal graft. A corneal transplant is more likely to be rejected in a vascularized than a non-vascularized cornea. In this and many other clinical situations, therefore, it is desirable that corneal new vessels be obliterated. Many treatments have been suggested, including corticosteroids, irradiation, thiotepa, cryotherapy, photocoagulation, cysteine, chondroitin sulphuric acid, and dextran. One of us (PMHC) was, we believe, the first to report the use of the argon laser in the treatment of corneal neovascularization in man (Cherry, Faulkner, Shaver, Wise, and Witter, 1973). This was an open trial in four patients, two with chemical burns of the cornea and two with herpes simplex keratitis. There were two failures, one success, and one partial success. It was impossible to draw any definite conclusions from so few cases, and it was therefore decided to embark on a controlled trial in rabbits.

Materials and methods

One of the eyes of each of 11 pigmented Dutch rabbits were used as both case and control. Each animal weighed about 2 kg. Two 7' o' or 8' o' black silk sutures were placed in the cornea about 3 mm in from the limbus, one at 10 o'clock and one at 2 o'clock. The animals were anaesthetized with intravenous sodium pentobarbitone. Usually the cornea was perforated during suture placement with slight resultant loss of aqueous and shallowing of the anterior chamber. In every case the chamber quickly re-formed and no anterior synechiae to the corneal perforation ensued. The sutures were used as the stimulus for corneal new vessel formation, which took about three weeks to reach the sutures from the limbus. When neovascularization was adequate the sutures were removed. Corneal fluorescein angiograms were then obtained under anaesthesia to document accurately the position of the vessels and determine which were arteries and which were veins. A modified Zeiss photoslit lamp camera was used for the angiography with a Balzar interference excitation filter (FITC 4) and a Kodak Wratten 15 barrier filter.

Address for reprints: Paul M. H. Cherry, FRCS, Department of Ophthalmology, University of Toronto, 1 Spadina Crescent, Toronto, Canada

Because of the positioning of the sutures two sectors of vessels were stimulated, one from the upper nasal limbus and the other from the upper temporal limbus. Two sectors of vessels in the same eye were needed so that one could be used as a control and the other as the argon-treated area. The argon laser therapy was performed under sodium pentobarbitone anaesthesia and repeated at intervals of several days until the vessels were completely occluded. (Only one animal, no. 2, was killed before the treated vessels were occluded. This was done deliberately to obtain some histological specimens very soon after argon laser treatment.)

The technique of laser therapy was as follows. Both arteries and veins were treated as they crossed the limbus and 2 to 3 mm to the corneal side of the limbus. The first treatment of each vessel was 'downstream' and the second 'upstream', thus trapping a column of blood which was able to absorb subsequent treatment of the vessel between these two points. Intravenous fluorescein was usually given immediately before the argon laser therapy so that more laser energy would be absorbed by the corneal vessels as they were being treated (Kohner, personal communication). Intravenous fluorescein was repeated during the treatment session to document the success or failure of each stage of the treatment. When the treated sector of corneal vessels was occluded the fluorescein angiograms were repeated at intervals of several days to make sure that the control vessels were still patent. The iris damage during the experiment was also documented with fluorescein angiography until the changes were stabilized. The instrument used for the argon laser therapy was manufactured by Coherent Radiation, Palo Alto, California, USA. The settings were usually 50 μ m spot size, 0.2 s exposure time, and 150 mW energy (see Table).

When the animals were killed their treated eyes were enucleated for histopathological study. Just before some of the animals were killed the pupil of the treated eye was dilated and the fundus examined with the indirect ophthalmoscope to determine if there was any visible retinal damage. No damage was found.

Results

The results are summarized in the Table. The argon laser was effective in obliterating corneal new vessels, provided a continued stimulus for revascularization of the cornea was not present. An active stromal infiltrate in the area of the suture

Table Results of Argon laser treatment of corneal neovascularization in 11 pigmented Dutch rabbits

Rabbit no.	Sutures removed on day :	Argon laser treatment on days :	No. of treatments	No. of shots at each treatment	Power setting (mW)	Animal killed on day :	Control vessels patent at death of animal	Eye	Nasal or temporal vessel sector treated
1	o	9, 10, 13, 14	4	230 134 150 226 <hr/> 740	272 at 100 92 at 200 150 at 250 226 at 300 <hr/> 740	164	No (gone by day 132)	Right	Temporal
2*	o	16	1	350	200	20	Yes	Left	Temporal
3	o	0, 3, 10, 13, 17, 42	6	745 471 382 586 291 394 <hr/> 2869	2283 at 150 586 at 250	80	No (gone by day 69)	Left	Nasal
4	o	0, 7, 10	3	375 99 312 <hr/> 786	150	77	Yes	Right	Nasal
5	o	11, 21	2	467 280 <hr/> 747	150	91	Yes	Left	Nasal
6	o	3, 7, 14	3	368 451 320 <hr/> 1139	150	25	Yes	Right	Temporal
7	o	0, 7	2	88 194 <hr/> 282	150	18	No (gone by day 14)	Left	Temporal
8	o	0, 4, 28	3	2299 1456 567 <hr/> 4322	100	32	Yes	Right	Temporal
9	o	7, 14, 18	3	482 307 239 <hr/> 1028	987 at 150 41 at 250	63	Yes	Left	Nasal
10	o	3, 7, 14	3	249 415 316 <hr/> 980	664 at 150 316 at 200	25	Yes	Left	Temporal
11	o	3, 8	2	833 288 <hr/> 1121	150	46	Yes	Right	Nasal

*Rabbit deliberately killed before occlusion to study histopathology very soon after argon laser treatment

†Forty-one burns were at 100 µm spot size not 50 µm

scar was apparent during the sessions of argon laser therapy in rabbits 3 and 8, and these were the two animals which required the greatest number of laser shots (2869 and 4322 at six and three treatment sessions respectively). In both these animals, however, the laser-treated sector was successfully occluded after the suture scar inflammation had resolved.

When occluding the vessels an effort was made to use the minimum amount of argon laser energy possible, thus limiting the iris damage. The minimum spot size (50 μm) was used (except for 41 shots of 100 μm spot size in rabbit 9) together with an exposure time of 0.2 s: 150 mW of energy was usually selected, but 100, 200, 250, and 300 mW were occasionally used. Rabbit 8 had only 100 mW treatment, and we suggest that this power meter setting is adequate so long as no stimulus for revascularization of the cornea remains.

We hoped that it would be enough to treat only the arteries and that the veins, deprived of their blood supply, would then spontaneously regress. But this was not found to be the case in rabbit 11 (Figs 1-5), in which all arteries in the treated sector were successfully obliterated by day 3 after suture removal; the veins were not treated. However, when examined on day 8 the vein marked V_2 was carrying blood to the suture scar from the limbus and had

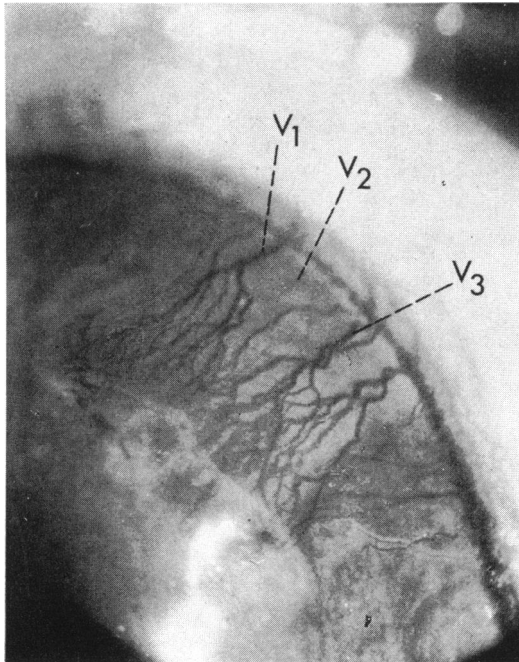


FIG. 1 Rabbit 11. Pretreatment photograph of 2 o'clock sector of vessels. V_1 , V_2 , and V_3 are veins

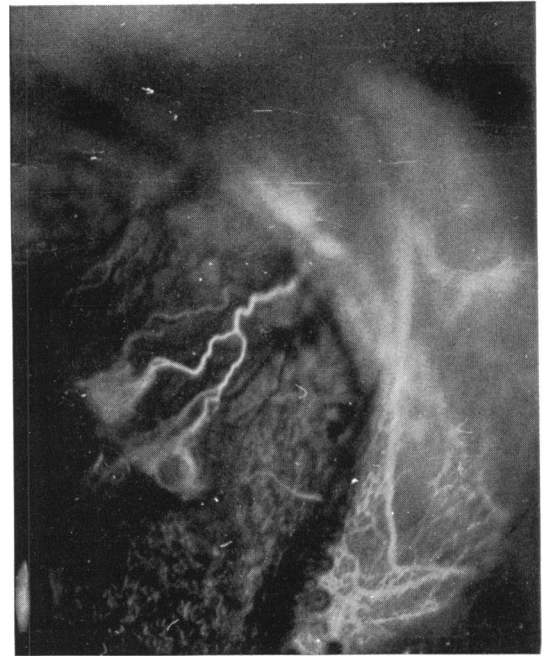


FIG. 2 Rabbit 11. Pretreatment fluorescein angiogram, right eye, showing 2 o'clock sector of vessels in arterial phase

thus become the afferent part of a venous loop. V_2 was obliterated with the argon laser on day 8. The rabbit was next seen on day 11, when V_3 was the afferent limb of a venous loop and V_1 the efferent limb (Fig. 5). By this time the vessels were of very fine calibre and V_3 and V_1 spontaneously disappeared by day 14. Thus, two examples of retrograde flow were demonstrated in this rabbit, and it is therefore not sufficient to treat only arteries when attempting to obliterate corneal new vessels.

Before each session of argon laser therapy fluorescein was given intravenously to ensure that maximum laser energy would be taken up by the corneal blood vessels (Kohner, personal communication). The smaller and less obvious vessels could also be visualized and therefore treated. Additionally, fluorescein given intravenously several times during each treatment helped to show when the vessels had been occluded.

Apart from in rabbit 2, the laser therapy eventually closed all the treated sectors of vessels. This rabbit was purposely killed four days after the first and only session of laser therapy in order that histopathology of the acute lesion might be observed. In the remaining 10 rabbits the average number of treatment sessions required to obliterate the vessels was 3.1. The animals were then ob-

served for varying periods before being killed to make sure that the control vessels remained patent and did not disappear spontaneously. The control vessels in rabbits 1, 3, and 7 did disappear spontaneously at days 118, 27, and 7 respectively after successful occlusion of the treated vessels. The

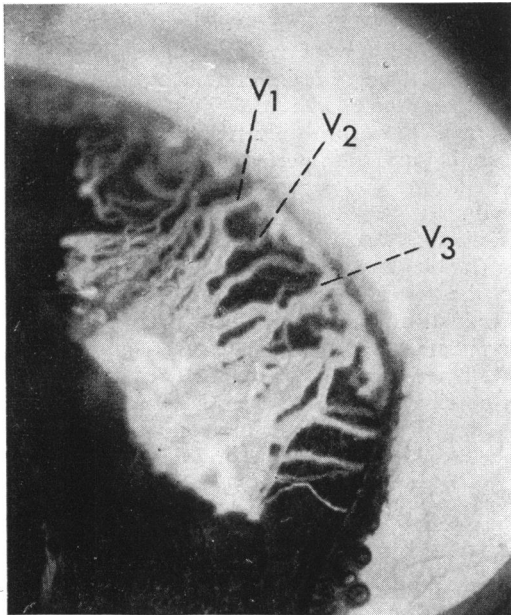


FIG. 3 As for Fig. 2 showing 2 o'clock sector of vessels in venous phase. V_1 , V_2 , and V_3 are veins

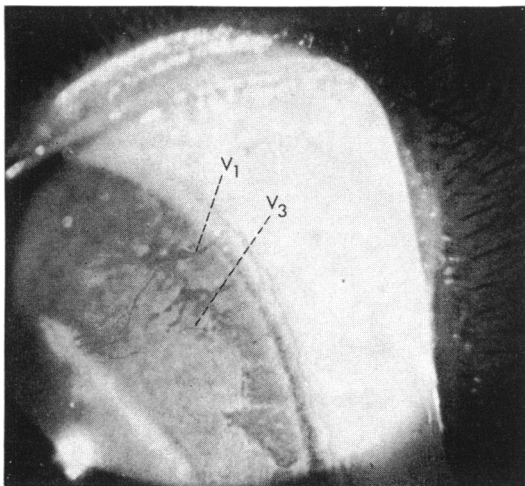


FIG. 4 Rabbit 11. Photograph day 11 after argon laser treatment. Veins V_1 and V_3 are only vessels remaining patent

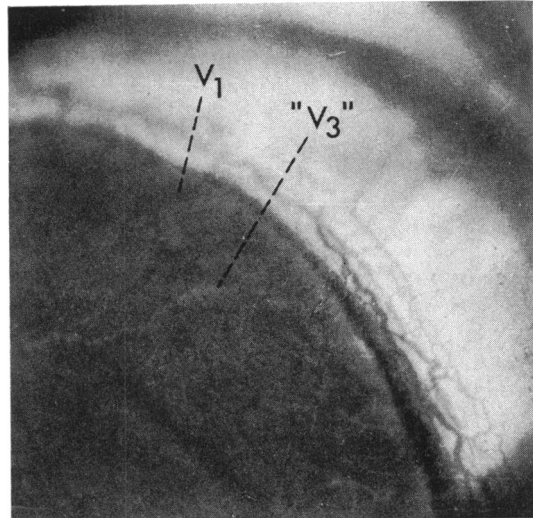


FIG. 5 Rabbit 11. Fluorescein angiogram day 11 after argon laser treatment. " V_3 " is afferent limb and V_1 efferent limb of a venous loop. " V_3 " has filled from limbus and is beginning to empty into V_1

control vessels of the other rabbits remained patent until they were killed.

Changes in the iris were observed at the time of laser application in all animals. Energy not absorbed by the corneal blood vessels reached the iris and caused a pigment disturbance on the surface. A black patch appeared on the surface of the iris underneath the treated vessel and sometimes the iris surface became slightly excavated, but by about two months the excavation was almost imperceptible and the hyperpigmentation of the black patch was less marked. In rabbit 1 these iris changes were accompanied by very slight ectropion uveae.

Fluorescein angiography was performed on the non-vascularized eye of rabbit 9 two to three hours after the application of 601 (108 mW, 50 μm , 0.2 s) argon laser burns to the iris (Figs 6-9). The black patches did not fluoresce, the pigment, acting as a curtain, preventing fluorescence from the underlying iris stromal vessels. Dots of fluorescein leakage, however, appeared from many iris vessels, including those at the edge of the black patches, within 30 seconds of intravenous fluorescein injection (Fig. 8), and these dots slowly increased in size. There was also a massive outpouring of aqueous from the ciliary body. Thirty to 60 seconds after intravenous fluorescein injection fluorescent aqueous started to enter the anterior chamber through the pupil, and after about five minutes the iris could hardly be seen in blue light because of the large amount of

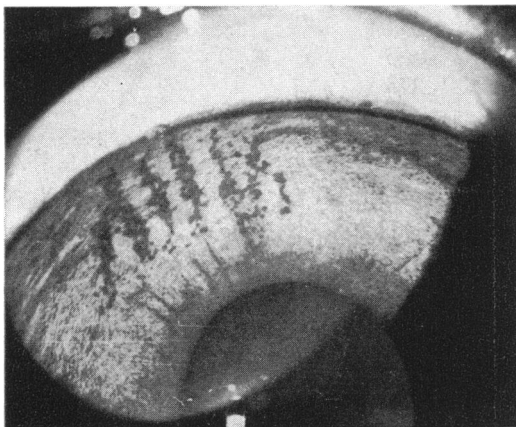

FIG. 6 Rabbit 9. Photograph of right eye two to three hours after application of 601 (100 mW, 50 μ m, 0.2 s) argon laser burns to iris (corneal vessels not induced in this eye). Note black patches of iris damage

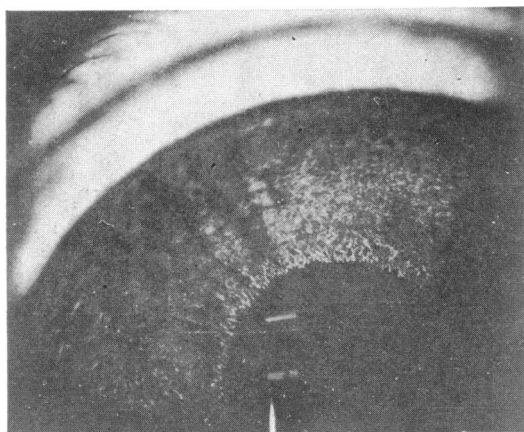


FIG. 7 As for Fig. 6. Black patches of iris damage mask fluorescence (15 s post-injection)

fluorescent aqueous in the anterior chamber. The rabbit's other eye was used for comparison and there the entry of fluorescent aqueous into the anterior chamber via the pupil was much less. Three days after the application of the laser the amount of aqueous produced by the ciliary body was much less, and a week after the laser treatment it had returned to normal (Fig. 10). The focal iris leakage seen two to three hours after treatment (Figs 8, 9) had ceased.

PATHOLOGY

The corneal blood vessels seen in histological sections were generally in the superficial stroma

immediately beneath the epithelium, although in three animals (1, 4, and 7) vascularization was more obvious in the deep or midstroma. The vessels on the treated side of the cornea were variably surrounded by scanty macrophages, lymphocytes, and proliferated fibrous scar tissue. In most instances the vessel would appear to have been completely destroyed (Fig. 11a, b), while occasional less severely damaged vessels were occluded by thrombus. Two corneae (rabbits 8 and 10) showed small solitary aggregates of necrotic debris associated with trivial leucocytic infiltration between Descemet's membrane and the lining endothelium (Fig. 12). These probably represented the site of perforation into the anterior chamber of the sutures inserted into the cornea to induce vascular ingrowth.

Iris lesions were included in the sections of four eyes (rabbits 2, 8, 9 (right eye), and 11). In each case they presented as minute foci of stromal pigment disturbance which had given rise to tiny accumulations of melanin-laden macrophages near to the anterior surface of the iris (Fig. 11c). There was no sign of residual necrosis or inflammation, and the pigment epithelium on the posterior surface of the iris was intact in every instance.

Discussion

The power of the argon laser is confined to the green and blue regions of the spectrum with 80 per cent of the total confined to two wavelengths, 5145 Å (green) and 4880 Å (blue) (Campbell, Rittler, Swope, and Wallace, 1969). Energy at these wavelengths is transmitted by the optical system of the eye with relatively low absorption and therefore high efficiency (Meyer-Schwickerath,

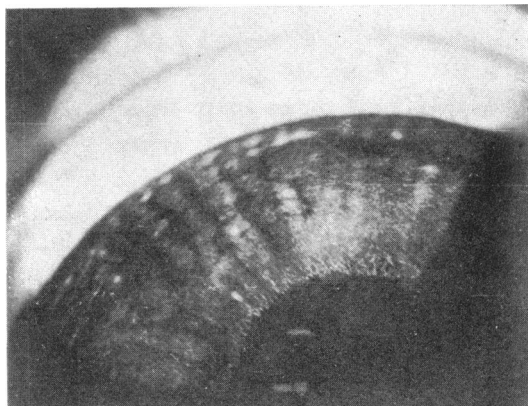


FIG. 8 As for Fig. 6. Dots of fluorescein leakage from many iris vessels including those at edge of black patches (30 s post-injection)

1960). Pigment epithelium absorbs a high degree of energy at these wavelengths, and a significant portion of the energy is also absorbed by blood (Geeraets, William, Chan, Ham, Guerry, and Schmidt, 1962).

The argon laser was effective in occluding suture-induced corneal new vessels, the sutures having been removed before treatment with the laser. In rabbits 3 and 8 an active infiltrate of the stromal suture scar remained after suture removal, and the argon laser did not occlude the vessels in these animals until the inflammation subsided. We therefore suggest that the argon laser can occlude corneal blood vessels in rabbits so long as there is no, or very little, stimulus remaining for revascularization. In these optimum circumstances very little laser energy has to be used to occlude the vessels (50 μm , 100–150 mW, 0.2 s).

The most obvious complication of argon laser therapy in these 11 Dutch rabbits was damage to the iris. This must particularly be borne in mind because of the iris route of corneal graft rejection (Jones, 1973). If the argon laser is to be used extensively to occlude corneal new vessels in man we think it will be to occlude corneal new vessels before keratoplasty. Therefore if argon laser therapy to corneal vessels is complicated by an increased chance of corneal graft rejection by the iris route it must surely be discarded as a means of treating corneal new vessels in these circumstances. Black iris patches, 'shadows' of the treated corneal vessels, appeared immediately on treating the vessels in our Dutch rabbits and were caused by any laser energy not taken up by the corneal vessels.

Unger, Perkins, and Bass (1974) showed that laser irradiation of the iris in pigmented Dutch rabbits is followed by a transient increase in intraocular pressure of up to 45 mmHg within 10 minutes, with a return to normal within 2 hours. They suggested that this increase is mediated by E-type prostaglandins. They also found a breakdown of the blood-aqueous barrier with increased permeability to plasma proteins occurring in the ciliary processes and not in the iris. Fluorescein angiography performed in our experiment confirmed the findings by Unger and others (1974). Angiograms two to three hours after the laser treatment showed no fluorescence through the surface black patches on the iris but there were focal dots of fluorescent leakage from many iris vessels, including those at the edge of the black patches (Figs 8, 9). This leakage persisted for a few days but had always resolved within a week. There was also massive outpouring of fluorescent aqueous from the ciliary processes, through the pupil, in the fluorescein angiograms two to three

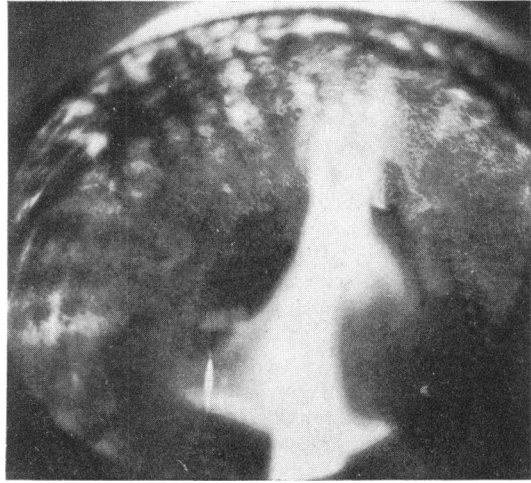


FIG. 9 As for Fig. 6. Fluorescent aqueous beginning to pour into anterior chamber through pupil. Dots of fluorescein leakage from many iris vessels including those at edge of black patches. Black patches of iris damage mask fluorescence (45 s post-injection)

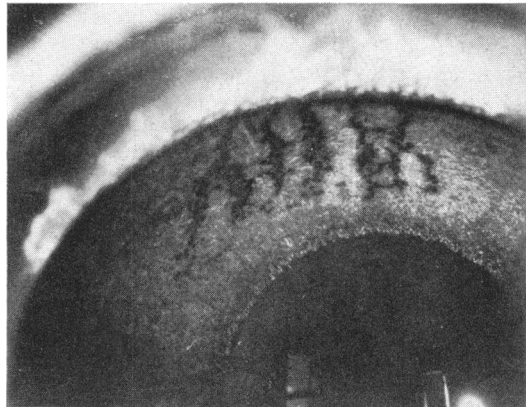


FIG. 10 Rabbit 9. Fluorescein angiogram of right eye seven days after argon laser treatment to iris. Black patches of iris damage mask fluorescence. There is now no focal leakage of fluorescein from the iris vessels (about 1 min post-injection)


hours after laser treatment. The intraocular pressure was not measured at this time or immediately after laser treatment, but presumably it was transiently raised. The breakdown of the blood-aqueous barrier resolved slowly and was also back to normal within a week.

Histopathological examination of the iris lesions showed minute foci of stromal pigment disturbance which had given rise to tiny accumulations of melanin-laden macrophages near the anterior

surface of the iris (Fig. 11c). There was no sign of residual necrosis or inflammation and the pigment epithelium on the posterior surface of the iris was intact in every instance. This suggests that the iris damage stabilizes about one week after argon laser treatment of corneal blood vessels in pigmented Dutch rabbits and should not, therefore, necessarily contraindicate the use of the argon laser to treat corneal blood vessels in patients being considered for keratoplasty. The corneal vessels could be occluded about two weeks before the proposed keratoplasty, thus allowing the iris time to stabilize before the operation. It must also be mentioned that further work by Unger and Brown (personal communication) has shown, so far, that the blood-aqueous barrier in humans is much more stable after ruby laser therapy of the iris than that of pigmented Dutch rabbits.

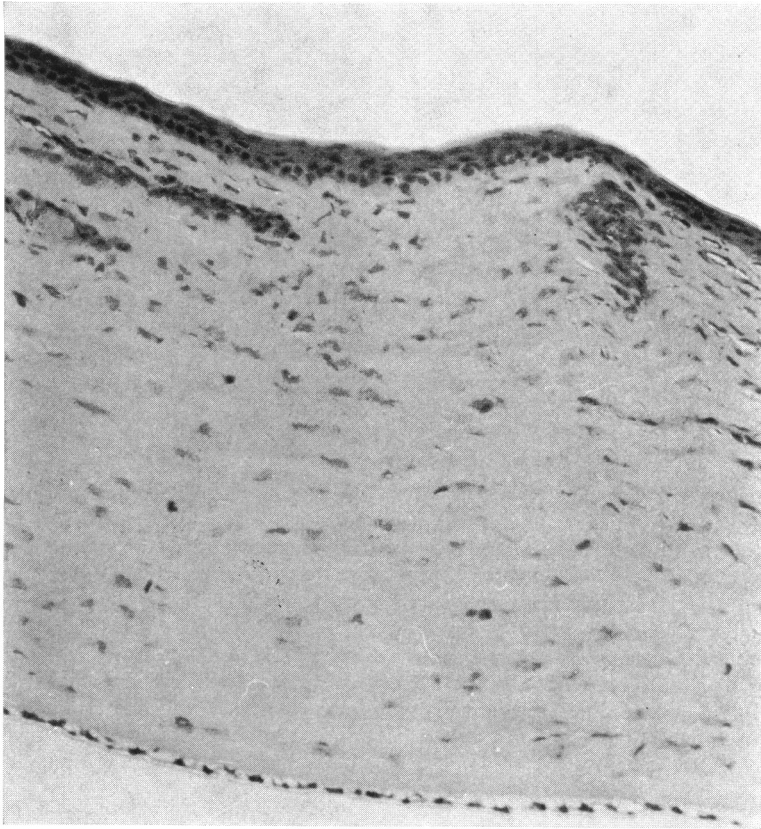
The following technique of argon laser treatment of corneal new vessels is recommended.

1. Suppress the corneal lesion which is stimulating the neovascularization with appropriate treatment, thus reducing the stimulus for revascularization to a minimum.
2. Perform intravenous fluorescein angiography at the time of laser therapy in order to determine which of the corneal vessels are arteries and which are veins and to visualize easily the smaller vessels. Furthermore, with fluorescein in the vessels at the time of laser therapy the energy absorption by the vessels is increased (Kohner, personal communication).
3. Set the argon laser at 100 mW, 50 μ m, 0.2 s and treat the corneal arteries about 3 mm in from the limbus, and then 'upstream' at the limbus. Having isolated a column of blood in this manner, treat between these two points on all the arteries until the arteries are obviously occluded and the blood flow in the veins therefore stagnant. The laser power can be increased to 150 mW, but it should not be necessary to use a greater power.
4. The retrograde flow in the veins (Figs 2-5) is at first very sluggish, taking about a day to become fully established. Even then, the calibre of the venous loop vessels is always less than before the arteries were occluded. However, this retrograde flow makes it necessary to treat all vessels rather than just the arteries. The veins are first treated at the limbus, then 'upstream' 3 mm in from the limbus, and then between the two points just mentioned. They need far fewer laser shots than the arteries. They are treated immediately after the arteries, when the

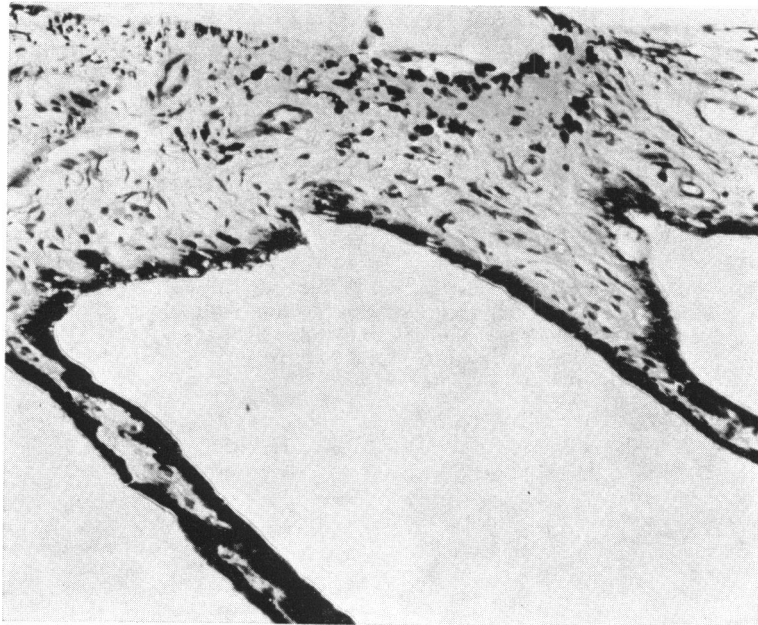


(11a)

FIG. 11 *Rabbit 2.* (a) Section showing occluded blood vessel in superficial stroma of cornea associated with a little reactive scar tissue formation. Underlying iris shows small shallow excavation lined by pigment-filled macrophages: iris otherwise intact. Haematoxylin and eosin. $\times 92$. (b) and (c) Higher magnifications of occluded corneal vessel and iris lesion seen in (a). Haematoxylin and eosin. $\times 180$



(Iib)



(Iic)

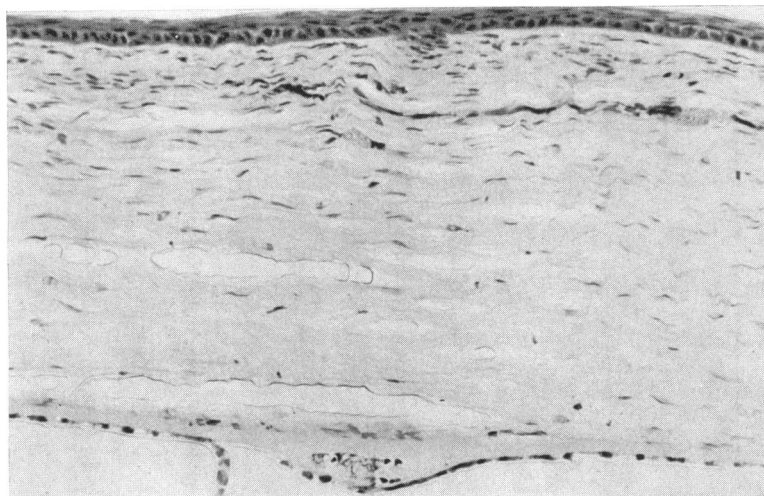


FIG. 12 Rabbit 10. Several treated vessels in superficial corneal stroma associated with mild scarring; small focus of debris between Descemet's membrane and endothelium probably related to earlier insertion of silk suture to induce vascularization. Haematoxylin and eosin. $\times 195$

blood flow in the veins will be stagnant or very sluggish.

5. If retreatment of the vessels is necessary some days later it should be in a similar manner to the first treatment session, but fewer laser shots should be needed to occlude all corneal vessels at the second and any subsequent treatment sessions.

Summary

The argon laser set at $50\ \mu\text{m}$, 100–150 mW, 0.2 s occluded corneal blood vessels in pigmented Dutch rabbits provided the corneal lesion responsible for inducing vascularization was inactive. After arterial treatment with the argon laser retrograde flow in untreated veins was demonstrated by

fluorescein angiography. Therefore all corneal new vessels should be treated, not just arteries. Minimal iris damage complicated the laser therapy, but this was not thought necessarily to contraindicate the use of the argon laser to treat corneal blood vessels in man. The iris damage was associated with outpouring of aqueous from the ciliary processes, and it took up to a week for the blood-aqueous barrier to return to its normal state.

We thank the Medical Research Council for donating the argon laser used in the experiment to Dr E. M. Kohner of the Hammersmith Hospital, London, England. We also thank Mr N. S. C. Rice and Dr Kohner for their advice, and the Department of Audio-Visual Communications, Institute of Ophthalmology, London, for preparing the figures.

References

- CAMPBELL, C. J., RITTLER, M. C., SWOPE, C. H., and WALLACE, R. A. (1969) *Amer. J. Ophthalm.*, **67**, 671
 CHERRY, P. M. H., FAULKNER, J. D., SHAVER, R. P., WISE, J. B., and WITTER, S. L. (1973) *Ann. Ophthalm.*, **5**, 911
 GEERAETS, W. J., WILLIAM, R. C., CHAN, G., HAM, W. T. JR., GUERRY, D. III, and SCHMIDT, F. H. (1962) *Invest. Ophthalm.*, **1**, 340
 JONES, B. R. (1973) 'Summing Up Present Knowledge and Problems of Corneal Graft Failure', Ciba Foundation Symposium 15 (NS), p. 352. Elsevier, Excerpta Medica, North-Holland, Amsterdam
 MEYER-SCHWICKERATH, G. (1960) 'Light Coagulation', p. 16. Mosby, St Louis
 UNGER, W. G., PERKINS, E. S., and BASS, M. S. (1974) *Exp. Eye Res.*, **19**, 367