

Annular choroidal sclerosis

A. CHOPDAR

Fundus Clinic, Moorfields Eye Hospital, High Holborn, London

Annular choroidal sclerosis is a rare kind of fundus disease. It was first described by Knapp (1907) but later Schocket and Ballin (1970) added two more cases to the literature.

Material and methods

CASE REPORT

A 29-year-old White man was seen in the fundus clinic of Moorfields Eye Hospital in September 1974. He had a history of gradual deterioration of vision in both eyes for the past five months. He had been seen elsewhere earlier that year when visual deterioration first became noticeable in the right eye, with a diagnosis of central serous retinopathy, and had received a course of systemic corticosteroids. One month later symptoms began in the left eye, while still on systemic corticosteroid treatment, and he was referred to the fundus clinic. He gave no history of any previous ocular or systemic illnesses. There was no family history of similar disease or of consanguinity.

OCULAR EXAMINATION

The visual acuity was 6/18 in each eye. External examination—including slit-lamp biomicroscopy, pupillary responses, and extraocular movements—was normal. The fundi showed bilateral symmetrical annular bands of depigmentation beginning at the upper part of the optic disc, passing along the course of the upper temporal vessels, and circling round an oedematous macula. This circle of depigmentation was somewhat incomplete inferiorly. There were a few pigment clumps on the surface of the retina along the band of depigmentation, but no evidence of narrowing of the retinal blood vessels or optic atrophy.

The fluorescein angiogram showed early background choroidal fluorescence through the defective retinal pigment epithelium, surrounding a hypofluorescent macula, in a horse-shoe manner. The lower incomplete part showed spotty windowing. The late frames of the angiogram showed leakage into the macula and scleral staining corresponding to the depigmented band (Fig. 1).

Eighteen months after the onset of symptoms his visual acuity and visual fields had remained unchanged. The fluorescein angiogram showed there was very little

leakage into the macula, and no further advance of the choroidal sclerosis.

RETINAL FUNCTION TESTS

Perimetry revealed an incomplete ring scotoma between the 10° and 20° isopters around the point of fixation in each eye which matched very closely to the band of depigmentation seen clinically (Fig. 2). The colour vision was normal. The dark adaptation curve showed a rise in the final threshold by 1½ log units. The electro-oculogram was flat, while the electroretinogram was reported to be normal.

LABORATORY EXAMINATIONS

The haematological examination showed haemoglobin 15.4 g/100 ml, total white cell count 9000 mm³, neutrophils 57 per cent, lymphocytes 34 per cent, eosinophils 4 per cent, monocytes 5 per cent, packed cell volume 44 per cent, mean cell haemoglobin concentration 34 per cent, and erythrocyte sedimentation rate 4 mm in 1 hour. Serological tests for syphilis and Reiter's syndrome were negative.

PEDIGREE

The seven-year-old daughter of this patient had a visual acuity of 6/6 in each eye. Her fundi showed gross retinal pigment epithelial disturbance and a faint arc of depigmentation extending both upwards and downwards adjacent to the temporal border of the optic disc. Fluorescein angiography revealed patchy choroidal filling and windowing owing to defective retinal pigment epithelium. The depigmented arc at the temporal border of the optic disc gradually took on a somewhat oval-ring shape, and showed some loss of choriocapillaris. Both maculae were normal (Fig. 3). No other member of the family showed any such clinical signs (Fig. 4).

Discussion

The case described here has many findings similar to those reported by the previous authors as circinate choroidal sclerosis (Knapp, 1907; Schocket and Ballin, 1970). Zimmerman and Fitzgerald (1975) described a case of 'peculiar degenerative choroidal sclerosis' affecting both

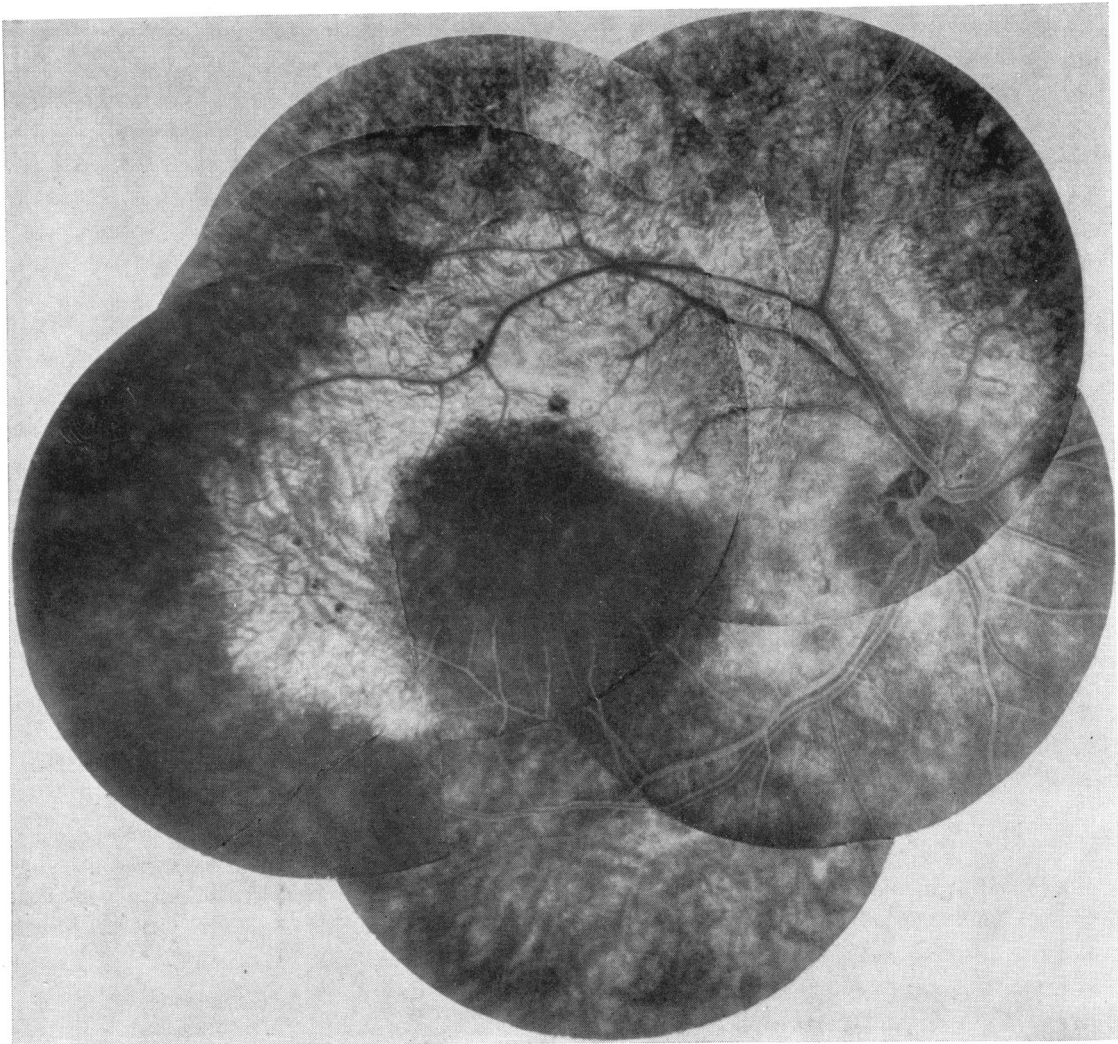


FIG. 1 (a) Composite fundus photograph of right eye, from various stages of fluorescein angiography, showing annular choroidal sclerosis

eyes in a 60-year-old man, with many features similar to circinate choroidal sclerosis. The term 'annular' has been chosen to avoid confusion with the well-established circinate retinopathy seen in various fundus disorders.

Annular choroidal sclerosis, although rare, is a definite entity. Careful analysis of all reported cases showed bilateral occurrence in both sexes at all ages. The visual acuity may also be reduced depending upon the amount of damage to the macula. From this fluorescein study it was apparent that the initial lesion lay in the choriocapillaris, leading to degeneration and atrophy of retinal pigment epithelium which progressed in an annular

pattern from the optic disc round the macula. Macular oedema during the active phase of the disease was probably due to damaged choriocapillaris and altered metabolism of the retinal pigment epithelium. Later the activity subsided and the macular oedema resolved, leaving an annular band of choroidal sclerosis around the macula. The flat electro-oculogram suggested widespread damage of the outer layer of the retina, probably secondary to the impaired choroidal circulation.

In this family the genetic evidence is inadequate, although the seven-year-old daughter did show some of the signs of the disease both clinically and angiographically. It has not been possible to com-

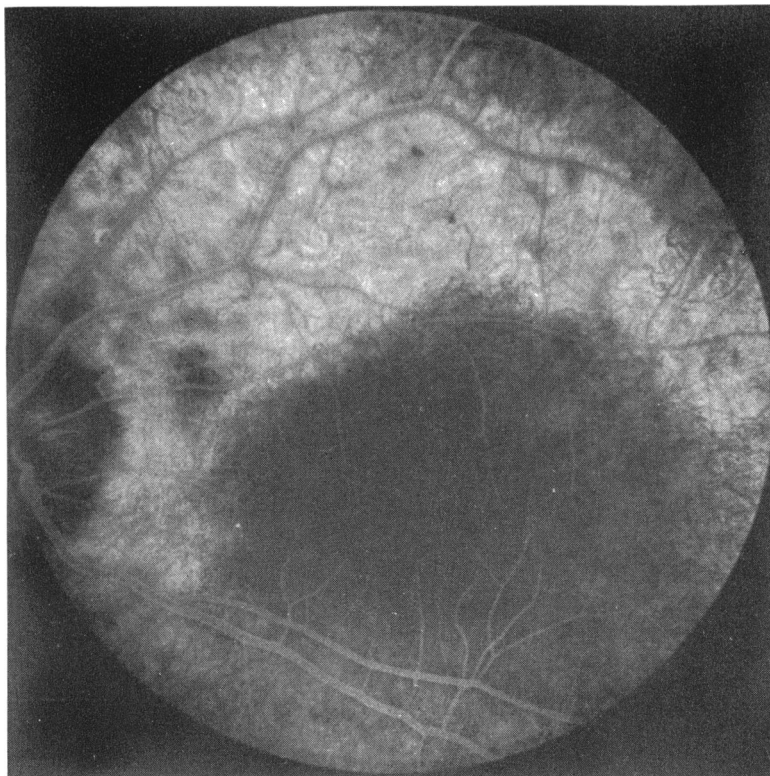


FIG. 1 (b) *Fluorescein angiographic appearance of left fundus, 10 min after injection of dye showing an annular pattern of choroidal sclerosis, similar to that of right eye*

plete all the desired investigations on this very young girl because of lack of co-operation, and it will need many years of follow-up to see if the full form of the disease will develop.

Defective electrodiagnostic results and abnormal dark adaptation would arouse suspicion of tapeto-retinal degeneration such as retinitis pigmentosa and choroideremia. Central choroidal sclerosis and

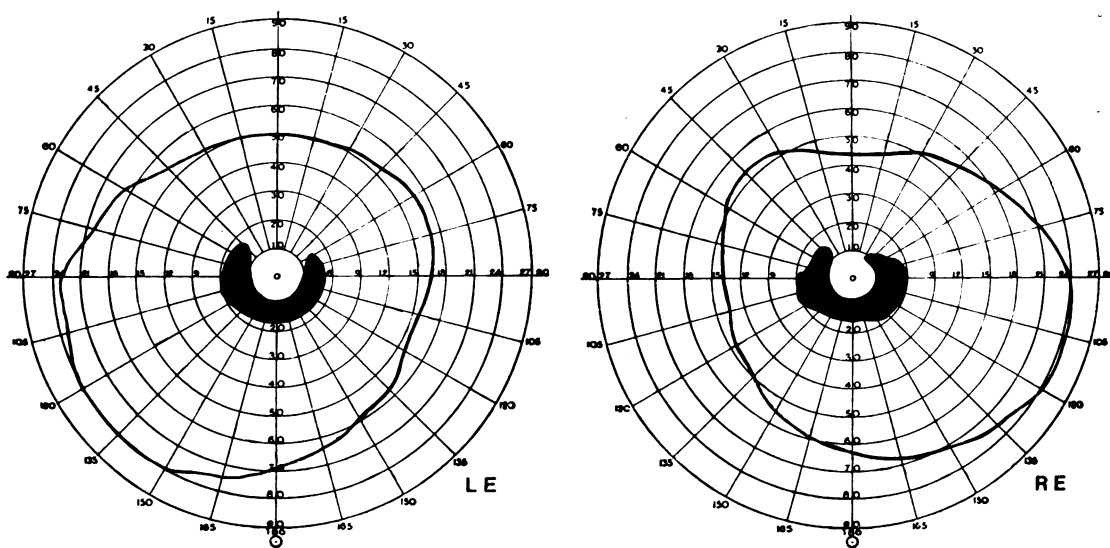


FIG. 2 *Visual fields showing ring scotomas matching choroidal sclerosis seen in Fig. 1*

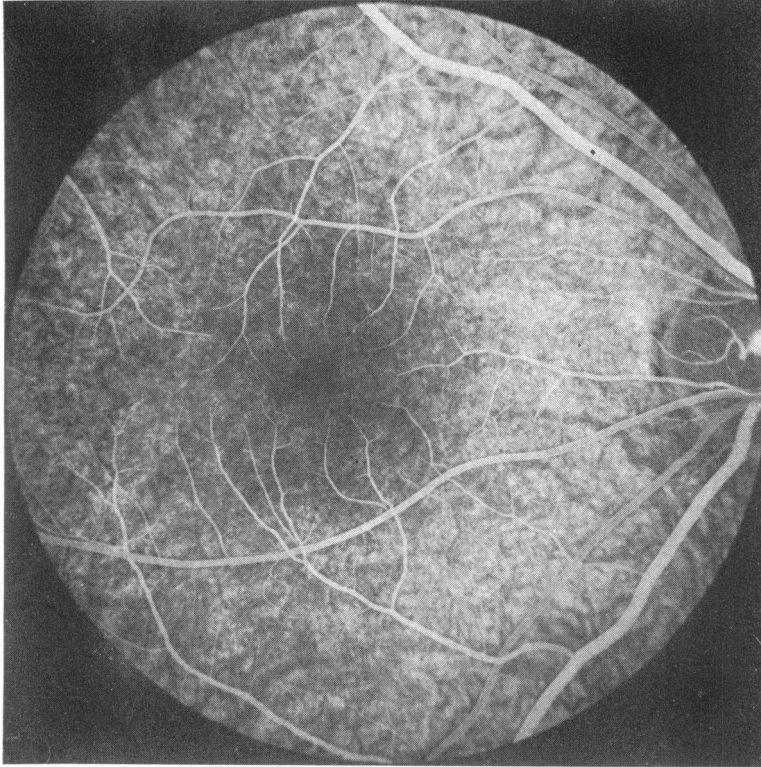


FIG. 3 (a) *Fluorescein angiographic appearance of right fundus of daughter, during venous phase, showing patchy background choroidal fluorescence due to defective retinal pigment epithelium in a somewhat ring-shaped manner, especially temporal to optic disc*

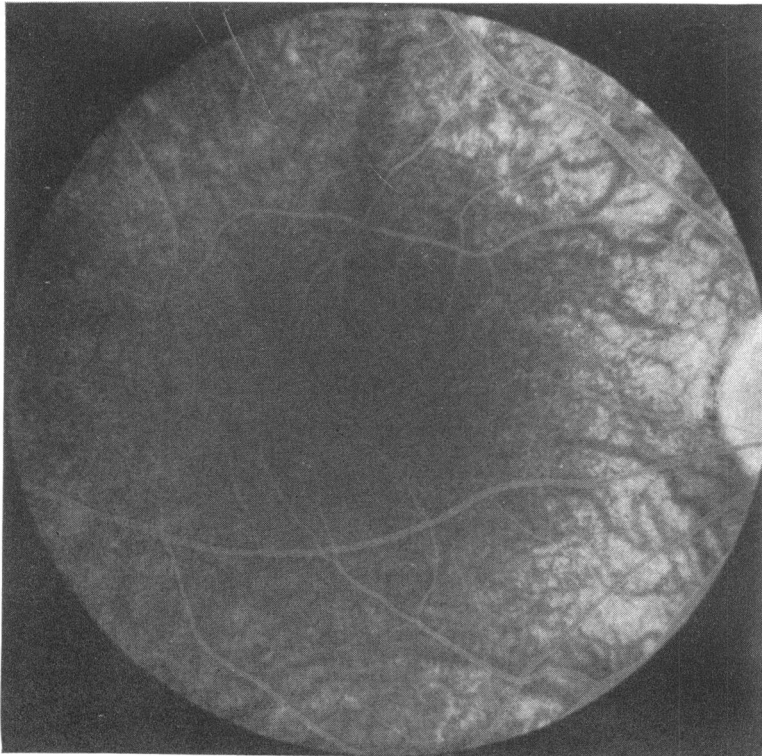


FIG. 3 (b) *Same eye as (a) 10 min after injection of dye, showing more definite annular pattern*

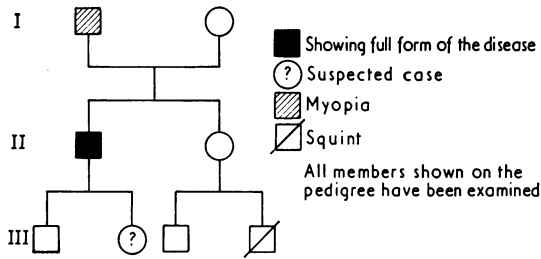


FIG. 4 *The pedigree*

geographical choroiditis may at times be confused with annular choroidal sclerosis because of macular oedema, but in all these cases the visual acuity is

severely affected and atrophic changes start at the macula. Rarely myopia and albinism might be suspected because of the sparseness of the retinal pigment epithelium.

Summary

This is a case description of a rare fundus condition known as annular choroidal sclerosis. No more than four previous cases have so far been reported. In this article consideration is given to the pathogenesis of the disease and a possible familial link.

I thank Professor David W. Hill for his helpful criticism and permission to report this case under his care. I also thank Mrs Ann Marie Turk for the illustrations and Mrs Joyce Preen for her secretarial help.

References

KNAPP, P. (1907) *Klin. Mbl. Augenheilk.*, **45**, 171
 SCHOCKET, S. S., and BALLIN, N. (1970) *Trans. Amer. Acad. Ophthal. Otolaryng.*, **74**, 527
 ZIMMERMAN, T. J., and FITZGERALD, C. R. (1975) *Ann. Ophthal.*, **7**, 480