

Subconjunctival and episcleral lipid deposits

F. T. FRAUNFELDER,* A. GARNER, AND T. C. BARRAS

From the External Diseases Unit, Moorfields Eye Hospital, and the Department of Pathology, Institute of Ophthalmology, University of London

Biomicroscopical examination of the peripheral bulbar conjunctiva and episcleral tissue, especially at the level of the palpebral fissure, commonly reveals globules of lipid. The globules vary in size from 30–80 μm in diameter, although in any one individual they tend to be fairly uniform, and were first described by Paliaga (1959) in Italy. A subsequent report from America (Fraunfelder and Hanna, 1975) indicated that the prevalence of the lipid deposits increases with age, over half the population aged 50 years or more in Arkansas being affected. The deposits assume two basic patterns: most often multiple globules lie adjacent to blood vessels but sometimes they occur in small isolated foci. Perivascular distribution is six times more

common on the nasal side and twice as common on the temporal side when compared with isolated patches (Fraunfelder and Hanna, 1975).

The purpose of this report is to compare the prevalence of this entity in Great Britain with that observed in the United States of America, to consider its relationship to arcus senilis of the cornea, and to describe the histopathological features.

Patients and methods

From January to July 1975 over 1000 randomly selected outpatients at Moorfields Eye Hospital drawn from various parts of Britain were examined biomicroscopically for the presence of conjunctival or episcleral lipids. Some were also examined for corneal arcus senilis. Patients who had not spent at least three-quarters of their lives in the United Kingdom were excluded from the study. Photographs were taken using a Zeiss photo slit lamp and a macro camera as described by Brown (1970). Twenty-eight eye bank eyes were

*Visiting Professor, Institute of Ophthalmology, July 1974 to July 1975. Present address: Department of Ophthalmology, University of Arkansas Medical Center, 4301 West Markham, Little Rock, Arkansas 72201.

Address for reprints: Dr A. Garner, Institute of Ophthalmology, Judd Street, London WC1H 9QS

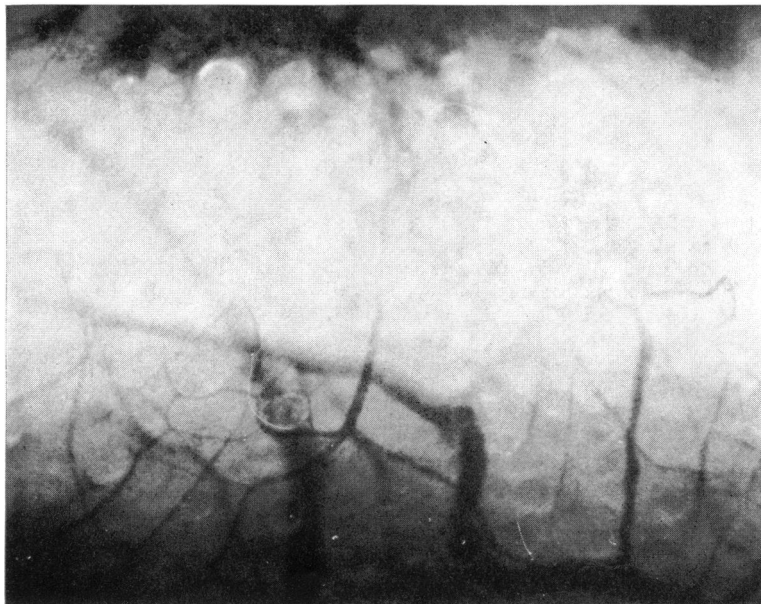


FIG. 1 *Slit-lamp photograph of multiple lipid globules in deep conjunctiva and episclera. $\times 11$*

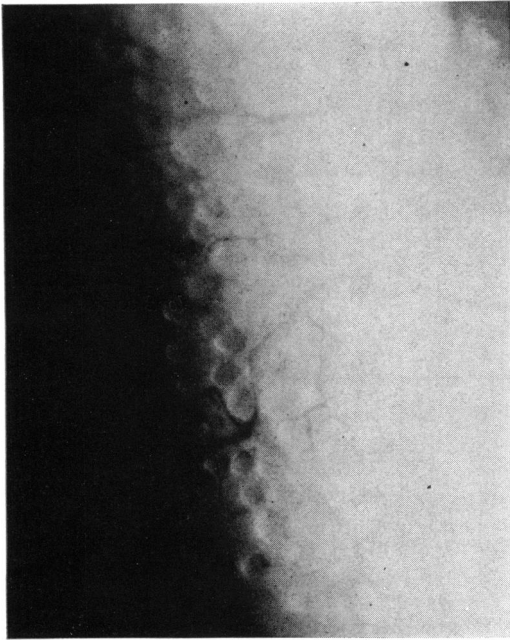


FIG. 2 Widespread distribution of lipid globules in bulbar conjunctiva of man who had sustained blast injury to both eyes. $\times 14$

examined histologically, the tissue being fixed in formol saline and variously stained with haematoxylin and eosin, oil red O, osmium tetroxide and α -naphthylamine (OTAN), and by Okamoto's method for cholesterol. Carbowax embedding (a water-soluble wax designed to impregnate tissues without requiring the prior removal of lipid) was also performed on selected specimens.

Results

Clear round globules were seen at varying depths within the conjunctiva but predominated in the episcleral tissue (Fig. 1). The deposits were asymp-

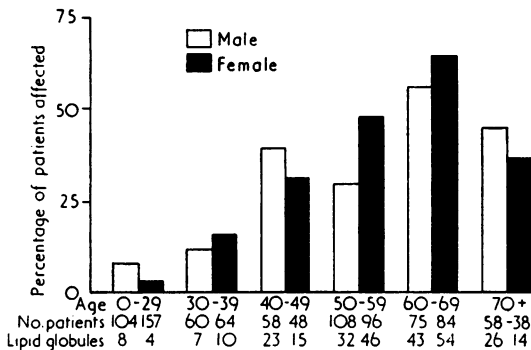


FIG. 3 Prevalence of subconjunctival lipid globules in Great Britain at different ages in men and women

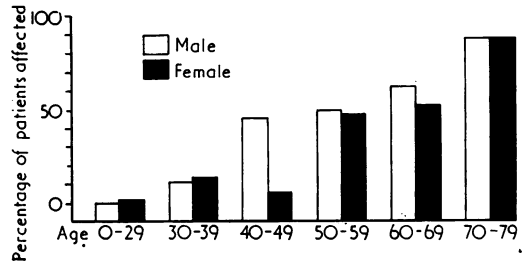


FIG. 4 Prevalence of corneal arcus in men and women at different ages

tomatic and, although differing in size from patient to patient, were of uniform diameter in a given person. In one patient, who had sustained a blast injury during the second world war, the whole bulbar conjunctiva of both eyes was filled with lipid globules (Fig. 2). The youngest person to show the presence of globules was 21 years old. The prevalence and severity of the lesion increased linearly up to the age of 70 years: beyond this age the prevalence declined (Fig. 3). The proportions of men and women with conjunctival lipid deposits

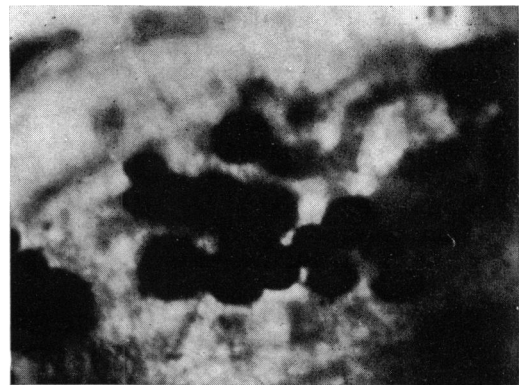


FIG. 5 Stained subconjunctival globules in intact emucleated globe showed pronounced uptake of oil red O (from colour original). $\times 18$

were not significantly different. The prevalence of corneal arcus also increased with age in both sexes (Fig. 4) but without any reduction beyond the age of 70 years, so that the correlation in individual cases between the presence of arcus and conjunctival lipid was not statistically significant.

Examination of the subconjunctival globules with a dissecting microscope showed a predominantly perivascular distribution, and it was noted that heat generated by the illuminating source caused them to fuse and lose their discrete spherical shape. Treatment of the globules at this stage with oil red O produced an intense uptake of the dye

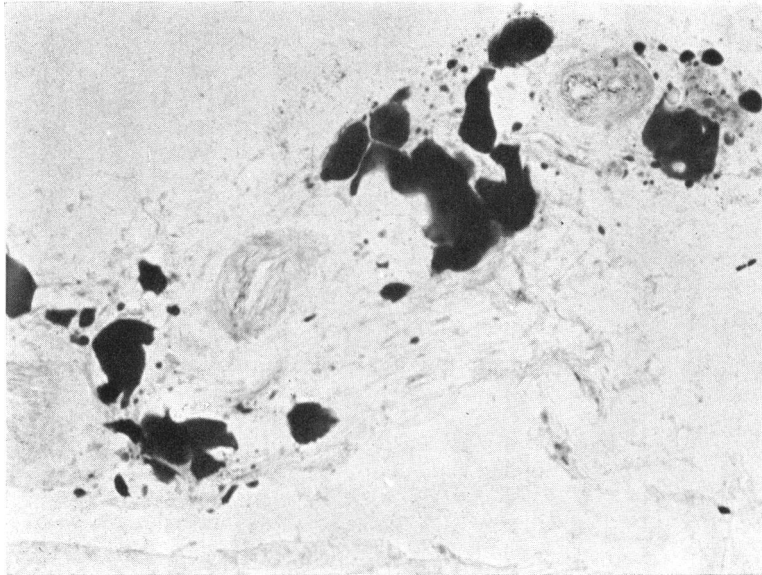


FIG. 6 *Frozen section showing extracellular lipid deposits adjacent to conjunctival blood vessels. Oil red O. $\times 90$*

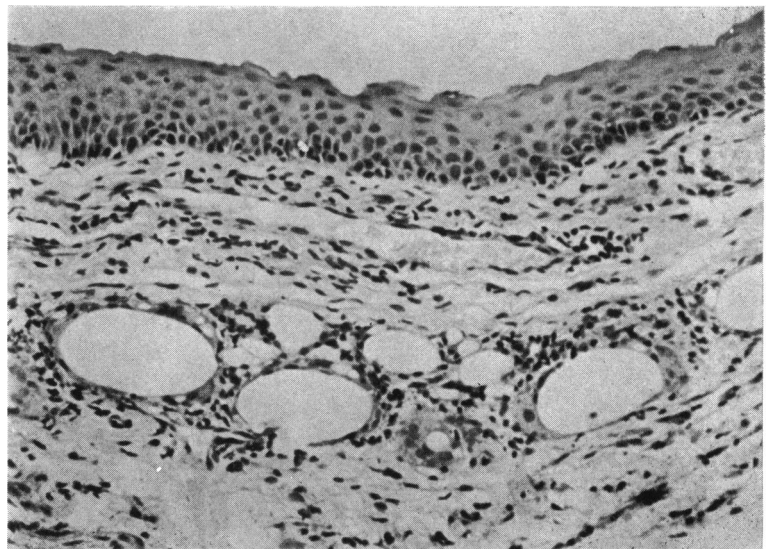
by the deposits (Fig. 5). Although frozen and carbowax-embedded sections were prepared the lipid globules were seldom retained in the mounted preparation, the rare exceptions showing amorphous fat devoid of any limiting membrane and apparently located within extracellular spaces in the loose connective-tissue of the subconjunctiva and episclera (Fig. 6). Staining for cholesterol by Okamoto's method on the gross specimen resulted in a blue-black reaction product. Finely particulate lipid which stained with oil red O and gave a brown-black colour in the OTAN procedure was demonstrable in the sclera in all cases.

A biopsy specimen, which had been taken some years earlier from the patient demonstrated in Fig. 2, examined in routine paraffin-embedded sections showed fat spaces surrounded by a granulomatous inflammatory reaction (Fig. 7).

Discussion

Conjunctival and episcleral lipid globules are easily missed unless specifically looked for, ideally using either direct or indirect retroillumination. The aggregated globules resemble frog-spawn and occur most often between the loops of large, tortuous blood vessels.

FIG. 7 *Section showing lipid spaces in conjunctival stroma surrounded by giant-cell granulomatous reaction. Haematoxylin and eosin. $\times 185$*



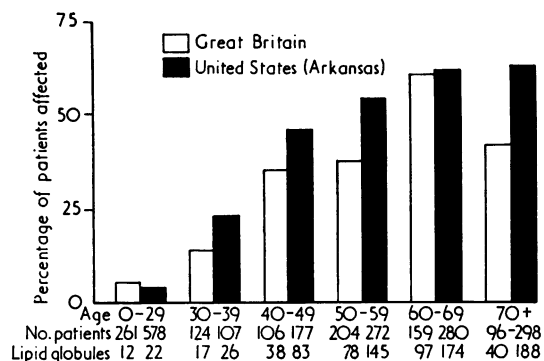


FIG. 8 Comparative prevalence of subconjunctival lipid globules in Great Britain and United States of America at different ages. (US data from Fraunfelder and Hanna, 1975)

The prevalence of the condition shows a clear relationship with age. Beyond the age of 70 years, however, the American data show that the rise in prevalence is halted (Fraunfelder and Hanna, 1975), while the present study suggests that it might even be reversed. The American study also showed a preponderance of women with subconjunctival lipid at all ages, but there was no convincing evidence of such a predilection in British subjects. However, the overall prevalence seems to be slightly higher in Arkansas (Fig. 8).

With increasing age lipid accumulates between the collagen fibres of the sclera, particularly towards the uveal surface, and this process may share a common pathogenesis with corneal arcus formation, with which it is commonly associated (Yanoff and Fine, 1975). Consequently, if the subconjunctival globules originate from the same source as those in the sclera—and our finding of scleral lipid deposition in all eyes with conjunctival globules examined histologically lends some support to this hypothesis—a good correlation between the conjunctival lesion and corneal arcus might also have been expected. This, however, was not the case.

The reason for this disparity is not immediately obvious but may be linked with the observation that the lipid deposited in the cornea and sclera is in a finely particulate form, being largely bound to low density lipoprotein (Walton, 1973), whereas

that in the loose stroma of the conjunctiva occurs as much larger globules which probably represent unbound fat. There is good evidence that the lipid of corneal arcus senilis is derived from the circulating plasma (Cogan and Kuwabara, 1959; Walton, 1973; Walton and Dunkerley, 1974), and the frequent perivascular and extracellular location of the deposits as well as their cholesterol content are conducive to similar reasoning in respect of the conjunctival lesion. Whether or not the loose structure of the subconjunctival stroma facilitates the fusion of smaller lipid particles, which have seeped through a vascular endothelium subject to an age-related increase in permeability, is not known.

Other possibilities for the origin of the conjunctival globules, referred to in an earlier paper (Fraunfelder and Hanna, 1975), include forward migration of orbital fat, degenerative changes in the tissues, and trauma to the conjunctival blood vessels caused by eye movements and blinking. The essentially extracellular location of the lipid droplets, however, lends little support to any but the last of these suggestions. The extent to which leakage of circulating fat might represent a fundamental degenerative change in the conjunctival vessels, after the manner postulated for arteriosclerosis in other sites, or be attributable to repeated episodes of minor trauma is not known, although the finding of massive lipid deposition in the conjunctiva of a man subjected to blast injury suggests that the latter hypothesis is a real possibility.

Fortunately, in view of their high prevalence, conjunctival and anterior episcleral lipid globules almost never give rise to symptoms—the extremely rare exception appearing to be a granulomatous reaction which probably reflects an alteration in the nature of the fat.

Summary

Biomicroscopical examination of the bulbar conjunctiva and anterior episclera of 1000 randomly selected outpatients showed the presence of multiple discrete lipid globules in 30 per cent. The lipid deposits were asymptomatic. Their prevalence was age-related, while their distribution and composition were consistent with origin from the conjunctival blood vessels.

References

- BROWN, N. A. (1970) *Brit. J. Ophthalm.*, **54**, 697
 COGAN, D. G., and KUWABARA, T. (1959) *Arch. Ophthalm.*, **73**, 553
 FRAUNFELDER, F. T., and HANNA, C. (1975) *Amer. J. Ophthalm.*, **79**, 262
 PALLAGA, G. P. (1959) *Boll. Oculist.*, **38**, 867
 WALTON, K. W. (1973) *J. Path.*, **111**, 263
 ———, and DUNKERLEY, D. J. (1974) *Ibid.*, **114**, 217
 YANOFF, M., and FINE, B. S. (1975) 'Ocular Pathology: a text and atlas', p. 281. Harper & Row, Maryland