

# PRÆCORDIAL PULSATIONS IN RELATION TO CARDIAC MOVEMENT AND SOUNDS

BY

PATRICK MOUNSEY

*From the Cardiac Department of the London Hospital*

Received November 29, 1958

In a previous paper (Mounsey, 1957), a method of recording præcordial pulsations was described. The purpose of this paper is to show how the simultaneous recording of præcordial pulsations and heart sounds can help in diagnosis, especially by enabling a clearer picture to be formed of the cardiac movements as observed at thoracotomy.

The original name proposed for the method was præcordial ballistocardiography, but in view of the different use of the word in conventional ballistocardiography, it seemed preferable to alter the name to the præcordial acceleration cardiogram, which describes both the nature and site of the pulsations.

Although it was hoped at first that the acceleration cardiogram might help to distinguish between right and left ventricular hypertrophy, ventricular systolic pulsations have so far proved difficult to analyse in the record. This is perhaps in part due to the fact that much of the cardiac work during systole is expended in pressure rather than movement, and in part due to the nature of the præcordial movement, which is heaving and lifting in the presence of hypertrophy and hence difficult to investigate in a record of acceleration. Diastolic præcordial pulsations, however, have lent themselves well to analysis by this method and in this paper the relationship will be discussed between these pulsations, the diastolic heart sounds, and the underlying abnormal cardiac movements, when these were witnessed at thoracotomy.

## THE INVESTIGATION DESCRIBED

The accelerometer used for the recording was that described by Elliott *et al.* (1954). The original method of attaching the accelerometer to the chest wall by a rubber strap was retained (Mounsey, 1957). The instrument itself, however, was mounted on a light aluminium arm, moving on a relatively frictionless pivot, thereby eliminating all movement of the accelerometer, other than that in its long axis (Harrison, 1957). In this way a more faithful record of movement in an axis at right angles to the body surface was obtained and minor inaccuracies introduced by rocking or side to side movement of the accelerometer were avoided (Fig. 1).

The two areas selected for recording were the apex beat and the lower sternum, about the level of the fourth intercostal space. The subject lay resting on a steady couch, which was covered with a firm mattress, with the upper part of the body raised to an angle of 35°. Records were made on a Sanborn Twin-Viso recorder, the output of the accelerometer being fed into the electrocardiograph amplifier. Standardization of the acceleration cardiogram was varied as required in individual records to give a convenient size, although most records were made with roughly the same amplification. Where the chest was thin, however, or the pulsations very large, great reduction in amplification was sometimes necessary. Any attempt at absolute standardization of the record was impracticable.

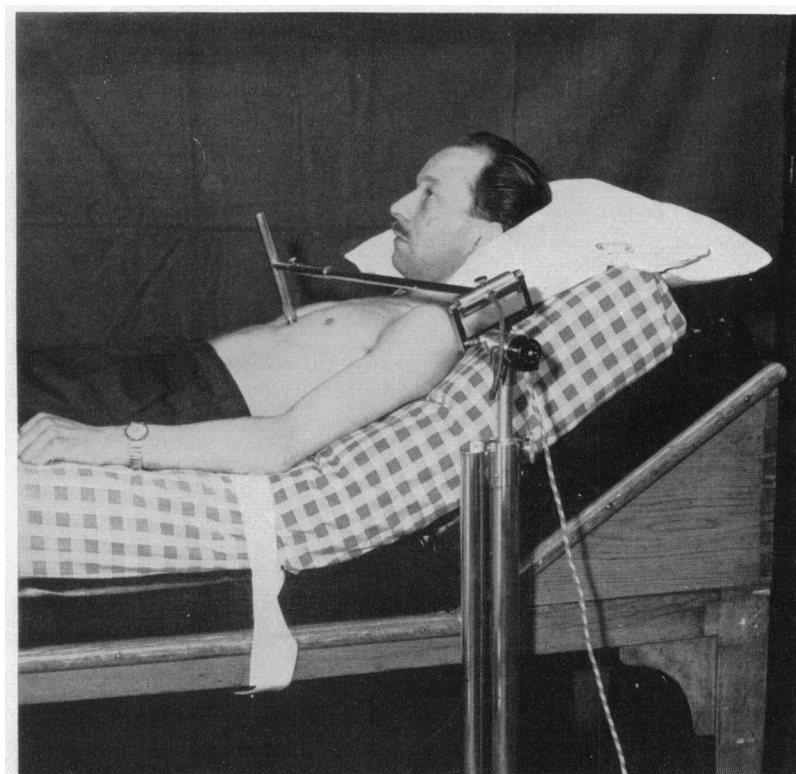


FIG. 1.\*—Præcordial acceleration cardiograph. The rubber band, securing it to the chest wall, is not shown.

A simultaneous *phonocardiogram* was recorded with the acceleration cardiogram from identical areas, by placing the accelerometer pick-up on top of the phonocardiograph microphone and strapping it lightly, but firmly, to the chest with an encircling rubber band. The placing of the 4 cm. diameter phonocardiograph microphone between the chest wall and the accelerometer pick-up did not alter the form of the acceleration record obtained, apart from diminishing slightly its voltage. A medium frequency filter was used to record the phonocardiogram. In addition, an electrocardiogram, usually lead II, was recorded simultaneously with the acceleration cardiogram.

Over 300 præcordial acceleration cardiograms have now been recorded. These include 57 records on normal subjects, 148 on patients with rheumatic heart disease, 41 with congenital heart disease, 24 with constrictive pericarditis, 15 with systemic hypertension, 9 with cardiomyopathy, and 12 with cardiac infarction.

In order to try to interpret the abnormal patterns of the pulsations recorded, the movements of the heart were carefully watched at thoracotomy in 80 of these patients, including 55 with mitral stenosis, 14 with congenital heart disease, and 10 with constrictive pericarditis.

#### THE NORMAL PRÆCORDIAL ACCELERATION CARDIOGRAM

The normal tracing has already been described under the title of the præcordial ballistocardiogram (Mounsey, 1957). In this paper only the diastolic portion of it will be considered.

\* Reproduced by kind permission of the Editors of the *Journal of the Society of Cardiological Technicians of Great Britain*.

Two typical examples of normal acceleration cardiograms are illustrated, one from a boy in his teens (Fig. 2), and the other from a man of middle age (Fig. 3). In both records an *atrial beat* accompanying atrial systole is seen, although no clear atrial sound is recorded in the medium

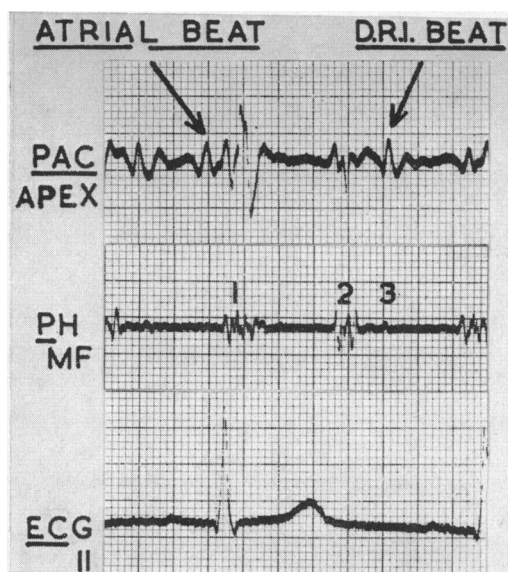


Fig. 2

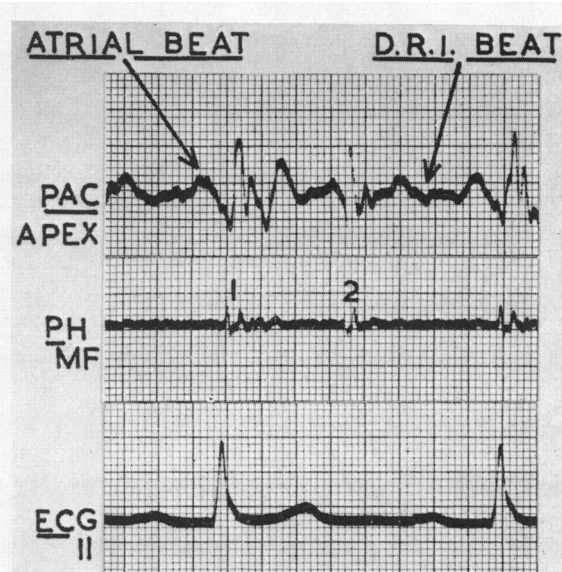


Fig. 3

FIG. 2 and 3.—Præcordial acceleration cardiograms (PAC) at the apex in two healthy subjects: Fig. 2, aged 12 years; Fig. 3, aged 50 years. An atrial beat and diastolic rapid inflow (D.R.I.) beat are recorded, which are larger in the younger subject. The third heart sound (3) in Fig. 2 coincides with the D.R.I. beat.

PH MF=phonocardiogram medium frequency. 1 and 2=first and second heart sounds. ECG II=electrocardiographic lead II.

frequency phonocardiogram. In both subjects the atrial beat is relatively small compared with the vibrations in the acceleration cardiogram, which coincide with the first heart sound. An atrial beat was an invariable finding in healthy subjects in this series, although sometimes it was very small and was seldom palpable.

A *diastolic rapid inflow beat*, accompanying the phase of rapid ventricular filling, is also seen in the acceleration cardiogram in both subjects. It is larger and more obvious in the younger subject (Fig. 2) and very small in the older (Fig. 3). Only the younger subject had a third heart sound, for this is the audible component of the diastolic rapid inflow beat and is only heard when the beat is large. There was a general tendency in the group for the younger subjects to have a larger rapid inflow beat, which was sometimes palpable and accompanied by a third heart sound (Evans, 1942), whereas the older subjects had a small and sometimes hardly recognizable rapid inflow beat and no third heart sound.

In disease, both the atrial beat and the diastolic rapid inflow beat may be greatly augmented.

#### ATRIAL SYSTOLE IN DISEASE

Anyone who has watched the heart of lone, severe, pulmonary stenosis at operation, cannot fail to have been struck in some patients by the violent agitation of the whole organ during atrial systole, which sometimes completely dwarfs the movement of the heart during ventricular systole. Simultaneously with the contraction of the greatly enlarged and hypertrophied right atrium, the right ventricle, which appears only partially to have filled passively during diastole, suddenly

distends further, rather like a toy rubber balloon, that has initially resisted inflation, but finally blows out in response to greater pressure.

The dynamics of giant atrial contraction are probably not fully understood, for pressure-volume rather than simple pressure measurements alone are needed in order to estimate the amount of active atrio-ventricular filling that takes place and how much atrial contractile force is diverted to regurgitation of blood into the venæ cavæ. It is likely that, in patients showing a giant *a* wave in the right atrium without tricuspid stenosis, abnormal stiffness or lack of full distensibility of the right ventricle at the time of atrial contraction is present: otherwise increased force of atrial contraction and increased atrial forward stroke-output could be accommodated in a freely distensible ventricle with little increase in the height of the *a* wave in right atrial pressure. In pulmonary stenosis abnormal ventricular stiffness is a sequence of right ventricular hypertrophy, although all patients with an equal degree of stenosis do not necessarily show a giant atrial beat. Other factors, like the age of the patient and the length of time during which the right ventricle has been subjected to obstruction, may determine this.

The præcordial pulsations recorded in the acceleration cardiogram reflect the violent agitation of giant atrial contraction. An example of a giant atrial beat in severe pulmonary stenosis is shown in Fig. 4. Here the small atrial sound in the phonocardiogram gives little indication of the strength

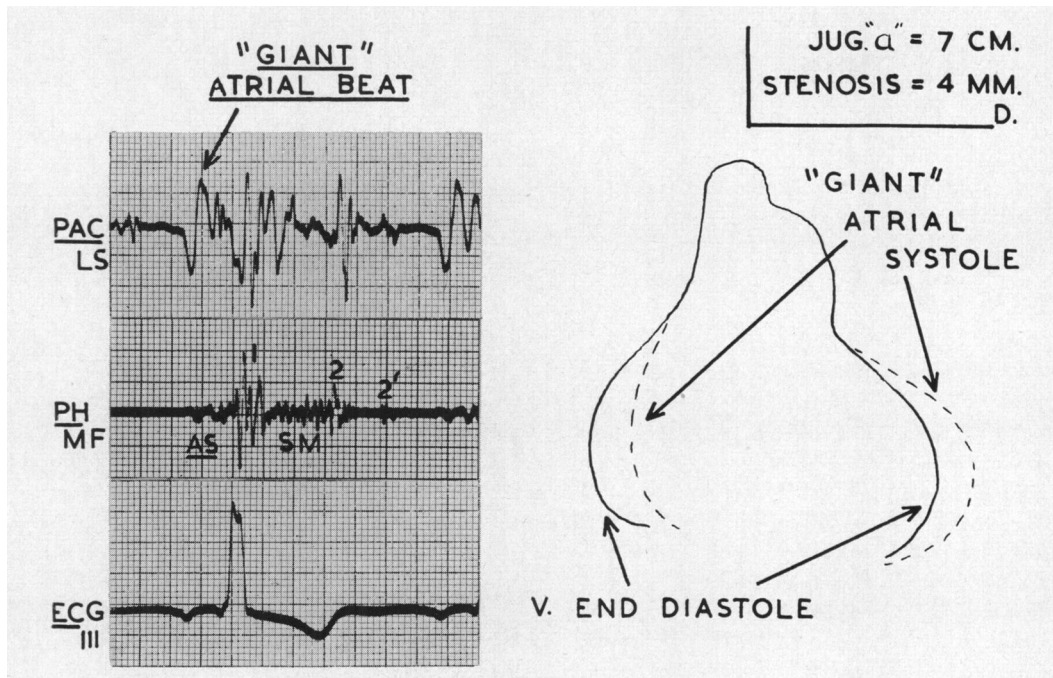


FIG. 4.—Giant atrial beat in the præcordial acceleration cardiogram (PAC) over the lower sternum (LS) in severe pulmonary stenosis, coinciding with an atrial sound (AS) in the phonocardiogram (PH). Line diagram of PA radiogram: extensive cardiac movement in atrial systole, as seen at thoracotomy, indicated by dotted lines. V. end diastole=ventricular end diastole, prior to atrial contraction. Jug. *a*=height above sternal angle of *a* wave in jugular venous pulse. D.=diameter. SM=systolic murmur. 2 and 2'=widely split second heart sound.

of atrial contraction, which was widely palpable over the whole præcordium and clearly recorded in the large vibrations in the acceleration cardiogram. The acceleration cardiogram of another patient with an equal degree of pulmonary stenosis is shown for comparison (Fig. 5). This patient

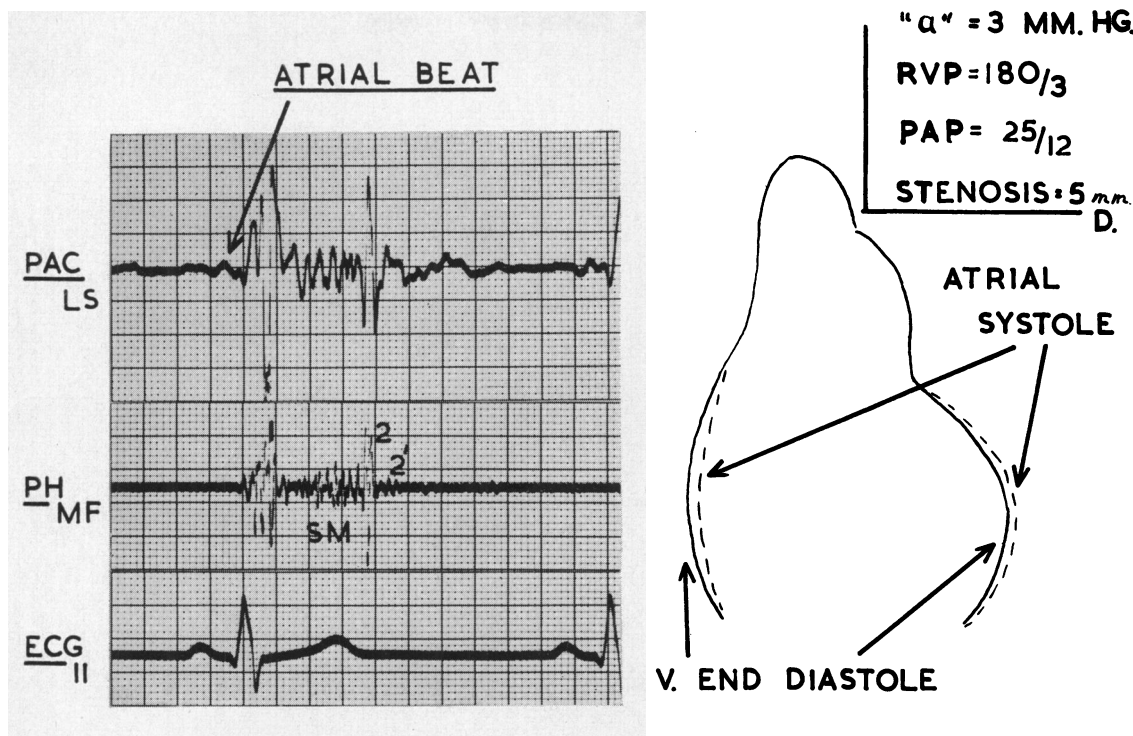


FIG. 5.—Absence of a giant atrial beat in severe pulmonary stenosis. Line diagram of PA radiogram, as in Fig. 4, with dotted lines indicating insignificant cardiac movement in atrial systole, as seen at thoracotomy.  $a$  = height of right atrial  $a$  wave above mid-heart: RVP and PAP = right ventricular and pulmonary arterial pressures (at cardiac catheterization).

did not have giant atrial contraction at operation and there is only a small atrial beat in the acceleration cardiogram, although he had tight pulmonary stenosis of 5 mm. diameter, with a gradient of pressure across the valve of 155 mm. Hg. The fact that he was a boy of 14 and considerably younger than the first patient, who was a woman of 37, may have in some way accounted for the apparent difference in myocardial reaction to a comparable degree of pulmonary stenosis.

A giant atrial beat may be seen in any condition in which great ventricular hypertrophy of either ventricle is present, such as in systemic and pulmonary hypertension, pulmonary, and aortic stenosis (Fig. 6), and mitral regurgitation (Fig. 13). The mechanism of the giant atrial beat in all these conditions is probably the same. Ventricular hypertrophy gives rise to myocardial stiffness, that permits only partial passive ventricular filling in response to right atrial filling pressure, and is overcome only by the extra impetus of atrial contraction. Patients with this sign often remain in relatively good health for a number of years and it does not carry the serious prognostic significance of a third heart sound and an associated large diastolic rapid inflow beat.

In general, a giant atrial beat produced by a left ventricular lesion is best recorded at the apex, and that by a right-sided lesion at the lower sternal area, the site of greatest impulse in each case being over the ventricle concerned. With left-sided lesions, however, this rule did not always hold good, since many of these patients had evidence of a giant right, as well as left, atrial beat as shown by the large  $a$  wave seen in the jugular venous pulse. The mechanism of a right-sided giant atrial beat, in response to left ventricular hypertrophy, is discussed below.

Another group of diseases in which a giant atrial beat is frequently seen is the cardiomyopathies (Brigden, 1957). As in simple ventricular hypertrophy, the pathogenesis of the beat is probably lack of normal distensibility and increased stiffness of the ventricular myocardium. Such patients

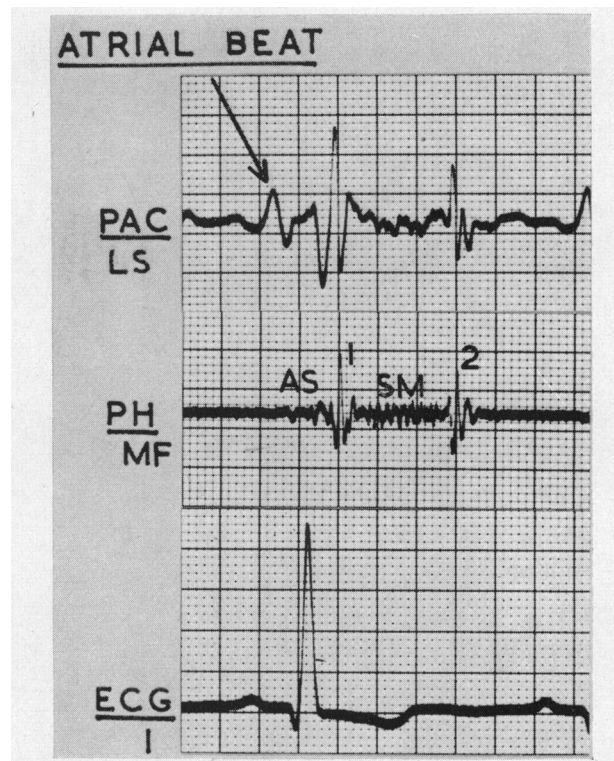


FIG. 6.—Large atrial beat in the præcordial acceleration cardiogram (PAC) in severe aortic stenosis, coinciding with atrial sound (AS). This record was made over the lower sternum (LS), but the beat was well recorded at the apex also.

with cardiomyopathy differ, however, from those with simple hypertrophy, in that heart failure is present with a raised end-diastolic pressure: hence the acceleration cardiogram shows a large diastolic rapid inflow beat as well as an increased atrial beat (Fig. 12).

One patient with cardiomyopathy is of special interest, since this eight-year-old girl was operated upon with a mistaken diagnosis of tricuspid and mitral stenosis, and at operation it was possible to study the abnormal cardiac movements. Tricuspid stenosis had been diagnosed on the finding of an atrial systolic murmur at the left sternal edge, right atrial enlargement in the radiogram and electrocardiogram, and the presence of a high end-diastolic pressure in the right atrium (7 mm. Hg) with a giant *a* wave (15 mm. Hg). No satisfactory withdrawal trace from the right ventricle to atrium had been obtained to confirm the diastolic pressure differential between the two chambers. Right ventricular systolic and pulmonary arterial pressures were within normal limits. At operation no stenosis of the tricuspid or mitral valve was found, but a giant right atrium was seen occupying over half the anterior surface of the heart; the contraction of this chamber appeared to the eye to be the dominant feature of the heart's movement. The appearance of delayed right ventricular filling, already described, was most striking in this patient, the ventricle appearing hardly to fill at all, until the atrium contracted. At autopsy, great left ventricular hypertrophy with no valvular cause was found, and on section the myocardium showed conspicuous hypertrophy of the muscle fibres with only slight increase in interstitial fibrous tissue. A diagnosis of cardiomyopathy was made in view of the idiopathic left ventricular hypertrophy which had given rise to heart failure. The right ventricular cavity was small and its walls not hypertrophied, which contrasted strikingly

with the left ventricle (Fig. 7). The right atrium was greatly enlarged and the left atrium was hypertrophied with only slight enlargement.

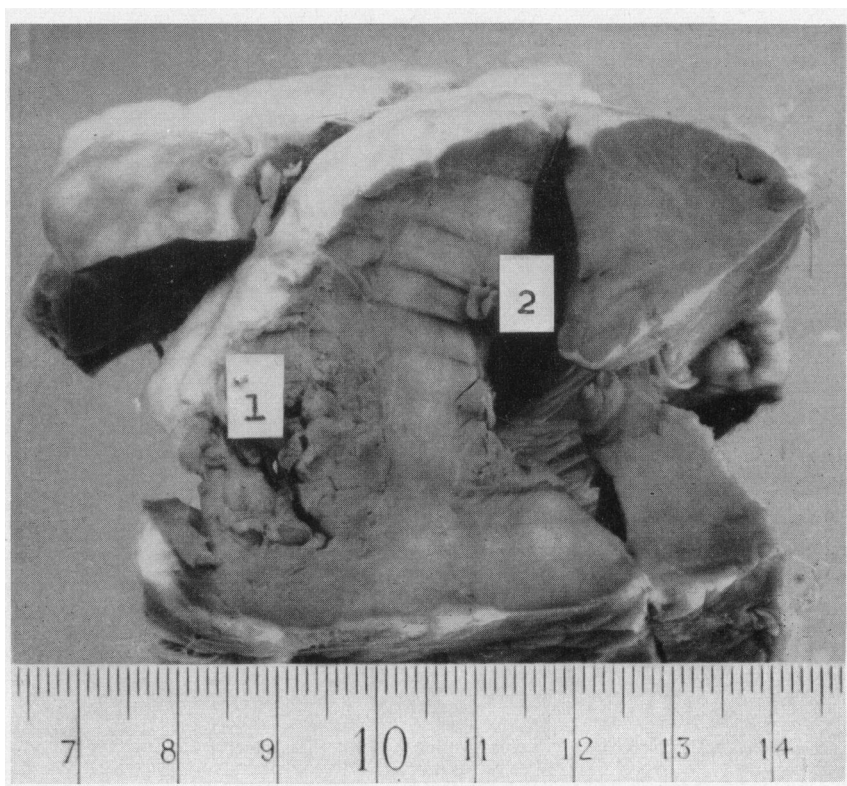


FIG. 7.—Transverse section of the heart of a patient with cardiomyopathy. The apex of both ventricles has been removed. 1=cavity of right ventricle. 2=cavity of left ventricle. Great left ventricular hypertrophy, involving interventricular septum.

This patient was an example of *Bernheim's syndrome* (1910), showing great left ventricular hypertrophy with the septum bulging into a small right ventricular cavity, great right atrial enlargement, normal pulmonary arterial pressure, and right heart failure. Observation of the heart's movements at operation suggested that increased myocardial stiffness in diastole, as well as decreased diastolic volume of the right ventricular cavity, was a factor in producing heart failure in this patient; for the right ventricle appeared capable of considerable additional filling under the high pressure provided by atrial contraction which raised the filling pressure from 7 to 15 mm. Hg. It is suggested, therefore, that the hypertrophied septum, besides decreasing the normal diastolic volume of the right ventricular cavity, acted also as a splint to the right ventricle. It thus prevented filling at normal diastolic pressures by increased stiffness consequent on hypertrophy, but still permitted this to take place in response to the greatly raised filling pressure, provided by giant atrial contraction.

The præcordial acceleration cardiogram clearly reflected the giant atrial beat, which was widely and easily palpable over the whole præcordium (Fig. 8). In the phonocardiogram an atrial systolic murmur was seen, best heard at the left sternal edge, and the electrocardiogram showed large right atrial P waves. In retrospect the presence of a giant atrial beat of such unusually large proportions, associated with a right atrial systolic murmur, should probably have weighed against the diagnosis of tricuspid stenosis. Although, in the presence of stenosis of either atrio-ventricular valve, there

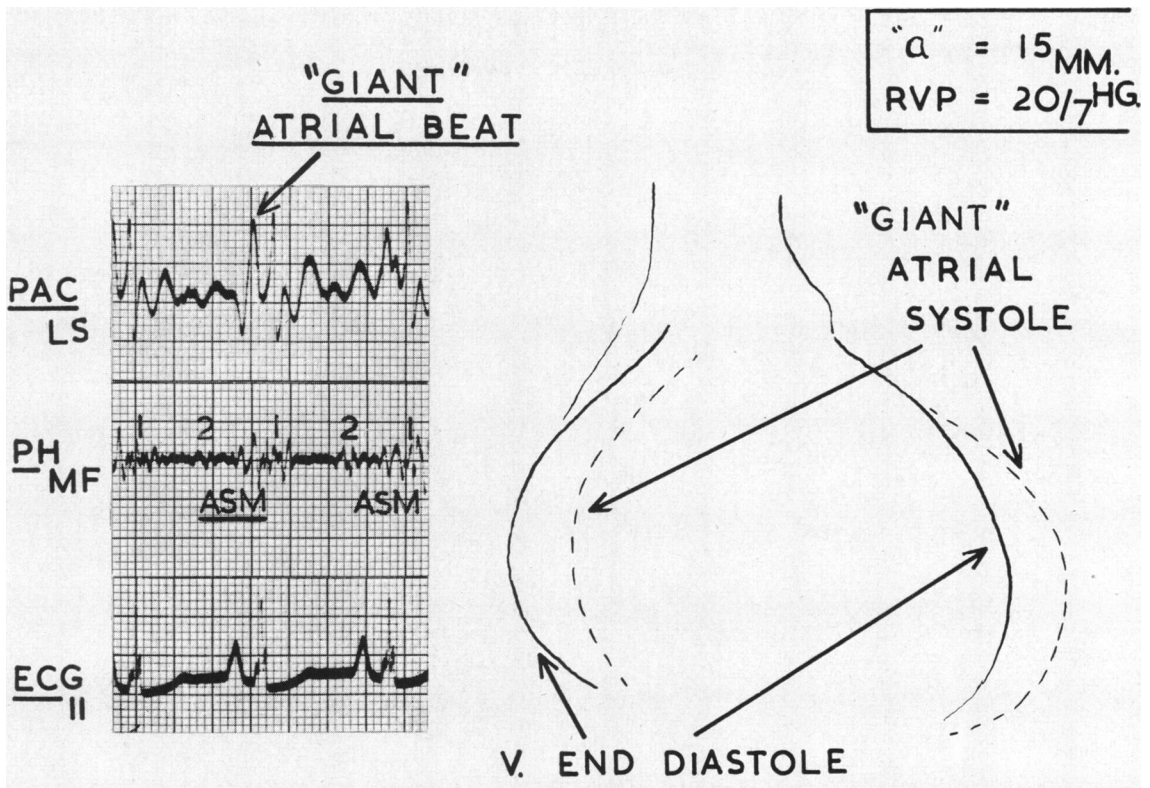


FIG. 8.—Giant atrial beat in the praeordial acceleration cardiogram (PAC) over the lower sternum (LS) in cardiomyopathy, accompanied by an atrial systolic murmur (ASM) in the phonocardiogram (PH). Line diagram of PA radiogram with extensive cardiac movement in atrial systole, as seen at thoracotomy, indicated by dotted line. *a* and RVP=right atrial *a* wave and right ventricular pressure. Time scale: large division=0.2 sec. V.=ventricular.

is increased pressure accompanying atrial contraction, very little associated movement of blood into the ventricle is possible. This is well seen in tight mitral stenosis at operation, where the main movement of the atrium during atrial contraction is of the appendix, the walls of the atrium and ventricle moving very little. For this reason the acceleration cardiogram in tight mitral stenosis shows slight, if any, increase in the size of the atrial beat compared with the normal (Fig. 9). In this patient with cardiomyopathy observation at operation had shown that the major part of right ventricular filling was accomplished during atrial systole and this accounted for the giant atrial beat seen in the acceleration cardiogram. In general, therefore, a giant atrial beat associated with an atrial systolic murmur suggests that the murmur is functional, due to increased atrial stroke-volume, and does not indicate stenosis.

#### VENTRICULAR DIASTOLIC RAPID INFLOW IN DISEASE

The heart in constrictive pericarditis is often spoken of as still, but, if we watch its movement at thoracotomy, the reverse is usually seen to be true. The heart dilates very rapidly in early diastole, as blood rushes into it under high pressure from the veins, and then, when the limit of dilatation imposed by the rigid constricting pericardium is reached, this movement is suddenly arrested, as though with a shudder, and the heart remains still for the rest of diastole. In certain unusual cases where pericardial thickening is very great, hardly any movement of the heart is seen until the pericardial coverings are removed.



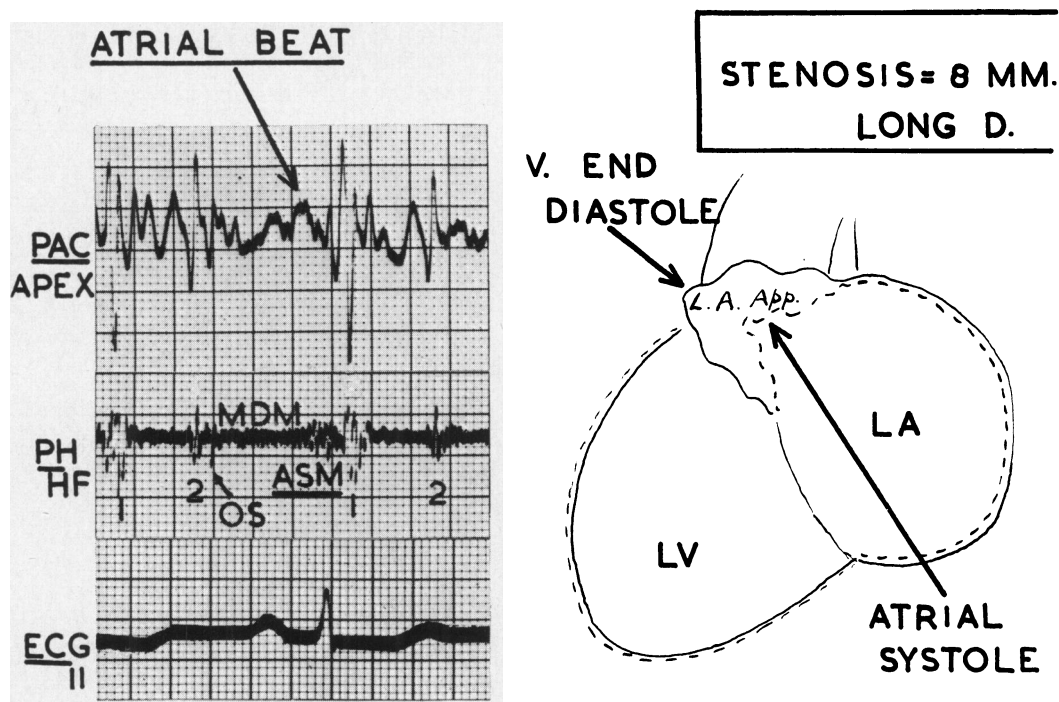


FIG. 9.—Small atrial beat in the præcordial acceleration cardiogram (PAC) at the apex in tight mitral stenosis, coinciding with an atrial systolic murmur (ASM) in the phonocardiogram (PH). Line diagram of heart, as seen at thoracotomy: dotted lines indicate insignificant movement of left atrial (LA) and left ventricular (LV) walls during atrial systole, with greatest movement of left atrial appendix (LA App.). OS=opening snap. MDM=mid-diastolic murmur. V=ventricular. D=diameter.

The præcordial pulsations resulting from abrupt halting of rapid ventricular filling are well recorded in the acceleration cardiogram. This usually shows initial outward acceleration of the chest wall followed abruptly by deceleration, as cardiac filling is arrested by the rigid pericardial casing. At the point of change from acceleration to deceleration, an upward stroke is recorded in the præcordial acceleration cardiogram, the “diastolic rapid inflow check,” and the early diastolic sound is recorded in the phonocardiogram (Fig. 10) (Mounsey, 1957). Following successful operation, the diastolic rapid inflow check became smaller, less steep, and later in time, although it could still be brought out by deep inspiration (Fig. 11).

Operation for constrictive pericarditis offers an opportunity to observe abnormally rapid ventricular filling, but a similar process probably takes place in heart failure from other causes. In myocardial failure, however, as opposed to constrictive pericarditis, the halting of rapid ventricular filling consequent on the high venous pressure is usually less abrupt: the brake on ventricular filling here lies in the myocardium instead of the pericardium. In the præcordial acceleration cardiogram an augmented diastolic rapid inflow beat is seen, which reflects the palpable diastolic beat, consequent on rapid ventricular filling. The rapid inflow check, however, terminating this beat, is less steep and abrupt than in a typical case of constrictive pericarditis, indicating the more gradual halting of rapid ventricular filling by the myocardium (Fig. 12).

Mitral valve disease forms another group in which diastolic rapid inflow is pathological and the præcordial pulsations, recorded in the acceleration cardiogram, reflect the different mechanisms of left ventricular filling in mitral stenosis and mitral regurgitation. In both conditions the left atrial pressure is raised at the beginning of diastole when the mitral valve opens, but, whereas in mitral stenosis filling is restrained by the small aperture, in regurgitation it is abnormally rapid.

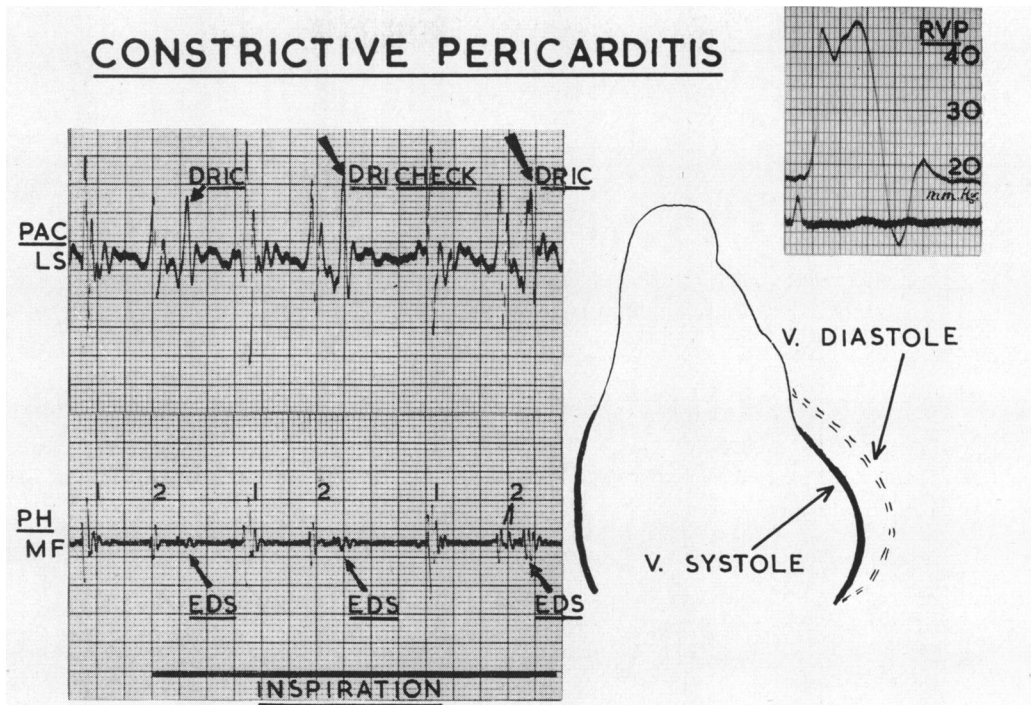


FIG. 10.—Diastolic rapid inflow (DRI) check in the præcordial acceleration cardiogram (PAC) over the lower sternum (LS) in constrictive pericarditis. The check coincides with the early diastolic sound (EDS) in the phonocardiogram (PH), and with the early diastolic dip in right ventricular pressure (RVP). Both DRI check and EDS increase on inspiration. Line diagram of PA radiogram, with filling movement of heart, as seen at thoracotomy, indicated by dotted lines. V=ventricular.

A large diastolic rapid inflow beat, therefore, is seen in the acceleration cardiogram of mitral regurgitation, indicating abnormally rapid filling (Fig. 13). In gross mitral regurgitation the heaving left ventricle sinks to rest about the period of diastolic rapid inflow: in such patients, therefore, both ventricular relaxation and ventricular filling combine to influence the præcordial acceleration cardiogram. In mitral stenosis, on the other hand, no clear diastolic rapid inflow beat is recorded. Instead, an opening check is seen, coinciding with the opening snap, this check being of small amplitude, since there is little general cardiac movement accompanying movement of the valve and ring (Fig. 14). Following the opening check is a small rapid inflow check, which initiates the mid-diastolic murmur. This rapid inflow check may coincide with completion of ventricular relaxation, for the left ventricle in mitral stenosis is seen to flick outwards at about this time in early diastole, when watched at operation.

In combined mitral stenosis and regurgitation, where regurgitation is considerable, a characteristic record is sometimes seen in the acceleration cardiogram, that combines features of both conditions (Fig. 14). In addition to an opening check, a diastolic rapid inflow check is recorded (0.08 seconds later), that is of unusually large size and high frequency: it coincides with a large third heart sound in the phonocardiogram. The pathogenesis of this large diastolic rapid inflow check seems uncertain, but it probably represents checking of abnormally rapid filling of the left ventricle in early diastole, as in pure mitral regurgitation. It is of interest that the mid-diastolic murmur is delayed until after the rapid inflow check, although blood is presumably entering the ventricle immediately after the opening check, which suggests that partial distension of the ventricle is necessary for the production of the murmur in these patients.

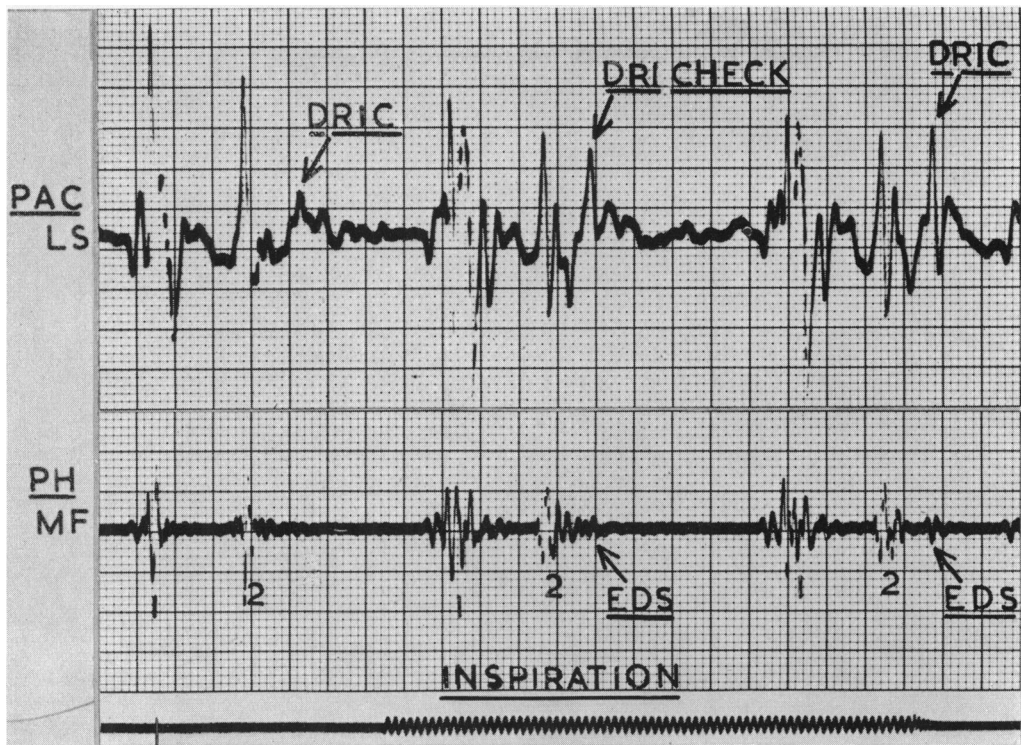


FIG. 11—The same patient, as in Fig. 10 after successful operation. Jugular venous pressure 5 cm. The DRI check is still present, but smaller and later than before operation. No clear early diastolic sound (EDS) is seen in the medium frequency phonocardiogram (PH MF), except on inspiration.

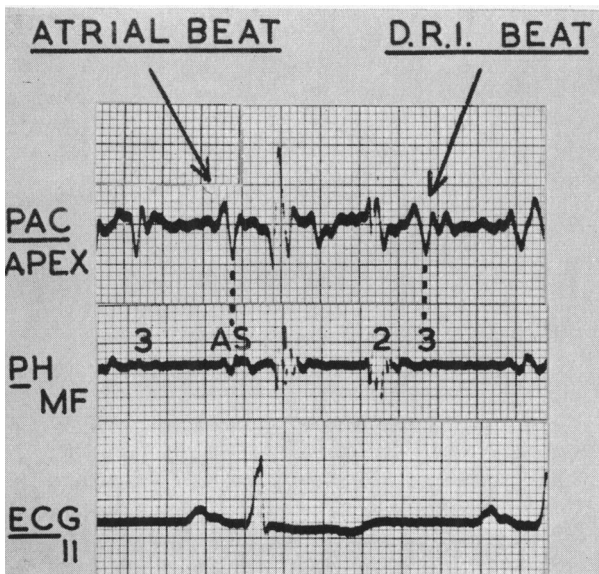


FIG. 12.—Large atrial beat and diastolic rapid inflow (DRI) beat in the præcordial acceleration cardiogram (PAC) at the apex in heart failure due to cardiomyopathy, with associated atrial sound (AS) and third heart sound (3) in the phonocardiogram (PH).

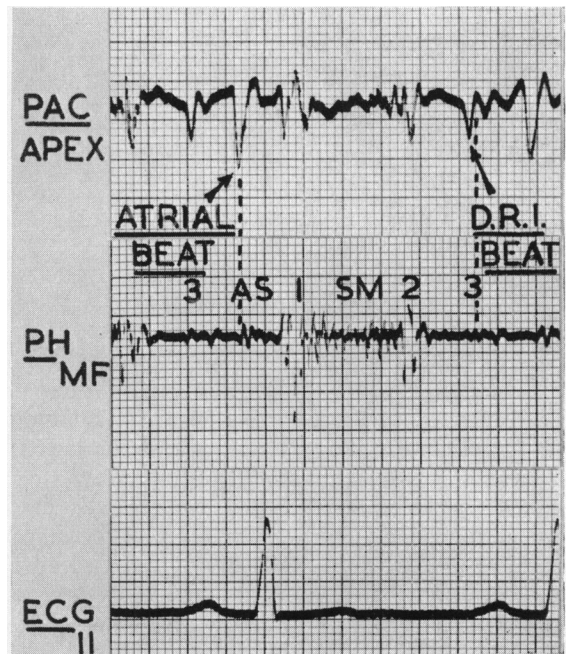


FIG. 13.—Large atrial beat and diastolic rapid inflow (DRI) beat in the præcordial acceleration cardiogram (PAC) at the apex in mitral regurgitation, with associated atrial sound (AS) and third heart sound (3) in the phonocardiogram (PH). SM=systolic murmur.

Although a large diastolic rapid inflow check initiating a mid-diastolic murmur has been found to indicate a relatively considerable degree of regurgitation in relation to the amount of stenosis, it has been found to occur where stenosis is tight enough to benefit by valvotomy and is, therefore, of limited value in selection of patients for mitral valve surgery.

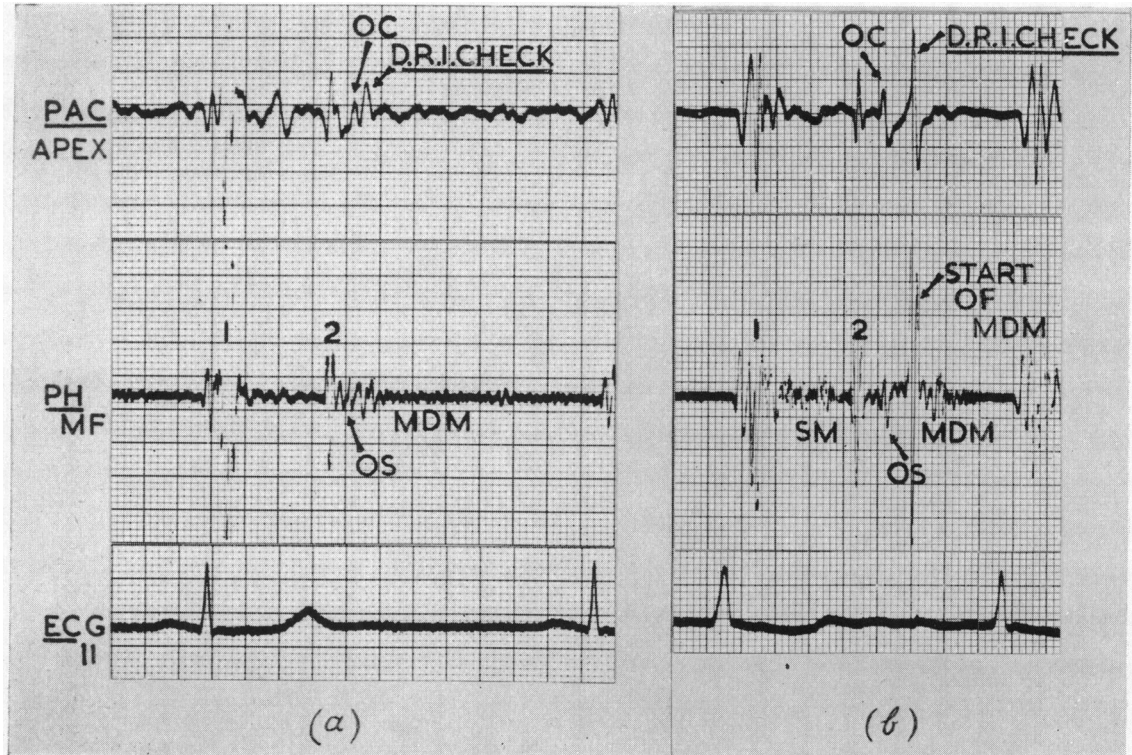


FIG. 14.—(A) Opening check (OC) in the præcordial acceleration cardiogram (PAC) at the apex in tight mitral stenosis, coinciding with the opening snap (OS) in the phonocardiogram (PH). Small diastolic rapid inflow (DRI) check, initiating mid-diastolic murmur (MDM). (B) Large diastolic rapid inflow (DRI) check, following opening check (OC), and initiating mid-diastolic murmur (MDM), in combined mitral regurgitation and stenosis. SM=systolic murmur.

The *site* on the præcordium where the diastolic rapid inflow beat was best recorded varied with the cardiac lesion. In left or right heart failure, the abnormally large diastolic rapid inflow beat was often widely palpable over the whole præcordium, but it was best recorded over the affected ventricle. In constrictive pericarditis the diastolic rapid inflow check was often easily felt over the whole præcordium; it was usually best recorded about its centre. In mitral stenosis, on the other hand, the abnormalities of rapid inflow gave rise to small pulsations in the acceleration cardiogram, which were only recorded directly over the apex. In general, it was not easy to tell the site of the cardiac lesion from the area where the pulsation was best recorded in the acceleration cardiogram, due to the wide-spread propagation of all but the smallest cardiac impulses over the whole præcordium. A more reliable guide to the presence of a right heart lesion was increase in amplitude of the diastolic rapid inflow beat on deep inspiration, due to temporary increased filling of the right heart (Fig. 10 and 11). Conversely in left heart lesions the rapid inflow beat either diminished or remained unaltered on inspiration.

## SUMMARY AND CONCLUSIONS

The relationship between diastolic præcordial pulsations recorded with an accelerometer, the cardiac movements as observed at thoracotomy, and the heart sounds has been examined.

*Atrial Systole.* The atrial beat in the præcordial acceleration cardiogram in health is described. A giant atrial beat in the acceleration cardiogram and an atrial sound or murmur in the phonocardiogram are seen when increased active atrioventricular filling supplements passive diastolic filling, in the presence of a stiff hypertrophied ventricle, giving rise to giant atrial contraction. Right-sided giant atrial contraction may sometimes be met where the hypertrophy is of the left ventricle, due to splinting of the right ventricle by the hypertrophied interventricular septum.

A giant atrial beat is not seen in mitral stenosis, in spite of increased left atrial systolic pressure, since little transfer of blood from atrium to ventricle accompanies atrial contraction, owing to the stenosis. This is in contrast to the giant atrial beat of ventricular hypertrophy and hence may help to determine whether an atrial systolic murmur indicates stenosis or increased atrial stroke-volume from ventricular hypertrophy.

*Ventricular Diastolic Rapid Inflow.* The diastolic rapid inflow beat in the præcordial acceleration cardiogram in health is described. In constrictive pericarditis the acceleration cardiogram gives evidence of abrupt halting, by the rigid pericardium, of rapid ventricular filling: abnormalities of filling may be detected in this record where a clear early diastolic sound of constrictive pericarditis is absent.

In myocardial failure halting of rapid ventricular filling is less abrupt than in constrictive pericarditis and this is reflected in the præcordial acceleration cardiogram.

The differing mechanics of left ventricular filling in mitral stenosis and mitral regurgitation are mirrored in this record, which shows a large diastolic rapid inflow beat in mitral regurgitation and no clear rapid inflow beat in mitral stenosis.

The præcordial acceleration cardiogram, which gives an optical record of præcordial pulsations, helps to form a link between heart sounds and murmurs and the underlying cardiac movements and forces that produce them.

*General Note to Legends.*

*Time scale:* large division=0.1 sec., except in Fig. 8, where it is 0.2 sec.

*Electrocardiogram.* This has been added to the simultaneous præcordial acceleration cardiogram and phonocardiogram, by means of a common reference tracing.

I should like to thank Dr. William Evans, Dr. Wallace Brigden, Mr. Vernon Thompson, and Mr. Geoffrey Flavell for help and encouragement in the preparation of this paper, and Professor Dorothy Russell and her staff for the morbid anatomical findings. I should also like to thank Mr. William Dicks, Mr. Raymond Ruddick, Mr. Frederick Harrison, and Miss Gwen Clarke for their technical help.

## REFERENCES

- Bernheim (1910). *Rev. Médecine*, 30, 785.  
 Brigden, W. (1957). *Lancet*, 2, 1179 and 1243.  
 Elliott, R. V., Packard, R. G., and Kyrakis, D. T. (1954). *Circulation*, 9, 281.  
 Evans, W. (1942). *Brit. Heart J.*, 5, 205.  
 Harrison, F. G. (1957). *J. Soc. Cardiol. Technicians of Great Britain*, 3, 65.  
 Mounsey, J. P. D. (1957). *Brit. Heart J.*, 19, 259.