

EBSTEIN'S SYNDROME

BY

KAMTA P. SINHA, JOSEPH F. URICCHIO, AND HARRY GOLDBERG

From the Brith Sholom Cardiopulmonary Laboratory and the Division of Medicine, Hahnemann Medical College and Hospital and the Bailey Thoracic Clinic, Philadelphia, Pennsylvania, U.S.A.

Received March 3, 1959

In 1866, Ebstein described the post-mortem findings of a 19-year-old boy who died in congestive heart failure. The tricuspid valve was replaced by a large membrane, originating from the annulus fibrosus and from the anterior and posterior portions of the endocardium of the right ventricle and the interventricular septum and the septal cusp was displaced downwards 15 mm. from the annulus a patent foramen ovale was uncovered and multiple defects were present in the septum primum.

Since this original report, over 100 cases have been described under the various titles of Ebstein's disease, Ebstein's malformation, Ebstein's anomaly, or Ebstein's syndrome. Common to each was the deformity and displacement of the tricuspid valve and in some (Malan, 1908; Heigle, 1913; Blackhall-Morrison, 1923) it represented the only abnormality. In most, isolated or combined defects of the atrial and ventricular septum were noted, and frequently the foramen ovale was patent.

The present review records our experience with this syndrome. All cases with tricuspid valve deformity are included and the various associated cardiac defects are described. Our series consists of all 11 patients studied at the Hahnemann Medical College and Hospital from 1953 until 1958. The youngest was 6 months and the oldest was 49 years old. Six of our cases were female.

SYMPTOMATOLOGY

The symptoms in Ebstein's syndrome are usually mild. Three of our patients were asymptomatic at the time of examination. Similar observations were made by Marxsen (1886), Malan (1908), Heigel (1913), Wood (1956), and Mayer *et al.* (1957). In our series all the patients except one developed fatigue and dyspnæa, which are the most common symptoms observed.

Cyanosis was present in 85 per cent of the cases in which this sign was mentioned. Kilby *et al.* (1956) reported cyanosis in all their 9 cases and emphasized the diagnostic importance of this finding, although Wood (1956) believes that cyanosis is not an important feature of this disease. Mayer *et al.* (1957) reported cyanosis in 6 of their 10 cases, while Kjellberg *et al.* (1955) reported it in only one of their four. In our series 5 out of 11 cases had cyanosis: in two, cyanosis was present at birth, in one, it developed at the age of 47, and in one, it was present only on exposure to cold, while another developed it only after exertion.

We think that the presence of cyanosis should not be emphasized as an essential feature for the diagnosis of Ebstein's syndrome. Although it is a common feature of the symptomatic pattern, cases without a right-to-left shunt may never develop central cyanosis despite the presence of an interatrial communication. The clinical diagnosis of Ebstein's syndrome will be made more frequently if less stress is placed on the presence of cyanosis and greater consideration is given to other features of the syndrome.

PHYSICAL FINDINGS

Seven of our eleven patients had evidence of significant hepatomegaly. However, only three had peripheral œdema and neck vein distension. The neck veins were normal in 8 of our patients.

* This work has been supported by the Mary Bailey Foundation for Heart and Great Vessel Research, Philadelphia.

TABLE I
ELECTROCARDIOGRAPHIC FINDINGS IN EBSTEIN'S SYNDROME

Case No.	P wave	P-R interval	QRS-T complex	Others
1	Deformed	—	RBBB (C)	Frequent arrhythmias
2	Normal	Prolonged	RBBB (C)	Occasional arrhythmias
3	Very tall	Prolonged	RBBB (C)	Inverted T wave V1-V5
4	Tall	Prolonged	RBBB (Inc.)	Frequent arrhythmias
5	Normal	—	Normal	Normal
6	A.F.	—	RBBB (C)	Occasional arrhythmias
7	Tall	—	RBBB (Inc.)	Occasional arrhythmias
8	A.F.	—	RBBB (Inc.)	Normal
9	Tall	—	RBBB	
10	A.F.	—	RBBB (C)	Nothing particular
11	A.F.	—	RBBB (Inc.)	Nothing particular

A.F. for atrial fibrillation.

RBBB (C) for right bundle-branch block (complete).

RBBB (Inc.) for right bundle-branch block (incomplete).

Nadas (1957) reported distension of neck veins as a common feature in his series, but in Wood's experience (1956) they may be normal in some. In three cases, the enormous right atrium accommodated most of the regurgitant blood without increase in central venous pressure.

Cardiac auscultation revealed a rather constant pattern in our series, comparable with others recently reported. Ten of our eleven cases had a systolic murmur at the apex, which was heard also at the third and fourth left intercostal space to the left of the sternum. The murmur was blowing in character and its intensity varied from grade 2 to 4. Three of our cases had an early grade 1 to 2 blowing diastolic murmur at the apex, while four had a third heart sound. In one, the auscultatory findings were normal. More than half a dozen cases have been reported without a murmur.

We could not appreciate a systolic thrill at the apex or the xiphoid area in our cases, but others consider systolic thrills of great diagnostic value in the study of this syndrome.

Electrocardiogram. Incomplete or complete right bundle-branch block is a very common feature of Ebstein's syndrome. Ten out of 11 in our series had this finding. A review of reported cases reveals the presence of right bundle-branch block in 88 per cent of those in whom cardiograms were taken.

Sodi-Pallares (1956) postulates the presence of right bundle-branch block on the basis of the increased right atrial pressure acting on the upper part of the right septal surface. We feel that the associated presence of an atrial septal defect or patent foramen ovale may also contribute to the pattern of rSR' in V1 and RS in V6. According to Sodi-Pallares (1956) a QR pattern from V1 to V4-V6 with negative T waves in young patients with cyanosis is practically pathognomonic of Ebstein's syndrome. In his experience the combination of W-P-W, type B, and cyanosis has never been noticed except in Ebstein's syndrome. By W-P-W, type B, he means that the QRS complex in V1 is negative: if the QRS complex is positive in V1 he refers it to be as type A. None of our cases had either of these features.

Sodi-Pallares and Marcico (1955) reported the right heart intracavitary tracing in Ebstein's syndrome, and clearly demonstrated the different pattern of the tracing in superior and inferior portions of the right atrium. Yim and Yu (1958) reported intracavitary tracings in this syndrome and arrived at a similar conclusion. According to these authors the intracavitary electrogram is diagnostic in Ebstein's syndrome.

For obvious reasons most of the cases of Ebstein's syndrome showed atrial dysfunction. Four of our cases had atrial fibrillation. Five of the remaining seven had tall and abnormal P waves. Three had a prolonged P-R interval. A similar pattern of atrial dysfunction has been reported.

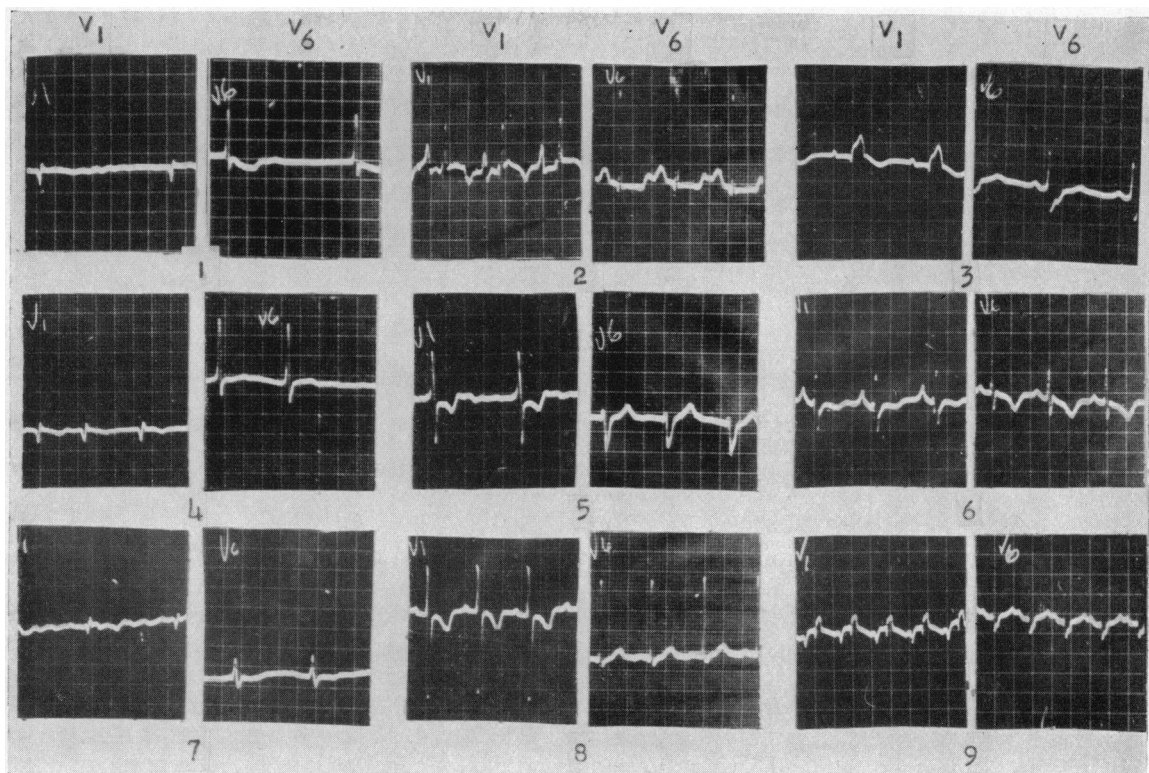


FIG. 1.—Electrocardiograms of nine patients. (Leads V1 and V6.) For interpretation, see text.

Various arrhythmias are seen in Ebstein's syndrome and sometimes they may cause death. Ten of our patients had paroxysmal bouts of tachycardia. They were supraventricular in origin in all but one. The proximity of the A-V node and common bundle of His to the associated deformity best explains the marked irritability of the conduction apparatus.

Radiological and Angiocardiographic Studies. Many have emphasized the diagnostic configuration of the heart in the frontal projection in Ebstein's syndrome. A globular contour of the heart is common because of a combination of enlargement of the heart in the transverse diameter and an inconspicuous supracardiac shadow. The transverse diameter is increased by the huge dilated right atrium. The small supracardiac shadow is due to the hypoplastic aorta and pulmonary artery. The lung fields may reveal decreased pulmonary blood flow. In our series, eight out of 11 had the so-called globular contour of the heart shadow (Fig. 2). In all cases the heart size was moderately enlarged. The lung fields were clear in six. A hypoplastic aorta and pulmonary artery were noted in seven.

Recently more stress has been given to angiocardiographic studies in this syndrome. Twenty-five cases analyzed by this technique have been reported. The procedure is not without risk: most of the reported cases developed disturbing arrhythmias during procedure, and one died during angiocardiography (Nadas, 1957). Reynolds in 1950 demonstrated a huge right atrium, delayed emptying of the right atrium, and faint opacification of pulmonary artery in this syndrome. The description of Baker *et al.* (1950) is essentially the same, and in addition, left atrial opacification through an atrial septal defect was noted. Engle *et al.* (1950) demonstrated beautifully the visualization of the right atrium followed by left atrial, left ventricular, and aortic opacification. Soloff *et al.* (1951) clearly pointed out the displaced tricuspid notch and the small right ventricle.

Angiocardiography was done in 5 of our cases without complication (Fig. 3). It invariably

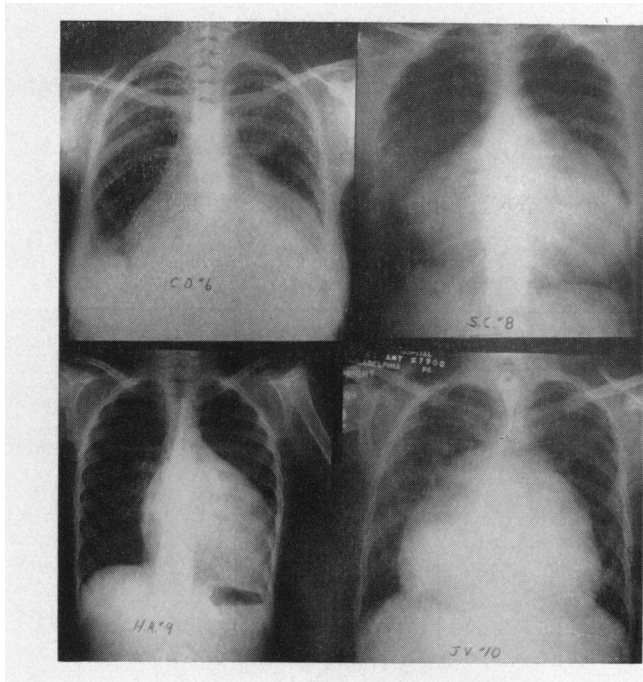


FIG. 2.—Postero-anterior X-ray of the chest. For interpretation, see text.

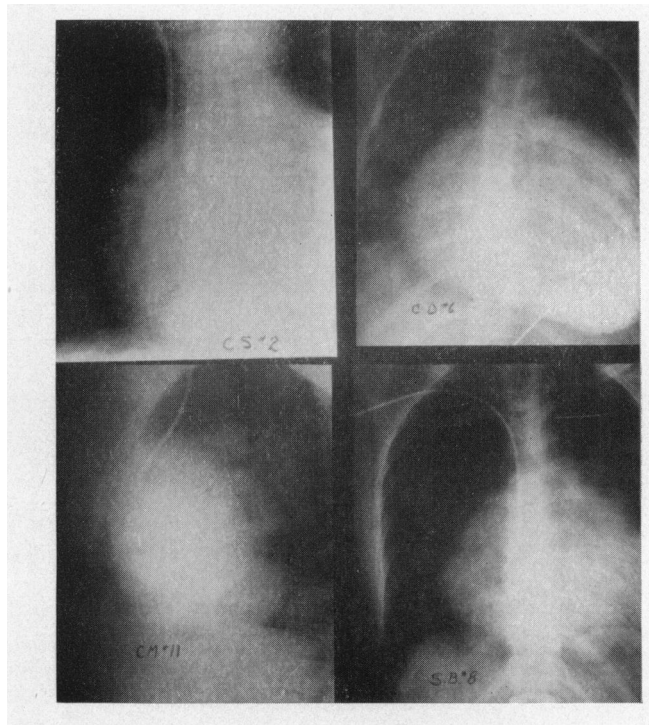


FIG. 3.—Angiocardiograms of four patients. For interpretation, see text.

demonstrated the huge right atrium, but the dye was so diluted in this huge chamber that its further course could not be traced accurately.

Cardiac Catheterization. Cardiac catheterization has been performed in nearly half of the cases reported. Serious arrhythmias were common during the procedure and at least six deaths have been reported (Baker *et al.*, 1950; Schaede, 1951; Blacket *et al.*, 1952; Campbell, 1953; and Nadas, 1957).

Cardiac catheterization was done in all of our cases (Table II and Fig. 4). No serious compli-

TABLE II
DATA FOUND AT CARDIAC CATHETERIZATION IN EBSTEIN'S SYNDROME

Case*	Course of the catheter	BA oxygen saturation	Miscellaneous
1	Normal	95.0%	All findings within normal limits
2	Normal	78.3%	RV appeared to be small and RA looked very big
3	Normal	91.3%	All findings within normal limits
4	Catheter entered LA	60.7%	RV P 78/2; PA P 78/40 mm. Hg
5	Normal	90.0%	All findings within normal limits
6	Catheter kept coiling in RA	90.0%	"Ventricularization" of RA pressure tracing
7	Normal	91.0%	All findings within normal limits
8	Catheter kept coiling in RA	Not obtained	All findings within normal limits
9	Normal	80.0%	All findings within normal limits
10	Catheter kept coiling in RA and then entered LA	68.6%	Catheter took quite abnormal course and entered the left ventricle
11	Catheter kept coiling in RA	93.5%	On left heart catheterization, LA P was found to be high

RA for right atrium
BA for brachial artery
RV for right ventricle

P for pressure
PA for pulmonary artery
LA for left atrium

NOTE—Right atrial pressure and pressure tracing were normal in all except Case 6 where RA and RV tracings looked alike.

* There was no evidence of a shunt in 8 cases. In 3 cases there was a right-to-left shunt.

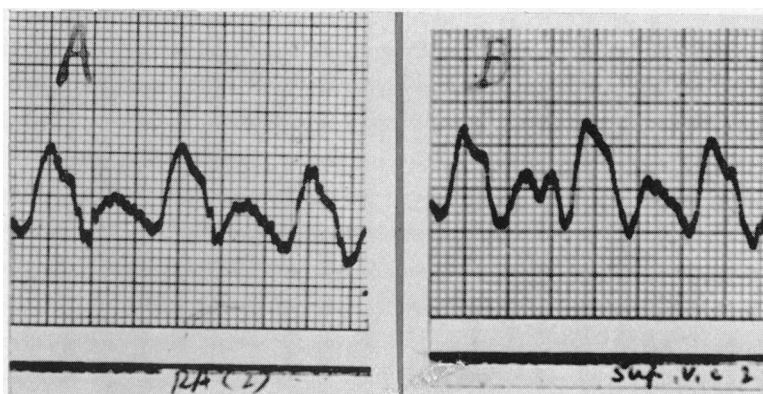


FIG. 4.—Pressure tracings of the right atrium (A) and superior vena cava (B) of Case 6, showing the similarity of the atrial tracing to a ventricular tracing.

cations except for arrhythmias were encountered. Four cases had arterial saturations below 90 per cent. In four the catheter coiled in the huge right atrium and could not be advanced. The right atrial pressure curve revealed a prominent V wave in many cases. A ventricular curve in

the superior part of the right atrium was observed in one of our cases—a finding that has been reported by others as well (Broadbent *et al.*, 1953; Wright *et al.*, 1954).

Surgical Intervention

Kirklin in 1954 treated one of his cases by closing the atrial septal defect to abolish the right-to-left shunt. However, in the presence of marked tricuspid regurgitation such a procedure is usually of little help. Three of our cases were treated surgically. In two of them partial amputation of the right atrium was carried out, while in one cross-polar plication of the tricuspid annulus was attempted.

PROBLEM IN DIAGNOSIS

Almost all the recently published series on Ebstein's syndrome claim that the clinical diagnosis of this entity can be made. The natural history of the disease, the characteristic auscultatory findings, the suggestive electrocardiographic pattern, and the diagnostic radiological findings are said to be of major assistance. Although suggestive of the syndrome this clinical pattern is not pathognomonic in our experience. One has to resort to cardiac catheterization and angiocardio-graphy, and still there are rare cases where the diagnosis cannot be established. Two cases cited below, which presented all the features of Ebstein's syndrome clinically, illustrate this point well.

Case 1. A woman, aged 22, was admitted to Hahnemann Medical College and Hospital in 1958. The history revealed that she was born with a heart murmur, and had practically normal growth and development, with no history of cyanosis. At the age of ten years she developed peripheral oedema and a diagnosis of right heart failure was made. Since then she was treated by digitalis, diuretics, and a low salt diet. Despite all these symptoms, she finished high school and was attending college regularly. From 1956 she developed progressive fatigue and dyspnoea. Finally she developed cyanosis. At the time of admission she was extremely dyspnoeic. There was generalized pitting oedema. The pulse rate was 84 a minute and grossly irregular. The blood pressure was 105/64. The lips and nailbeds were cyanotic and the neck veins were prominent. The thoracic cage was deformed with marked kyphoscoliosis. The apical impulse was in the sixth left intercostal space in the midclavicular line. It was forceful. She had a loud mitral 1st sound and a grade 2 to 3 blowing systolic murmur heard at the apex and also at the third left intercostal space by the side of the sternum. There was a grade 1 to 2 early diastolic murmur best heard at the apex, and a third heart sound. Auscultation of the lungs revealed bilateral rales. The liver was enlarged down to the right iliac crest. The spleen was palpable five fingers below the left costal margin. There was severe pitting oedema of the extremities. The electrocardiogram revealed atrial fibrillation, incomplete right bundle-branch block, and marked ventricular irritability. Radiological studies revealed a globular contour of the large heart, and the pulmonary vascular markings were increased.

A right heart catheterization was attempted, but the catheter coiled repeatedly in the huge right atrium and could not be manoeuvred into the right ventricle. The pressure in the right atrium was increased to 14 mm. Hg and the atrial curve was indicative of tricuspid regurgitation. However, no specific diagnosis could be reached because the patient was too sick to attempt further investigation. During her hospital stay, the patient was treated with digitalis, potassium, ammonium chloride, thiomerin, diamox, and diuril, with some improvement. However, one night she was found dead in bed, probably the result of an arrhythmia. Autopsy examination revealed a very large secundum type of atrial septal defect, a high ventricular septal defect, and a dilated tricuspid annulus. Otherwise the tricuspid valve was normal.

Case 2. A three-year-old white girl was admitted to Southern Division of Albert Einstein Medical Center in 1952. A cardiac murmur had been discovered at birth, and shortly after she developed progressive cyanosis. The child followed a down-hill course, and was admitted to the hospital in severe right heart failure, with obvious cyanosis of the lips, pitting oedema of the lower extremities, an enlarged liver, and distended neck veins. Heart sounds were rapid and faint. The patient died the following day. Post-mortem, the heart was much enlarged, and the right atrium and right ventricle were dilated. On opening the right atrium the foramen ovale was found to be patent. Except for slight thickening, the tricuspid valves were normal. In the region of the pulmonary valve cusps, the cusps were fused together leaving only a 2-mm. aperture. The left atrium and the left ventricle appeared normal.

Case 1 presented all the features of Ebstein's syndrome. However, autopsy examination revealed multiple congenital defects but no major deformity of the tricuspid valve. It was difficult then, in the absence of true displacement of the valve, to classify this case as Ebstein's syndrome.

Case 2 similarly was diagnosed as having Ebstein's syndrome until post-mortem examination proved it to be pulmonary stenosis. It is apparent that sometimes the diagnosis of Ebstein's syndrome can only be made at post-mortem examination, because of the non-specific nature of some of the clinical features of this syndrome.

DISCUSSION

In summary, it is emphasized that Ebstein's syndrome represents a heterogenous combination of congenital abnormalities, characterized chiefly by downward displacement of a rudimentary tricuspid valve. The symptomatic picture is generally mild, although cyanosis can occur due to an interatrial communication. Physical examination may show evidence of right heart failure. A systolic murmur is best heard along the left sternal border and a third heart sound is generally present. The hæmodynamic alterations are variable although decreased cardiac output, arterial oxygen unsaturation, and "ventricularization" of the right atrial curve are not uncommon. The catheter usually curls in the dilated right atrium. The electrocardiographic pattern is almost always that of complete or incomplete right bundle-branch block, while radiologically the heart generally has a globular contour. Surgery should be considered in cases of Ebstein's syndrome. Although reconstruction of the tricuspid valve is as yet not possible, treatment is available for correction of some of the associated anomalies. These can only be properly diagnosed by the performance of cardiac catheterization.

Patients with Ebstein's syndrome may be confused with cases of pulmonic stenosis and ostium atrioventricularis communis. The diagnosis may be difficult to establish clinically despite the apparently typical spectrum of the syndrome. For this reason, surgical intervention appears justifiable in the problem cases, especially if all the facilities for performing extracorporeal circulation are available.

REFERENCES

- Baker, C., Brinton, W. D., and Channell, G. D. (1950). *Guy's Hosp. Rep.*, **99**, 247.
 Blacket, R. B., Sinclair-Smith, B. C., Palmer, A. G., Halliday, J. H., and Maddox, J. K. (1952). *Australas. Ann Med.*, **1**, 26.
 Blackhall-Morrison, A. (1923). *J. Anat.*, **57**, 262.
 Broadbent, J. C., Wood, H. E., Burchell, H. B., and Parker, R. L. (1953). *Proc. Staff Meet. Mayo Clinic*, **28**, 79.
 Campbell, M. (1953). *Brit. Heart J.*, **15**, 363.
 Ebstein, W. (1866). *Arch. Anat. Physiol.*, **238**, 1866.
 Engle, M. A., Payne, P. B., Brunis, C., and Taussig, H. B. (1950). *Circulation*, **1**, 1246.
 Heigle, A. (1913). *Arch. Path. Anat.*, **214**, 301.
 Kilby, R. A., Dushane, J. W., Wood, H. E., and Burchell, H. B. (1956). *Medicine*, **35**, 161.
 Kjellberg, S. R., Mannheimer, E., Rudhe, U., and Jonsson, B. (1955). *Diagnosis of Congenital Heart Disease*. p. 518.
 Malan, G. (1908). *Zentralbl. allg. Path.*, **19**, 452.
 Marxsen, T. (1886). *Inaug. Diss. Kiel. Schmidt Klaunig*, **12**, 1886.
 Mayer, E. F., Nadas, S. A., and Ongly, A. P. (1957). *Circulation*, **16**, 1057.
 Nadas, S. A. (1957). *Pediatric Cardiology*. p. 459.
 Reynolds, G. (1950). *Guy's Hosp. Rep.*, **99**, 276.
 Schaede, A. (1951). *Deutsches Arch. klin. Med.*, **198**, 619.
 Sodi-Pallares, D. (1956). *New Bases of Electrocardiography*. p. 270.
 —, and Marcico, F. (1955). *Amer. Heart J.*, **49**, 202.
 Soloff, L. A., Stauffer, H. M., and Zatuchni, J. (1951). *Amer. J. med. Sci.*, **222**, 554.
 Wood, P. (1956). *Diseases of the Heart and Circulation*. p. 352. Eyre and Spottiswoode, London.
 Wright, J. L., Burchell, H. B., Kirklin, J. W., and Wood, H. E. (1954). *Proc. Staff Meet. Mayo Clinic*, **29**, 278.
 Yim, J. B., and Yu, P. N. (1958). *Circulation*, **17**, 543.