

THE ELECTROCARDIOGRAM IN SUBARACHNOID HÆMORRHAGE

BY

SAM SHUSTER

From the Medical Unit, Cardiff Royal Infirmary

Received July 27, 1959

Myocardial infarction has been found post mortem in many patients with strokes (Dozzi, 1937 and 1940; Wilson *et al.*, 1951; Stürup, 1952; and Glathie and Achor, 1958), and Dozzi (1939) found electrocardiograms diagnostic of myocardial infarction in 8 of 66 patients with a stroke. These observations have led to the view that many cerebrovascular accidents result from a preceding cardiac infarction. However, Burch *et al.* (1954) and Popov (1955) found electrocardiographic abnormalities in patients with cerebrovascular accidents in whom they could find no evidence of myocardial infarction. The possibility therefore arises that the abnormal electrocardiograms found in certain patients after a vascular incident may be the result of the cerebral episode itself rather than of concurrent or antecedent cardiac infarction.

Seven of the 17 patients reported by Burch *et al.* (1954) had a subarachnoid hæmorrhage, and 7 others had blood in the cerebrospinal fluid after a cerebral hæmorrhage or unclassified cerebrovascular accident. We therefore thought it possible that the electrocardiographic abnormalities they described might have been related to subarachnoid rather than to intracerebral hæmorrhage. The present investigation was made to study the frequency of cardiographic abnormalities in patients in whom there had been bleeding into the subarachnoid space.

RESULTS IN OUR PATIENTS

In every patient the clinical diagnosis of subarachnoid hæmorrhage was confirmed by the finding of a blood-stained or xanthochromic cerebrospinal fluid. Two groups of patients were studied.

(1) *Primary Subarachnoid Hæmorrhage.* All patients admitted to the Cardiff Royal Infirmary in a three-month period in whom a ruptured berry aneurysm was thought to have been the immediate cause of a subarachnoid hæmorrhage. There were twelve patients in this group and in eight an aneurysm was demonstrated by carotid angiography. Their ages were between 25 and 50, and five of them were under 40 years of age.

(2) *Secondary Subarachnoid Hæmorrhage.* All patients admitted to two wards of the hospital in the same period in whom subarachnoid bleeding seemed to have followed an intracerebral hæmorrhage (six) or an embolus (one patient). The ages of these patients lay between 40 and 60 years.

Twelve-lead electrocardiograms were taken on all patients as soon as possible after admission to hospital, and again at intervals of days or weeks. The concentration of Na, K, Cl, and CO₂ were measured in blood collected at the time of the initial cardiogram. In four patients with cardiographic abnormalities the stellate ganglion was anæsthetized on one or both sides by infiltrating the region of the sixth cervical transverse process with 5 ml. of 2 per cent procaine; in all four this produced a Horner's syndrome. Further electrocardiograms were then taken, and in three patients they were taken before and after 0.6 mg. atropine was injected intravenously.

Findings in Both Groups. The following features were found in patients from both groups. *Bradycardia* occurred in both groups and the heart rate was 70 a minute or less in eight patients. Ten patients had a *sinus arrhythmia* that was not related to phase of respiration. Transient atrial

fibrillation was noted in one patient, and three had multiple atrial ectopic beats. Ventricular ectopic beats were seen in only one patient.

The corrected *Q-T interval* (Goldberger, 1948) was short, ranging from 0.65 to 1.0 sec. for both groups with a mean of 0.82 second.

U waves were taller than 0.05 mV in 10 out of the 19 patients. They occurred in standard and præcordial leads of patients from both groups. Fewer than 5 per cent of normal electrocardiograms have *U waves* of this amplitude (Papp, 1940).

T Waves and S-T Segments

The findings in patients with a secondary subarachnoid hæmorrhage are described first, since they serve as a control to the patients in whom the hæmorrhage was primary.

(a) *Patients with Secondary Subarachnoid Hæmorrhage.* In all seven, *T waves* were depressed or inverted in leads V5 and V6, and in two there was slight S-T depression in these leads. All these patients had high blood pressure with clinical or radiological evidence of hypertensive heart disease, and the electrocardiographic abnormalities could therefore be attributed to left ventricular strain. In one patient the S-T segments were slightly depressed in the standard and anterior chest leads, but became iso-electric within 24 hours.

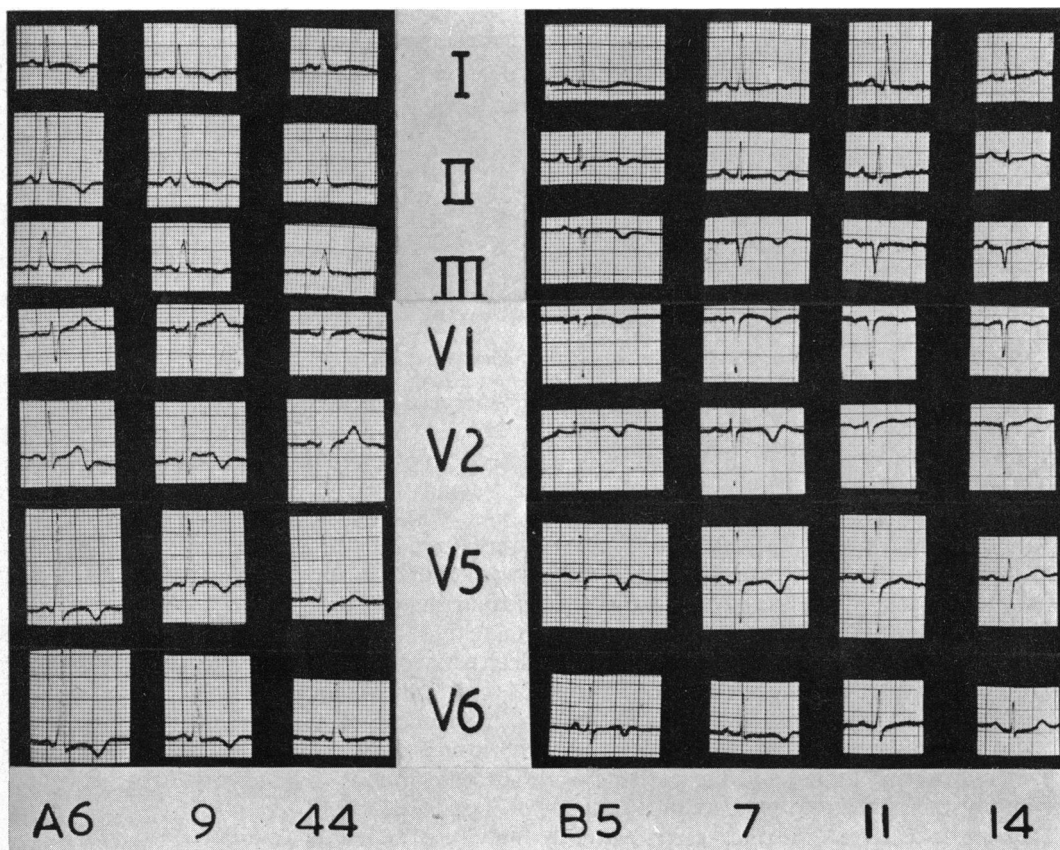


FIG. 1.—Electrocardiograms of two patients at intervals: (A) 6, 9, and 44 days, and (B) 5, 7, 11, and 14 days after subarachnoid hæmorrhage. (A) Man, aged 48. Aneurysm on anterior communicating artery. (B) Woman, aged 50. Aneurysm on right middle cerebral artery.

(b) *Patients with Primary Subarachnoid Hæmorrhage.* There were twelve patients in this group. In contrast with the previous group there were only three with a high blood pressure and only one with evidence of pre-existing hypertensive heart disease. In six of these, however, T waves were inverted in the standard leads, lead aVF, and in the præcordial leads (Fig. 1, 2, and 3). In two others the T waves were flat.

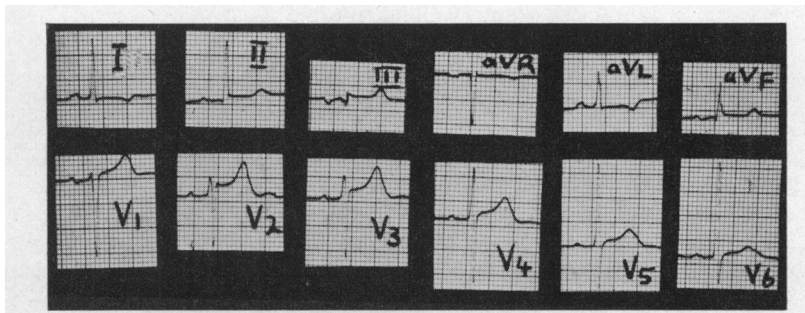


FIG. 2.—Electrocardiogram recorded 23 days after subarachnoid hæmorrhage. From a man, aged 45, with an aneurysm presumed but not demonstrated by carotid angiograms.

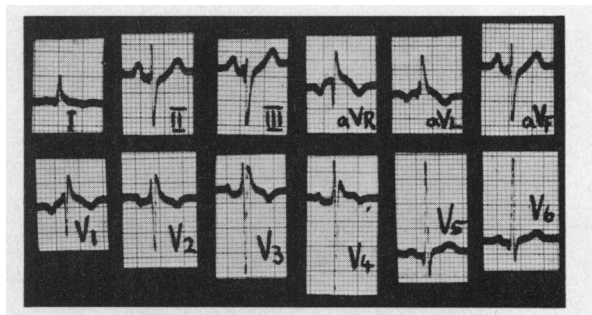


FIG. 3.—Electrocardiogram taken two days after subarachnoid hæmorrhage, from a man, aged 25, with an aneurysm on right middle cerebral artery.

Moderate displacement of S-T segments was seen in electrocardiograms from two patients (Fig. 2 and 3) and slight displacement was seen in tracings from three others (Fig. 1). In three, these abnormalities were observed within a few hours of the apparent time of onset of the subarachnoid hæmorrhage. Tall pointed T waves were found in three records. Thus significant abnormalities in the S-T segments and T waves were found in the electrocardiograms of about half of the patients with a primary subarachnoid hæmorrhage.

The electrocardiographic appearances were not related to the site of aneurysm, the site and degree of brain damage as assessed clinically and by electroencephalogram, or the cerebrospinal fluid pressure. Hypotension was not recorded in any of these patients and only three had a high blood pressure, although transient high or low blood pressure could have occurred after the hæmorrhage and before admission to hospital. The serum concentrations of sodium, potassium, and chloride were within normal limits, and the patients were not dehydrated. The plasma alkali reserve was likewise normal in the two patients in whom it was measured.

Subsequent Course. Further electrocardiograms were taken at intervals in eight patients: they showed a return towards normal in two within two days of the hæmorrhage, in two after seven days, and in one after fourteen days (Fig. 1B). In the three others, however, T wave depression was still present 17, 35, and 44 days after the hæmorrhage (Fig. 1A). In four patients with abnormal

T waves (one with primary and three with secondary subarachnoid hæmorrhage), electrocardiograms were taken before and after stellate ganglion block, carotid sinus pressure, and intravenous injection of atropine. The changes in the T waves and S-T segments observed after these procedures were not consistent.

Carotid angiography did not appear to affect the tracings.

Post-mortem Findings

The hearts of three of the patients who had died after a subarachnoid hæmorrhage from a berry aneurysm were examined. Two of the three had had electrocardiographic abnormalities, one with giant T waves and one with paroxysmal atrial fibrillation. The heart muscle was sliced in two directions in half-centimetre cuts. The coronary arteries, myocardium, and pericardium were normal in all three patients.

DISCUSSION

The results confirm that abnormal electrocardiograms may be found in patients with intracranial hæmorrhage (Burch *et al.*, 1954; and Popov, 1955). The most striking abnormalities both in the earlier and in the present investigations are T wave inversion and displacement of the S-T segments suggestive of myocardial infarction. In contrast with the findings of Burch *et al.*, the corrected Q-T interval was shorter than normal in the present series, which lends support to the suspicion of these workers that they were in fact measuring the Q-U and not the Q-T interval. In addition, atrial arrhythmias were common in our patients. There is no reason to suppose that rupture of a berry aneurysm in relatively young and otherwise healthy patients either produces myocardial infarction or is precipitated by it. It must be concluded therefore that displacement of the S-T segments is not indicative of infarction in these patients. The complete lack of clinical evidence of myocardial infarction supports this conclusion. It is of interest that similarly displaced S-T segments have been observed in patients with acute pancreatitis in whom there was no myocardial infarction post mortem (Pollock, 1959), and that various procedures, including even ingestion of water, may cause transient T wave inversion (Brotmacher, 1955).

The explanation of these abnormalities is not clear, although our findings suggest that blood in the subarachnoid space is a more important factor than damage to the brain. This may well account for the high incidence of subarachnoid hæmorrhage in the group of patients described by Burch *et al.* (1954), though three of them did not have a subarachnoid hæmorrhage, and similar cardiographic abnormalities may perhaps occasionally occur with intracerebral lesions.

Abnormal plasma sodium concentrations have been noted in patients with intracranial disease (Fourman and Leeson, 1958), and Burch *et al.* (1954) suggested that an abnormality of "electrolyte metabolism" might be responsible for the electrocardiographic findings in their patients, although they had no direct evidence on this point. Our finding of normal concentrations of sodium, potassium, and chloride in the plasmas of our patients does not favour this hypothesis.

Popov (1955) attributed the electrocardiographic abnormalities to a nervous mechanism. The present study does not allow of any conclusion on this point. However, with the exception of a normal P-R interval, the electrocardiographic findings in patients with subarachnoid hæmorrhage resemble the effects of vagal stimulation. Direct stimulation of the vagus in dogs (Robb and Turman, 1947) and indirect stimulation in man by carotid sinus pressure (Nielsen and Trier, 1939) will reduce the QTc interval. Transient vagal stimulation increases the amplitude of the T waves (Byer *et al.*, 1947) but prolonged stimulation leads to negative T waves and S-T depression (Manning *et al.*, 1937). Further investigation of the part played by the autonomic nervous system might therefore lead to a better understanding of the electrocardiographic abnormalities that may follow subarachnoid hæmorrhage.

Since submitting this paper I have given atropine (1/100 of a grain intravenously) to a patient

with electrocardiographic abnormalities associated with a subarachnoid hæmorrhage. The depressed S-T segments rapidly became more isoelectric, and this was clearly dissociated from any effect on the heart rate.

SUMMARY

Twelve-lead electrocardiograms were taken from patients at intervals after a subarachnoid hæmorrhage. Bradycardia, supraventricular arrhythmias, a short Q-Tc, and U waves were common. Abnormalities of the T waves and S-T segments that could not be attributed to heart disease or high blood pressure were found in about half of the patients in whom the hæmorrhage was due to rupture of a berry aneurysm.

Serum electrolyte concentrations were normal, and no abnormality was found post mortem in the hearts of three of the patients. The general similarity of the electrocardiograms in these patients with the changes produced by vagal stimulation suggests a possible explanation for the findings.

I am grateful to Mr. Charles Langmaid and Dr. J. D. Spillane for allowing me to see patients under their care, and to Professor Harold Scarborough and Dr. William Phillips for their valuable advice.

REFERENCES

- Brotmacher, L. (1955). *Lancet*, **2**, 1307.
Burch, G. E., Meyers, R., and Abildskov, J. A. (1954). *Circulation*, **9**, 719.
Byer, E., Toth, L., Ashman, R. (1947). *Amer. J. Physiol.*, **149**, 264.
Dozzi, D. L. (1937). *Amer. J. med. Sci.*, **194**, 824.
— (1939). *Ann. intern. Med.*, **12**, 1991.
— (1940). *Amer. J. med. Sci.*, **220**, 259.
Fourman, L. P. R., and Leeson, P. M. (1958). *Ciba Found. Colloq. on Aging*, **4**, 36.
Glathe, J. P., and Achor, R. W. P. (1958). *Proc. Mayo Clinic*, **33**, 417.
Goldberger, E. (1948). *Amer. Heart J.*, **36**, 141.
Manning, G. W., Hall, G., and Banting, F. G. (1937). *Canad. med. Ass. J.*, **34**, 9.
Nielsen, N. A., and Trier, M. (1939). *Amer. Heart J.*, **17**, 515.
Papp, C. (1940). *Brit. Heart J.*, **2**, 9.
Pollock, A. V. (1959). *Brit. med. J.*, **1**, 6.
Popov (1955), quoted by Simonson (1958).
Robb, J. S., and Turman, W. G. (1947). *Amer. J. med. Sci.*, **214**, 180.
Simonson, E. (1958). *Amer. Rev. Physiol.*, **20**, 123.
Stürup, H. (1952). *Acta med. Scand.*, **144**, 189.
Wilson, G., Rupp, C., Riggs, H. E., and Wilson, W. W. (1951). *J. Amer. med. Assoc.*, **145**, 1227.