




# NOTCH2NLC expanded GGC repeats in patients with cerebral small vessel disease

Yun-chao Wang <sup>1,2</sup>, Yu Fan,<sup>1,2</sup> Wen-Kai Yu,<sup>1</sup> Si Shen,<sup>1,2</sup> Jia-Di Li,<sup>1,2</sup> Yuan Gao,<sup>1,2</sup> Yan Ji,<sup>1,2</sup> Yu-Sheng Li,<sup>1,2</sup> Lu-Lu Yu,<sup>1</sup> Zi-Chen Zhao,<sup>1</sup> Shan-Shan Li,<sup>1</sup> Yao Ding,<sup>3</sup> Chang-He Shi <sup>1,2</sup>, Yu-ming Xu <sup>1,2</sup>

**To cite:** Wang Y, Fan Y, Yu W-K, et al. *NOTCH2NLC* expanded GGC repeats in patients with cerebral small vessel disease. *Stroke & Vascular Neurology* 2023;**8**: e001631. doi:10.1136/svn-2022-001631

► Additional supplemental material is published online only. To view, please visit the journal online (<http://dx.doi.org/10.1136/svn-2022-001631>).

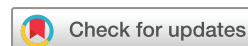Y-cW and YF contributed equally.

Received 7 April 2022

Accepted 21 September 2022

Published Online First

7 October 2022



© Author(s) (or their employer(s)) 2023. Re-use permitted under CC BY-NC. No commercial re-use. See rights and permissions. Published by BMJ.

<sup>1</sup>Department of Neurology, First Affiliated Hospital of Zhengzhou University, Zhengzhou, Henan, China

<sup>2</sup>NHC Key Laboratory of Prevention and Treatment of Cerebrovascular Diseases, Zhengzhou, Henan, China

<sup>3</sup>Department of Neurology, Xixiang Medical University, Xixiang, Henan, China

## Correspondence to

Professor Yu-ming Xu; [xuyuming@zzu.edu.cn](mailto:xuyuming@zzu.edu.cn)

Dr Chang-He Shi; [shichanghe@gmail.com](mailto:shichanghe@gmail.com)

## ABSTRACT

**Objective** GGC repeat expansions in the human-specific *NOTCH2NLC* gene have been reported as the cause of neuronal intranuclear inclusion disease (NIID). Given the clinical overlap of cognitive impairment in NIID and cerebral small vessel disease (CSVD), both diseases have white matter hyperintensity on T2-fluid-attenuated inversion recovery sequences of brain MRI, and white matter hyperintensity is a primary neuroimaging marker of CSVD on MRI. Therefore, we hypothesised that the GGC repeat expansions might also contribute to CSVD. To further investigate the relationship between *NOTCH2NLC* GGC repeat expansions and CSVD, we performed a genetic analysis of 814 patients with the disease.

**Methods** We performed a comprehensive GGC repeat expansion screening in *NOTCH2NLC* from 814 patients with sporadic CSVD. Their Fazekas score was greater than or equal to 3 points. Repeat-primed PCR and fluorescence amplicon length analyses were performed to identify GGC repeat expansions, and whole-exome sequencing was used to detect any pathogenic mutation in previously reported genes associated with CSVD.

**Results** We identified nine (1.11%) patients with pathogenic GGC repeat expansions ranging from 41 to 98 repeats. The minor allele frequency of expanded GGC repeats in *NOTCH2NLC* was 0.55%.

**Conclusion** Our findings suggest that intermediate-length and longer-length GGC repeat expansions in *NOTCH2NLC* are associated with sporadic CSVD. This provides new thinking for studying the pathogenesis of CSVD.

## INTRODUCTION

Cerebral small vessel disease (CSVD) affects arterioles, arteries, capillaries and venules in the brain.<sup>1</sup> Although the pathogenesis of CSVD remains unclear, genetics is currently recognised as one important explanatory factor.<sup>2</sup> Genome-wide cerebral association studies have identified several susceptible genetic loci associated with CSVD in various genetic backgrounds.<sup>3–5</sup> Some Mendelian forms of CSVD have been shown to be caused by some specific genetic mutations, such as *NOTCH3* mutations in cerebral autosomal dominant arteriopathy with subcortical infarcts and leukoencephalopathy,<sup>6</sup> *HTRA1* mutations

## WHAT IS ALREADY KNOWN ON THIS TOPIC

⇒ GGC repeat expansions in the human-specific *NOTCH2NLC* gene have been reported as the cause of neuronal intranuclear inclusion disease (NIID). Given the clinical overlap of cognitive impairment in NIID and cerebral small vessel disease (CSVD), both have white matter hyperintensity on T2-fluid-attenuated inversion recovery of MRI. Therefore, we speculate that GGC repeat expansions also play a role in CSVD.

## WHAT THIS STUDY ADDS

⇒ *NOTCH2NLC* GGC repeat expansions were not rare in the studied Han Chinese population with CSVD. Our findings suggest that intermediate-length and longer-length GGC repeat expansions in *NOTCH2NLC* are associated with sporadic CSVD. Our findings expand the scope of NIID-related disease.

## HOW THIS STUDY MIGHT AFFECT RESEARCH, PRACTICE OR POLICY

⇒ Our findings provide new insights into the molecular pathogenesis of CSVD, which provides clues to explore the mechanism of the disease. The mechanism of how abnormal GGC repeat expansion in the *NOTCH2NLC* gene increases the risk of CSVD remains unclear, and further study to establish suitable models is needed.

in cerebral autosomal recessive arteriopathy with subcortical infarcts and leukoencephalopathy<sup>7</sup> and *COL4A1* & *COL4A2* mutations in *COL4A*-related CSVD.<sup>8,9</sup>

Recently, GGC repeat expansions in the human-specific *NOTCH2NLC* gene were reported as a cause of neuronal intranuclear inclusion disease (NIID).<sup>10–11</sup> It is noteworthy that a significant fraction of adult-onset NIID presents leukoencephalopathy on T2-weighted MRI scans and fluid-attenuated inversion recovery (FLAIR), implicating severe white matter hyperintensities (WMHs) as an important NIID indicator.<sup>12–14</sup> Dementia is also a major clinical manifestation of sporadic NIID.<sup>15,16</sup> Consider that WMH is a primary neuroimaging marker of CSVD on

MRI,<sup>1</sup> and CSVD is a major vascular dementia and cognitive dysfunction contributor.<sup>17</sup> Therefore, we speculate that GGC repeat expansions also play a role in CSVD. We performed repeat-primed polymerase chain reaction (RP-PCR) and fluorescence amplicon length analyses to further investigate the relationship between GGC repeat expansions in *NOTCH2NLC* and CSVD.

## MATERIALS AND METHODS

### Enrolment

We recruited 814 sporadic Han Chinese patients with CSVD from the Neurology Department of the First Affiliated Hospital of Zhengzhou University between March 2018 and December 2021. The diagnosis was performed by neurologists and neuroimaging.<sup>18</sup> All the patients in our study underwent a neurological examination by two experienced neurologists. The inclusion criteria were as follows: (1) age  $\geq 18$  years and (2) a Fazekas score<sup>19</sup>  $\geq 3$  points for the degree of leukoencephalopathy. The exclusion criteria were as follows: (1) acute cerebral infarction lesions (lesions  $>20$  mm in diameter); (2) acute cerebral haemorrhage, cerebral vascular malformation due to cerebral aneurysm, history of subarachnoid haemorrhage or untreated cerebral aneurysm (diameter  $>3$  mm); (3) dementia due to neurodegenerative disease; (4) single-gene CSVD with known mutations; (5) with obvious non-vascular white matter lesions, such as metabolic encephalopathy, adult white matter dysplasia and multiple sclerosis; (6) a diagnosis of mental illness according to the Diagnostic and Statistical Manual of Mental Disorders V, tumours in the brain, traumatic brain injury and intracranial infection. In addition, two neurologists examined and recruited 1134 individuals matched for age and geography from the First Affiliated Hospital of Zhengzhou University as healthy control subjects. The Ethics Committee of the First Affiliated Hospital of Zhengzhou University approved this study.

### Statistical analyses

Our study recruited a total of 814 patients with CSVD and collected the demographic data, clinical features and imaging features of these patients, grouped them according to patients with GGC repeat expansion and without GGC repeat expansion in *NOTCH2NLC*, and performed a statistical analysis using SPSS V.19.0 software. Count data are expressed as frequencies. For the measurement data that conformed to the normal distribution, we used the independent sample t-test; for the measurement data that did not conform to the normal distribution, we used the Mann-Whitney U test; for qualitative dichotomous variables, when  $T \geq 5$ , we used Pearson's  $\chi^2$  test; when  $T < 5$  but  $T \geq 1$ , we used the continuity-adjusted  $\chi^2$  test; when  $T < 1$ , we used Fisher's exact test.  $P < 0.05$  was regarded for statistical significance.

### Magnetic resonance imaging

The Magnetic resonance imaging (MRI) assessment of the CSVD was independently assessed by two radiologists.

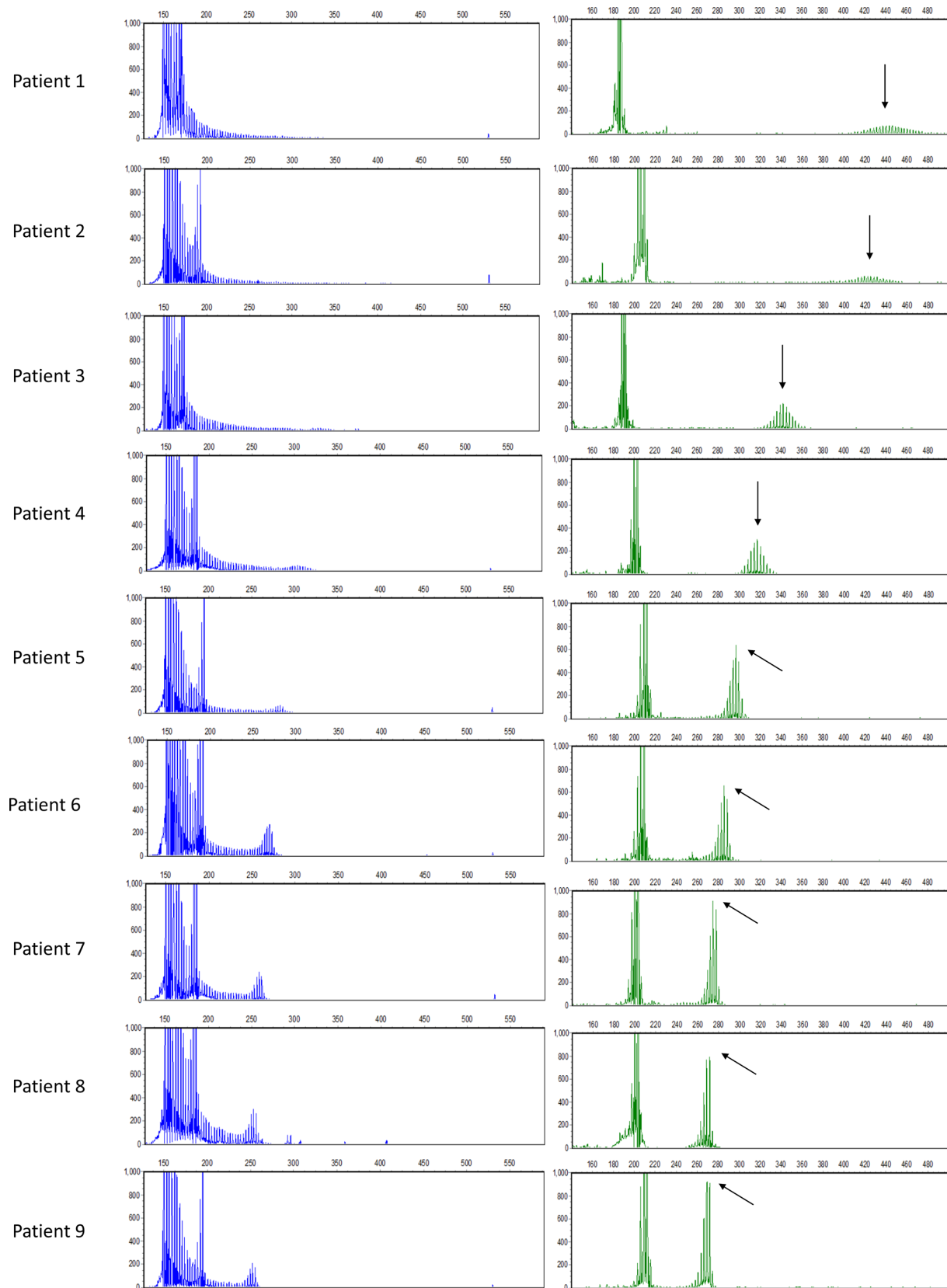
When there was disagreement, two radiologists consulted and decided. Finally, we selected patients with CSVD who met the inclusion and exclusion criteria. Evaluation of T1WI, T2WI, T2-FLAIR, susceptibility-weighted imaging (SWI) and diffusion-weighted imaging (DWI) scans of patients with CSVD were performed using Siemens magnetom Vida 3.0 T and PHILIPS Ingenia CX 3.0 T MRI. The parameters of Siemens magnetom Vida 3.0 T are T1WI: repetition time (TR) 200.0 ms, echo time (TE) 2.46 ms, slice interval 1.5 mm, slice thickness 5.0 mm, scanning time 28 s; T2WI: TR 4000.0 ms, TE 107 ms, slice interval 1.5 mm, slice thickness 5.0 mm, scanning time 48 s; T2-FLAIR: TR 6500.0 ms, TE 82 ms, slice interval 1.5 mm, slice thickness 5.0 mm, scanning time 1 min 18 s; SWI: TR 25.0 ms, TE 18.0 ms, slice interval 0.3 mm, slice thickness 1.5 mm, scanning time 2 min 43 s; DWI: TR 2800.0 ms, TE 68.0 ms, layer interval 1.5 mm, slice thickness 5.0 mm, scanning time 53 s. The parameters of PHILIPS Ingenia CX 3.0 T are T1WI: TR 250 ms, TE 2.3 ms, slice interval 6 mm, slice thickness 6 mm, scanning time 42 s; T2WI: TR 1873 ms, TE 70 ms, slice interval 6 mm, slice thickness 6 mm, scanning time 49 s; T2-FLAIR: TR 6500 ms, TE 130 ms, slice interval 1.5 mm, slice thickness 6 mm, scanning time 1 min 38 s; SWI: TR 31 ms, TE 7.2 ms, slice interval 0.5 mm, slice thickness 2 mm, scanning time 2 min 21 s; DWI: TR 1999 ms, TE 67 ms, slice interval 0.5 mm, slice thickness 6 mm, scanning time 24 s. WMH was assessed with brain MRI T2-FLAIR sequence, and cerebral microbleeds was assessed with brain MRI SWI sequence. The severity of WMH was assessed using the Fazekas scale.<sup>19</sup>

### DNA extraction and genetic analysis

We collected peripheral blood samples from the patients and extracted genomic DNA using DNA extraction kits (#DP1101, Bio Teke, Beijing, China) according to standard protocols. We performed RP-PCR and fluorescence amplicon length analyses.<sup>10 20</sup> In the patients screened for GGC repeat expansions, we performed whole-exome sequencing (WES) to detect any pathogenic mutations in previously reported genes associated with CSVD.<sup>20</sup>

## RESULTS

In our study, we screened for GGC repeat expansions in 814 patients with CSVD and found 9 patients with repeat expansions ranging from 41 to 98, which means 9 out of  $814 \times 2$  (0.55%) *NOTCH2NLC* alleles in patients with CSVD were found harbouring the expanded *NOTCH2NLC* GGC repeats; the minor allele frequency of expanded GGC repeats was 0.55%. The exact repeat numbers in the nine patients were 98, 92, 65, 57, 50, 46, 43, 42 and 41 units, as revealed by the fluorescence amplicon length analysis (figure 1). Previously, we screened for the GGC repeat expansion in the *NOTCH2NLC* gene in the 1134 healthy controls matched for age and geography.<sup>20</sup> All 1134 healthy controls were found harbouring fewer than



**Figure 1** Repeat-primed polymerase chain reaction and fluorescence repeat length analysis of patients harbouring GGC repeat expansions in *NOTCH2NLC*. The right graphs are the electropherograms of the product of fluorescence repeat length analysis. The highest signal peak of the expanded allele is indicated by a black arrow.

**Table 1** Comparison of demographic, clinical and neuroradiological characteristics between the patients with cerebral small vessel disease with GGC repeat expansion in *NOTCH2NLC* and those without GGC repeat expansion

Variables	Patients without GGC repeat expansion (n=805)	Patients with GGC repeat expansion (n=9)	P value
Age of onset (year)	60.86±10.43	59.33±10.07	0.664
Sex (male)	427 (53.0%)	5 (55.6%)	0.881
Muscle weakness	175 (21.7%)	3 (33.3%)	0.666
Sensory disturbance	87 (10.8%)	1 (11.1%)	1.000
Headache	123 (15.3%)	1 (11.1%)	1.000
Dizzy	342 (42.5%)	5 (55.6%)	0.430
Vision blurred	50 (6.2%)	0 (0.0%)	1.000
Speech impairment	60 (7.5%)	3 (33.3%)	0.024*
Stroke	288 (35.8%)	5 (55.6%)	0.219
Hypertension	542 (67.3%)	6 (66.7%)	0.966
Diabetes mellitus	157 (19.5%)	1 (11.1%)	0.834
Hyperlipaemia	267 (33.2%)	1 (11.1%)	0.297
Hyperhomocysteinaemia	230 (28.6%)	4 (44.4%)	0.499
Coronary artery disease	85 (10.6%)	1 (11.1%)	1.000
Family history/stroke	137 (17.1%)	2 (22.2%)	0.655
White matter hyperintensity	805 (100.0%)	9 (100.0%)	NA
Lacunar infarcts	582 (72.3%)	7 (77.8%)	0.715
Enlarged perivascular spaces	506 (62.9%)	5 (55.6%)	0.652
Brain atrophy	75 (9.3%)	2 (22.2%)	0.458

Data represent the mean±SD or the number (%) of subjects. For the measurement data that conform to the normal distribution, use the independent sample t test; for the measurement data that does not conform to the normal distribution, use the Mann-Whitney U test; for qualitative dichotomous variables, when  $T \geq 5$ , use Pearson's  $\chi^2$  test;  $T < 5$  but  $T \geq 1$  use continuity-adjusted  $\chi^2$  test; and  $T < 1$  use Fisher's exact test.  $P < 0.05$  was considered statistically significant.

\*Represents significant.

NA, not available.

40 GGC repeats. After comparison of demographic, clinical and neuroradiological characteristics between the two groups, only speech impairment was found to be significant between the two groups in table 1. The nine patients' demographic and clinical characteristics with expanded GGC repeats are shown in table 2. The nine patients' mean age at symptom onset was 59.33±10.07 years. The main complaints of all nine patients were mild neurological symptoms, such as dizziness, headache and limb weakness. Two of the patients had decreased muscle strength, and one patient had decreased limb sensation. Five had a history of stroke, for which cerebral infarction predominated. Patient 3 and patient 5 had a family history of stroke. The most prominent risk factors for cerebrovascular accidents were hypertension and hyperhomocysteinaemia.

Comparing the clinical features between the patients with CSVD with Fazekas score  $\geq 5$  (n=189) and Fazekas score  $\leq 4$  (n=616) in patients without GGC repeat expansion (online supplemental table 1), we found significant differences between the two groups in demographic characteristics, clinical manifestations and imaging findings. The patients in the Fazekas score  $\geq 5$  group were older,

and there were relatively more male patients. Regarding clinical manifestations, the patients in the Fazekas score  $\geq 5$  group had limb weakness and stroke more frequently than the Fazekas score  $\leq 4$  group, but the patients had fewer headache and dizziness than the Fazekas score  $\leq 4$  group. As for risk factors, the patients in the Fazekas score  $\geq 5$  group had more diabetes and hyperlipidaemia than the Fazekas score  $\leq 4$  group. Finally, imaging findings showed that the patients in the Fazekas score  $\geq 5$  group had more severe lacunar infarction. These differences are strongly associated with a high white matter burden in CSVD.

In patients 1, 2 and 3, who had the three most expanded GGC repeat numbers, moderate-to-severe deep and periventricular WMH were identified on T2-weighted FLAIR images of brain MRI (online supplemental figure 1). These three patients were also found to have much longer disease duration than those patients with CSVD with fewer than 60 GGC repeats in the *NOTCH2NLC* gene (table 2); their Fazekas score was the highest, > 4 points, and the only two cases of patients with brain atrophy were among them (table 3 and online supplemental figure 1); all three patients had moderate cognitive impairment,

**Table 2** Clinical characteristics of the patients harbouring GGC repeat expansion in *NOTCH2NLC*

Patient	Sex	Age at onset	Repeat number	Initial symptoms	Duration	Cerebrovascular accident				
						Stroke	Risk factors	Family history/stroke	Muscle weakness	Sensory disturbance
1	M	62	98	Dizziness	1 Year	–	HHcy	–	–	–
2	F	66	92	Dizziness	1 Year	CI, ICH	HTN	–	–	–
3	F	64	65	Dizziness	10 Years	–	HTN, HL	+	–	–
4	M	62	57	Weakness of the limb	2 Months	CI	HL, DM	–	+	+
5	M	37	50	Speech impairment	2 Months	CI	HTN, HHcy	+	–	–
6	F	48	46	Dizziness, Headache	10 Days	–	HTN	–	–	–
7	M	63	43	Speech impairment	4 Months	CI	–	–	+	–
8	F	67	42	Speech impairment, Weakness of the limb	5 Months	CI	HTN, HHcy, CAD	–	+	–
9	M	65	41	Dizziness	6 Days	–	HTN, HHcy	–	–	–

‘–’ indicates absent and ‘+’ indicates present.  
 CAD, coronary artery disease; CI, cerebral infarction; DM, diabetes mellitus; F, female; HHcy, hyperhomocysteinaemia; HL, hyperlipaemia; HTN, hypertension; ICH, intracerebral haemorrhage; M, male.;

and patient 2 also had problems with anxiety and depression (table 4). The majority of patients had a Fazekas score of 3 points with intermediate-length repeat expansions (table 3 and online supplemental figure 1); among the other six patients, five patients had mild to moderate cognitive impairment, three patients had depression and anxiety problems and one patient had anxiety problems (table 4). Other typical neuroimaging markers of CSVD

detected, including multiple lacunar infarcts, cerebral microbleeds and enlarged perivascular spaces, were not significant features in these nine patients (table 3).

## DISCUSSION

Our study set out to assess the relationship between expanded GGC repeats in *NOTCH2NLC* and CSVD. We identified nine patients with pathogenic expanded GGC repeats in *NOTCH2NLC*, from 41 to 98 repeats. WES failed to identify any pathogenic mutations in previously reported CSVD-related genes in any of these patients.<sup>21</sup> Moreover, eight of them had definite risk factors for cerebrovascular accidents, and none presented any of the typical symptoms of adult-onset NIID. Brain MRI scans of these patients did not reveal a high symmetrical signal in the corticomedullary junctions on DWI.<sup>19</sup>

The minor allele frequency of expanded GGC repeats in *NOTCH2NLC* was 0.55%, considerably lower than in patients with NIID, but closer to that in a cohort of patients with dementia.<sup>10 11</sup> Given that CSVD is a major factor leading to vascular dementia,<sup>17</sup> both NIID and CSVD have WMH on T2-FLAIR sequence, and we speculate that *NOTCH2NLC* GGC repeat expansions contribute to CSVD. It is worth mentioning that Jiao *et al* showed that the mean repeat size in patients with vascular dementia was 19.76±5.33 units, with 16 units (4/37, 10.8%) being the most frequent repeat size,<sup>21</sup> which might be explained by the small sample size and absence of healthy controls. In our previous study,<sup>20</sup> GGC repeats in 1134 healthy

**Table 3** Neuroradiological features of the patients harbouring GGC repeat expansion in *NOTCH2NLC*

Patient	The Fazekas score of WMH					
	Periventricular	Deep	LI	CMB	EPS	BA
1	2	2	+	NA	+	+
2	3	1	–	+	–	+
3	3	2	+	+	+	–
4	2	1	+	–	+	–
5	2	2	+	+	–	–
6	2	1	–	NA	–	–
7	2	1	+	NA	+	–
8	2	1	+	+	+	–
9	2	1	+	NA	–	–

‘+’ indicates present and ‘–’ indicates absent.  
 BA, brain atrophy; CMB, cerebral microbleeds; EPS, enlarged perivascular spaces; LI, lacunar infarcts; NA, not available; WMH, white matter hyperintensity.

**Table 4** Cognitive and psychological characteristics of the patients harbouring GGC repeat expansion in *NOTCH2NLC*

Patient	MMSE*	MoCA†	TMT‡		HADS§		AD8¶	BNT**
			A	B	A	D		
1	25	15	74	140	8	4	3	16
2	17	11	236	NA	18	11	2	12
3	25	17	87	156	5	4	3	15
4	26	18	61	NA	9	13	4	19
5	28	26	90	168	14	8	1	19
6	27	24	30	NA	1	6	1	20
7	18	11	152	NA	3	4	4	18
8	27	25	156	330	10	8	7	16
9	27	24	42	72	8	4	0	19

\*MMSE: a score of 27–30 indicates normal; 21–26 indicates mildly impaired cognitive function; 10–20 indicates moderately impaired cognitive function; 0–9 indicates severely impaired cognitive function.

†MoCA: a score below 26 suggests impaired cognitive function.

‡TMT: the results of both TMT A and B were recorded as the number of seconds required to complete the test, a TMT A score higher than 78 reveals deficient cognitive function, a TMT B score higher than 273 reveals deficient cognitive function.

§HADS: HADS-A, evaluating anxiety; HADS-D, evaluating depression. A score of 0–7 indicates asymptomatic (normal and mild); 8–10 indicates anxiety or depression probably present (moderate); 11–21 indicates anxiety or depression definitely present (severe).

¶AD8: a score higher than or equal to 2 suggests possible cognitive impairment.

\*\*BNT: 20-items version.

AD8, Ascertain Dementia 8-item Questionnaire; BNT, Boston naming test; HADS, Hospital Anxiety and Depression Scale; MMSE, Mini-Mental State Examination; MoCA, Montreal Cognitive Assessment; NA, not available; TMT A&B, Trial Making Test A and B.

individuals ranged from 6 to 39 units, with a mean repeat size of  $18.80 \pm 5.07$ . We defined the number of GGC repeat expansions ranging from 41 to 60 as intermediate-length expansions; besides, the number of GGC repeats in the control group was fewer than 40 times in the vast majority of studies on *NOTCH2NLC* expanded GGC repeats reported.<sup>10 11 22 23</sup> Therefore, we considered 41 as a critical value for pathogenic repeat number in patients with CSVD.

In our study, brain MRI of all patients with CSVD carrying pathogenic expanded GGC repeats showed moderate to severe WMH based on the Fazekas scale. Although the typical symmetrical high signal in cortico-medullary junctions on DWI is an indicator for NIID diagnosis,<sup>19</sup> severe WMH on T2-FLAIR brain MRI scans could be seen in almost all patients who had dementia-dominant NIID. Furthermore, a recent study found that expanded *NOTCH2NLC* GGC repeats are a leading cause of adult leukoencephalopathy. This disease was characterised by WMH on T2-FLAIR images with no known genetic aetiology in a Japanese cohort.<sup>14</sup> Significant WMH on T2-FLAIR images were also observed in three expanded GGC repeat carriers after screening for such GGC repeat expansions in a Chinese AD cohort.<sup>21</sup> Furthermore, our study found that patients 1, 2, 3, 4 and 5, who had the five most expanded GGC repeat numbers among the RP-PCR-positive patients, presented with relatively severe WMH on T2-FLAIR brain MRI scans. All these findings agree with the hypothesis that WMH on T2-FLAIR images might be a neuroradiologic marker of *NOTCH2NLC* GGC repeat expansions, which is expected to become a breakthrough

point in exploring the relationship between *NOTCH2NLC* GGC repeat expansions and CSVD.

In the sporadic adult form of NIID, dementia is the most prominent symptom.<sup>13 16</sup> Several previous studies reported that *NOTCH2NLC* expanded GGC repeats were found in AD-affected families and patients with sporadic AD. Affected patients harbouring a relatively large number of repeats usually had older age of onset and presented with typical and severe dementia symptoms.<sup>11 21</sup> Consistent with this, the nine patients developed cognitive dysfunctions, anxiety and depression problems with different degrees of severity. In fact, growing research has revealed the potential role of vascular pathology in AD progression, especially in older individuals.<sup>24</sup> As we know, CSVD is a major vascular dementia and cognitive dysfunction contributor,<sup>17</sup> and our study found that expanded GGC repeats in *NOTCH2NLC* could partly explain either neurodegenerative or vascular dementia. Of course, further research is required to investigate the specific pathogenicity of *NOTCH2NLC* GGC repeat expansions in patients with CSVD.

Liu *et al* reported that NIID accounts for one-fifth of patients with adult-onset genetically undiagnosed non-vascular leukoencephalopathies in Taiwan.<sup>25</sup> The patients with NIID they identified were found harbouring 73–323 GGC repeats in the *NOTCH2NLC* gene. However, our study investigated the relationship between CSVD and GGC repeat expansion, and the patients who were *NOTCH2NLC*-positive CSVD we identified were found to be harbouring relatively smaller *NOTCH2NLC* GGC repeats (41–100), especially the 41–60 GGC repeats,

which we termed the ‘intermediate-length’ repeats.<sup>20</sup> Thus, our study mainly demonstrated the relationship between CSVD and fewer than 100 GGC repeats.

In our study, the GGC repeat expansion in the *NOTCH2NLC* gene might act as a risk factor for CSVD, a cluster of vascular disorders. The mechanisms by which the GGC repeats in the *NOTCH2NLC* gene lead or are associated with vascular injury remain elusive. However, ubiquitin-positive intranuclear inclusions and p62-positive have been identified in the blood vessels of patients with NIID.<sup>26</sup> Moreover, fragile X-associated tremor/ataxia syndrome (FXTAS), which is attributed to a CGG repeat expansion in another gene (*FMRI*), has highly overlapping clinical and radiological features with NIID.<sup>27</sup> Intranuclear inclusions have been identified in the endothelial cells of capillaries in patients with FXTAS, which were thought to lead to cerebrovascular dysfunction.<sup>28</sup> Taking all these factors together, we speculate that the GGC repeat expansion may lead to cerebrovascular injury via the deposition of p62-positive and ubiquitin-positive intranuclear inclusions and the ensuing dysfunction in the endothelial cells of capillaries.

Skin or other tissue biopsy is the only useful tool for the antemortem diagnosis of NIID.<sup>29</sup> In clinical practice, there are currently no unified diagnostic criteria in NIID. The diagnosis is mainly based on typical clinical manifestations combined with the high symmetrical signal in the corticomedullary junctions on DWI to determine a suspicious diagnosis. The clinical features of NIID are variable, with the most common involvement of the central, peripheral and autonomic nerves. Unfortunately, none of these nine patients with CSVD with the GGC repeat expansion agreed to accept further examination, including a skin biopsy. The nine patients with repeat expansions only had symptoms in the central nervous system. Besides, there were no typical manifestations of NIID on imaging; that is, brain MRI scans of these nine patients with CSVD did not reveal a high symmetrical signal in the corticomedullary junctions on DWI.<sup>19</sup> In addition, by asking the parents and children of these patients about their physical conditions, and investigating their family history of disease, we found no suspected medical history.

GGC repeat expansions have been found in NIID, adult-onset leukoencephalopathy, essential tremor disease and other diseases.<sup>11 14 20 30–33</sup> Therefore, a study proposes to define the term NIID-related disease (NIIDRD) as referring to a series of diseases, such as NIID and other diseases caused by GGC repeat expansion in the *NOTCH2NLC* gene. Our findings suggest that GGC repeat expansion is also associated with CSVD, which expands the scope of NIIDRD. Screening for the GGC repeat expansion in the *NOTCH2NLC* gene needs to be conducted in more patients with CSVD to clarify the relationship between GGC repeats and CSVD. Moreover, the blood vessel organoids of CSVD patients who had *NOTCH2NLC*-positive are an excellent model to explore the mechanisms underlying *NOTCH2NLC* GGC repeats-induced vascular dysfunction.<sup>34</sup>

## CONCLUSION

*NOTCH2NLC* GGC repeat expansions were not rare in the studied Han Chinese population with CSVD. Our findings suggest that the intermediate-length and longer-length GGC repeat expansions in *NOTCH2NLC* are associated with sporadic CSVD. Our findings provide new insights into the molecular pathogenesis of CSVD, which provides clues to explore the mechanism of the disease. This study has certain limitations: the patients came from a single recruitment centre, and this study only recruited patients with CSVD with a Fazekas score of WMH  $\geq 3$  points on neuroimaging. Unfortunately, the nine patients refused to accept further clinical re-evaluation. The mechanism of how abnormal GGC repeat expansion in the *NOTCH2NLC* gene increases the risk of CSVD remains unclear, and further study to establish suitable models is needed.

**Contributors** YW, YF, YX and C-HS contributed to the conception and design of the study. W-KY, SS, J-DL, L-LY, Z-CZ, S-SL and YD contributed to collecting clinical data of the patients. YW and YF contributed to the DNA extraction and genetic analysis. YW, YF, YG, YJ and Y-SL contributed to the analysis of data. YW contributed to drafting and critical revision of the manuscript. YX is responsible for the overall content as guarantor. All authors critically reviewed the manuscript and approved it as submitted.

**Funding** This work was supported by the Non-profit Central Research Institute Fund of Chinese Academy of Medical Sciences [grant number 2020-PT310-01], the National Natural Science Foundation of China to Dr. Chang-he Shi [grant number 82171247, 81974211], the National Natural Science Foundation of China to Dr. Yu-ming Xu [grant numbers U1904207].

**Competing interests** None declared.

**Patient consent for publication** Not applicable.

**Ethics approval** This study was approved by the ethics committee of the First Affiliated Hospital of Zhengzhou University. Reference number: 2021-KY-1059-002. Participants gave informed consent to participate in the study before taking part.

**Provenance and peer review** Not commissioned; externally peer reviewed.

**Data availability statement** All data relevant to the study are included in the article or uploaded as supplementary information.

**Supplemental material** This content has been supplied by the author(s). It has not been vetted by BMJ Publishing Group Limited (BMJ) and may not have been peer-reviewed. Any opinions or recommendations discussed are solely those of the author(s) and are not endorsed by BMJ. BMJ disclaims all liability and responsibility arising from any reliance placed on the content. Where the content includes any translated material, BMJ does not warrant the accuracy and reliability of the translations (including but not limited to local regulations, clinical guidelines, terminology, drug names and drug dosages), and is not responsible for any error and/or omissions arising from translation and adaptation or otherwise.

**Open access** This is an open access article distributed in accordance with the Creative Commons Attribution Non Commercial (CC BY-NC 4.0) license, which permits others to distribute, remix, adapt, build upon this work non-commercially, and license their derivative works on different terms, provided the original work is properly cited, appropriate credit is given, any changes made indicated, and the use is non-commercial. See: <http://creativecommons.org/licenses/by-nc/4.0/>.

## ORCID iDs

Yun-chao Wang <http://orcid.org/0000-0002-3702-3826>

Chang-He Shi <http://orcid.org/0000-0002-4843-0072>

Yu-ming Xu <http://orcid.org/0000-0003-2689-9897>

## REFERENCES

- Pantoni L. Cerebral small vessel disease: from pathogenesis and clinical characteristics to therapeutic challenges. *Lancet Neurol* 2010;9:689–701.



- 2 Choi JC. Genetics of cerebral small vessel disease. *J Stroke* 2015;17:7–16.
- 3 Kubo M, Hata J, Ninomiya T, *et al.* A nonsynonymous SNP in PRKCH (protein kinase C eta) increases the risk of cerebral infarction. *Nat Genet* 2007;39:212–7.
- 4 Fornage M, Debette S, Bis JC, *et al.* Genome-Wide association studies of cerebral white matter lesion burden: the charge Consortium. *Ann Neurol* 2011;69:928–39.
- 5 Woo D, Falcone GJ, Devan WJ, *et al.* Meta-Analysis of genome-wide association studies identifies 1q22 as a susceptibility locus for intracerebral hemorrhage. *Am J Hum Genet* 2014;94:511–21.
- 6 Joutel A, Vahedi K, Corpechot C, *et al.* Strong clustering and stereotyped nature of Notch3 mutations in CADASIL patients. *Lancet* 1997;350:1511–5.
- 7 Hara K, Shiga A, Fukutake T, *et al.* Association of HTRA1 mutations and familial ischemic cerebral small-vessel disease. *N Engl J Med* 2009;360:1729–39.
- 8 Vahedi K, Boukobza M, Massin P, *et al.* Clinical and brain MRI follow-up study of a family with COL4A1 mutation. *Neurology* 2007;69:1564–8.
- 9 Gunda B, Mine M, Kovács T, *et al.* Col4A2 mutation causing adult onset recurrent intracerebral hemorrhage and leukoencephalopathy. *J Neurol* 2014;261:500–3.
- 10 Sone J, Mitsuhashi S, Fujita A, *et al.* Long-Read sequencing identifies GGC repeat expansions in NOTCH2NLC associated with neuronal intranuclear inclusion disease. *Nat Genet* 2019;51:1215–21.
- 11 Tian Y, Wang J-L, Huang W, *et al.* Expansion of human-specific GGC repeat in neuronal intranuclear inclusion disease-related disorders. *Am J Hum Genet* 2019;105:166–76.
- 12 Sone J, Kitagawa N, Sugawara E, *et al.* Neuronal intranuclear inclusion disease cases with leukoencephalopathy diagnosed via skin biopsy. *J Neurol Neurosurg Psychiatry* 2014;85:354–6.
- 13 Sone J, Mori K, Inagaki T, *et al.* Clinicopathological features of adult-onset neuronal intranuclear inclusion disease. *Brain* 2016;139:3170–86.
- 14 Okubo M, Doi H, Fukai R, *et al.* GGC Repeat Expansion of NOTCH2NLC in Adult Patients with Leukoencephalopathy. *Ann Neurol* 2019;86:962–8.
- 15 Munoz-Garcia D, Ludwin SK. Adult-Onset neuronal intranuclear hyaline inclusion disease. *Neurology* 1986;36:785–90.
- 16 Araki K, Sone J, Fujioka Y, *et al.* Memory loss and frontal cognitive dysfunction in a patient with adult-onset neuronal intranuclear inclusion disease. *Intern Med* 2016;55:2281–4.
- 17 Wardlaw JM, Smith C, Dichgans M. Mechanisms of sporadic cerebral small vessel disease: insights from neuroimaging. *Lancet Neurol* 2013;12:483–97.
- 18 Wardlaw JM, Smith EE, Biessels GJ, *et al.* Neuroimaging standards for research into small vessel disease and its contribution to ageing and neurodegeneration. *Lancet Neurol* 2013;12:822–38.
- 19 Sugiyama A, Sato N, Kimura Y, *et al.* Mr imaging features of the cerebellum in adult-onset neuronal intranuclear inclusion disease: 8 cases. *AJNR Am J Neuroradiol* 2017;38:2100–4.
- 20 Shi C-H, Fan Y, Yang J, *et al.* NOTCH2NLC intermediate-length repeat expansions are associated with Parkinson disease. *Ann Neurol* 2021;89:182–7.
- 21 Jiao B, Zhou L, Zhou Y, *et al.* Identification of expanded repeats in NOTCH2NLC in neurodegenerative dementias. *Neurobiol Aging* 2020;89:e1–142.e7.
- 22 Ishiura H, Shibata S, Yoshimura J, *et al.* Noncoding CGG repeat expansions in neuronal intranuclear inclusion disease, oculopharyngodistal myopathy and an overlapping disease. *Nat Genet* 2019;51:1222–32.
- 23 Deng J, Gu M, Miao Y, *et al.* Long-read sequencing identified repeat expansions in the 5'UTR of the NOTCH2NLC gene from Chinese patients with neuronal intranuclear inclusion disease. *J Med Genet* 2019;56:758–64.
- 24 Prins ND, Scheltens P. White matter hyperintensities, cognitive impairment and dementia: an update. *Nat Rev Neurol* 2015;11:157–65.
- 25 Liu YH, Chou YT, Chang FP, *et al.* Neuronal intranuclear inclusion disease in patients with adult-onset non-vascular leukoencephalopathy. *Brain* 2022;145:3010–21.
- 26 Chen H, Lu L, Wang B, *et al.* Re-defining the clinicopathological spectrum of neuronal intranuclear inclusion disease. *Ann Clin Transl Neurol* 2020;7:1930–41.
- 27 Ng ASL, Xu Z, Chen Z, *et al.* NOTCH2NLC-linked neuronal intranuclear inclusion body disease and fragile X-associated tremor/ataxia syndrome. *Brain* 2020;143:e69.
- 28 Salcedo-Arellano MJ, Wang JY, McLennan YA, *et al.* Cerebral microbleeds in fragile X-associated tremor/ataxia syndrome. *Mov Disord* 2021;36:1935–43.
- 29 Sone J, Tanaka F, Koike H, *et al.* Skin biopsy is useful for the antemortem diagnosis of neuronal intranuclear inclusion disease. *Neurology* 2011;76:1372–6.
- 30 Sun Q-Y, Xu Q, Tian Y, *et al.* Expansion of GGC repeat in the human-specific NOTCH2NLC gene is associated with essential tremor. *Brain* 2020;143:222–33.
- 31 Hayashi T, Katagiri S, Mizobuchi K, *et al.* Heterozygous GGC repeat expansion of NOTCH2NLC in a patient with neuronal intranuclear inclusion disease and progressive retinal dystrophy. *Ophthalmic Genet* 2020;41:93–5.
- 32 Fang P, Yu Y, Yao S, *et al.* Repeat expansion scanning of the NOTCH2NLC gene in patients with multiple system atrophy. *Ann Clin Transl Neurol* 2020;7:517–26.
- 33 Jih K-Y, Chou Y-T, Tsai P-C, *et al.* Analysis of NOTCH2NLC GGC repeat expansion in Taiwanese patients with amyotrophic lateral sclerosis. *Neurobiol Aging* 2021;108:210–2.
- 34 Wimmer RA, Leopoldi A, Aichinger M, *et al.* Human blood vessel organoids as a model of diabetic vasculopathy. *Nature* 2019;565:505–10.