

CINE-ANGIOCARDIOGRAPHIC STUDIES OF THE OUTFLOW TRACT IN ISOLATED PULMONARY VALVULAR STENOSIS

BY

HAMISH WATSON, C. PICKARD, K. G. LOWE, AND IAN G. W. HILL

From the Departments of Medicine and Radiology, University of St. Andrews and Dundee Royal Infirmary

Received March 5, 1960

Much of the confusion and misunderstanding regarding the nature of the obstruction to the outflow of blood from the right ventricle in patients with pulmonary stenosis is being resolved and the complex nature of the problem more fully recognized. Some five types of obstruction can be defined. First, there may be obstruction due to an abnormal pulmonary valve—pulmonary valvular stenosis. Secondly, there may be obstruction in the infundibular region due to a variety of congenital infundibular lesions such as are commonly seen in patients with Fallot's tetralogy. Thirdly, there may be combined infundibular and valvular lesions, again most commonly seen in Fallot's tetralogy. In these three varieties of pulmonary stenosis, pressure gradients at the sites of obstruction can be demonstrated during cardiac catheterization. The characteristic pressure pulse tracings, pressure artefacts, and possible misinterpretations of the pressure tracings are discussed by numerous authors (Sobin *et al.*, 1954; Wood *et al.*, 1954; Emslie-Smith *et al.*, 1956; Kjellberg *et al.*, 1959). Fourthly, a rather rare form of obstruction is due to constriction in the pulmonary arterial tree—supravalvular pulmonary stenosis (Arvidsson *et al.*, 1955; Kjellberg *et al.*, 1959).

Lastly, the most intriguing and controversial aspect of the subject lies in the concept of acquired infundibular obstruction in patients with congenital pulmonary valvular stenosis due to massive hypertrophy of the right ventricle. This concept has been developed by a number of workers who have studied right ventricular dynamics in pulmonary valvular stenosis with intact ventricular septum (Kirklin *et al.*, 1953; Swan *et al.*, 1954; Brock, 1955; Blount *et al.*, 1957; McGoon and Kirklin, 1958; Engle *et al.*, 1958; Johnson, 1959) but has been rejected by others (Bing *et al.*, 1954; Kjellberg *et al.*, 1959). Because of the uncertainty regarding the importance of infundibular obstruction due to muscular hypertrophy in pulmonary valvular stenosis, surgeons have been divided in opinion regarding the need for infundibular resection along with pulmonary valvotomy. Hitherto, their views on the subject have rested on hæmodynamic considerations. In severe pulmonary valvular stenosis with right ventricular hypertrophy there is usually a systolic pressure gradient at the valve site only and though the infundibular lumen may be narrowed, the high pressure is uniformly distributed throughout the ventricular cavity. In some cases, however, following successful valvotomy an infundibular systolic pressure gradient may become evident and in these presumably the narrowing of the infundibular lumen remains the sole obstruction to rapid outflow of blood. This pressure gradient can be reduced immediately by infundibular resection, but even if this part of the operation is not carried out, cardiac catheterization at a later date may show regression of the infundibular pressure gradient, presumably due to involution of the hypertrophied infundibular muscle (Engle *et al.*, 1958; Johnson, 1959). Kjellberg *et al.* (1959) state that in their experience residual systolic gradients have only followed inadequate pulmonary valvotomies and they stress the difficulties in interpreting the pressure pulses and locating the site of stenosis. They deny that infundibular hypertrophy can obstruct the outflow of blood from the right ventricle

in pulmonary valvular stenosis though they concede that angiocardiology may show considerable narrowing of the outflow tract in late systole. Moreover, in their patients in whom they carried out angiocardiology both before and after pulmonary valvotomy they observed appreciable widening of the infundibulum 5 to 12 months following pulmonary valvotomy.

Diagnosis of pulmonary valvular stenosis in this centre as elsewhere rests on the evaluation of the clinical, radiological and electrocardiographic features together with the findings at cardiac catheterization. As additional tools, intracardiac electrocardiography and selective cine-angiocardiology are employed. Interpretation of the pressure pulses is made with due regard to such possible sources of error as Venturi effects, pressure artefacts due to catheter movements, etc., and the intracardiac electrogram, obtained from an electrode at the tip of the catheter, is used as an aid in locating the site of stenosis on the withdrawal tracings (Emslie-Smith *et al.*, 1956). Fig. 1 illustrates such pressure pulses and intracardiac electrograms recorded during cardiac catheterization.

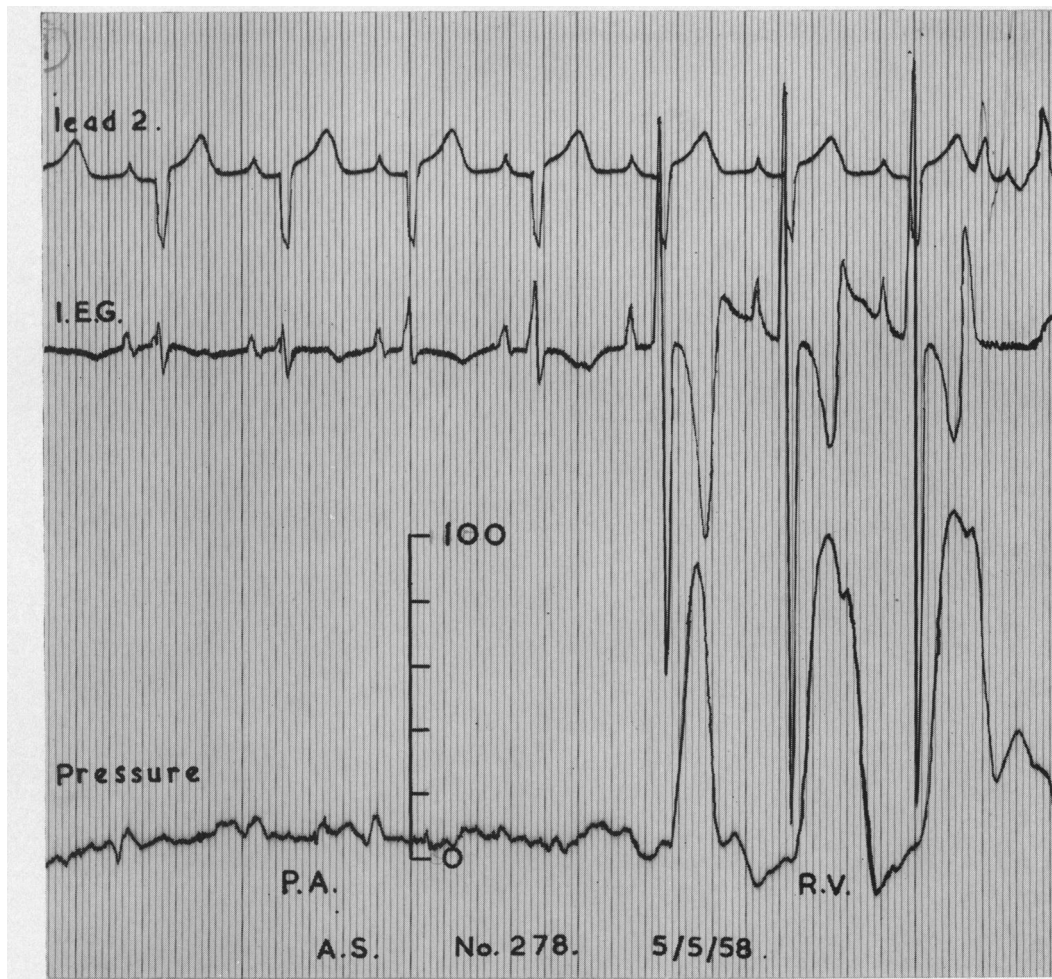


FIG. 1.—A withdrawal tracing from pulmonary trunk to right ventricle obtained at cardiac catheterization in a patient with severe isolated pulmonary valvular stenosis, whose selective cine-angiocardiology is illustrated in Fig. 4. The changes in the intracardiac electrogram and the pressure pulse are both abrupt and synchronous, indicating valvular stenosis. The use of intracardiac electrocardiology in this way pin-points the site of the valve on the record.

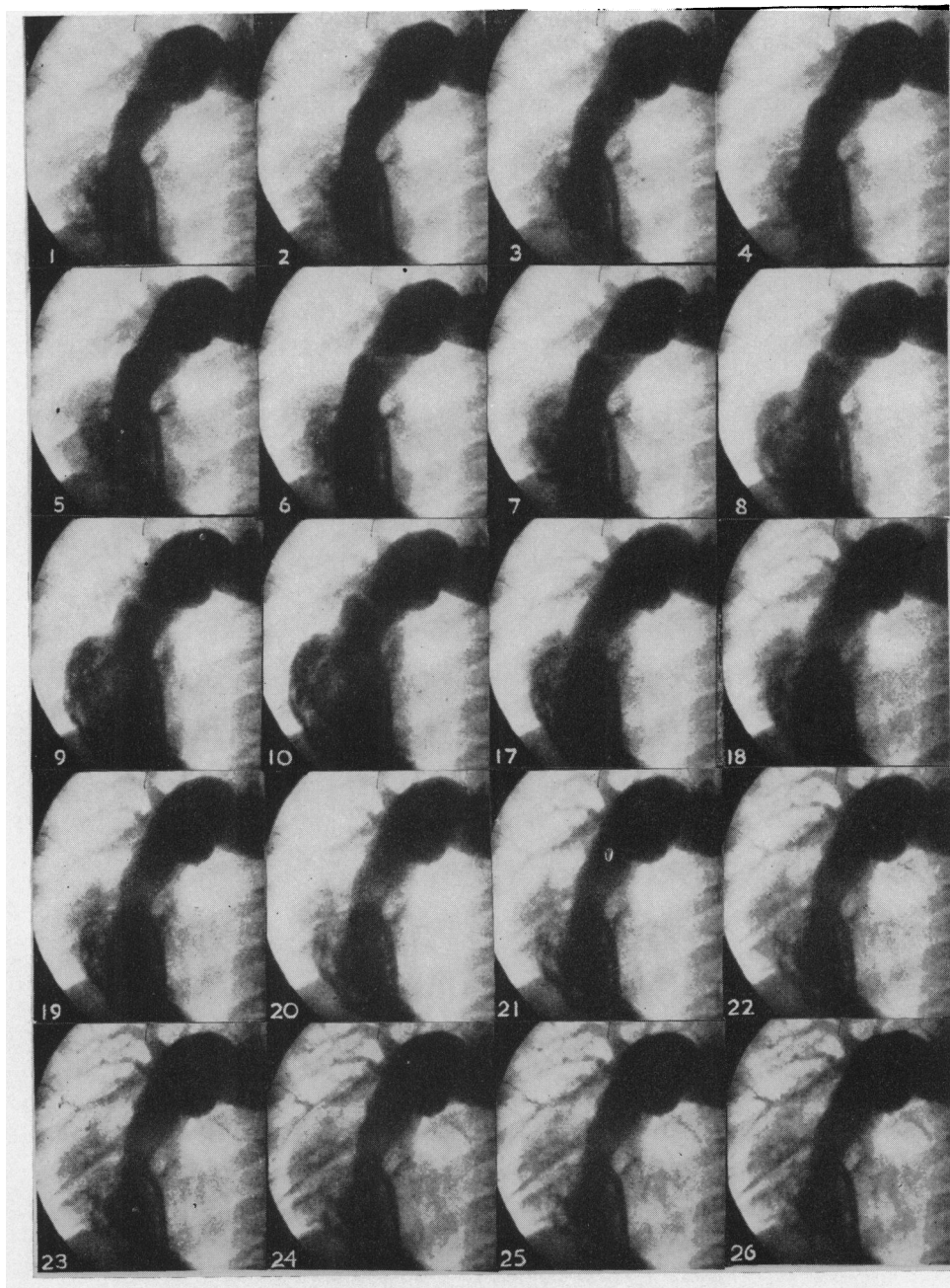


FIG. 2.—Mild isolated pulmonary valvular stenosis—right ventricular pressure 46/0 mm. Hg. A series of 26 consecutive frames, taken at or exceeding 50 frames per second, from a selective cine-angiogram on a four-year-old girl. Six frames (No. 11–16), showing the outflow tract in the fully dilated phase, have been removed. The patient is in the left anterior oblique position and the contrast medium injected into the apex of the right ventricle. During systole there is slight narrowing throughout the whole length of the outflow tract, which becomes widely dilated during diastole. Its appearance is almost within normal limits, though in an earlier part of the film, during the initial opacification and before the post-stenotic dilatation becomes densely outlined, a jet can be clearly seen issuing from the stenosed pulmonary valve.

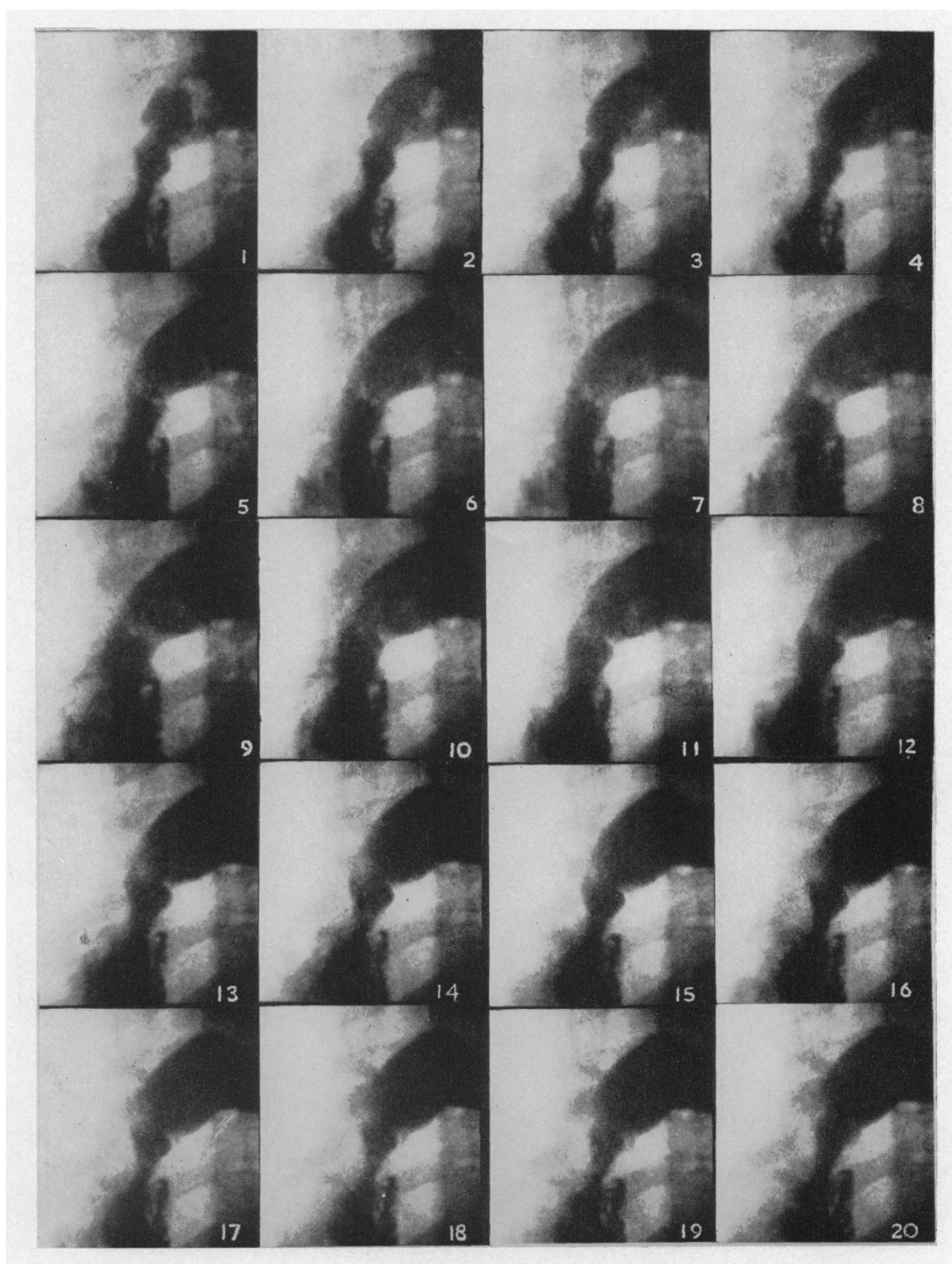

FIG. 3.—Moderate isolated pulmonary valvular stenosis—right ventricular pressure 73/0 mm. Hg. A series of 20 consecutive frames, taken at or exceeding 50 frames per second, from a selective cine-angiogram on a 9-year-old girl with pulmonary valvular stenosis confirmed at operation, and showing a complete cardiac cycle; position of patient and site of injection as in Fig. 2. In this instance there is significant narrowing of the outflow tract throughout its whole length, and though it is still capable of fairly wide dilatation, the duration of this phase is short. In the first few frames the jet ejected through the stenosed valve can be traced in the dilated pulmonary trunk, and the turbulence in this region can be seen.

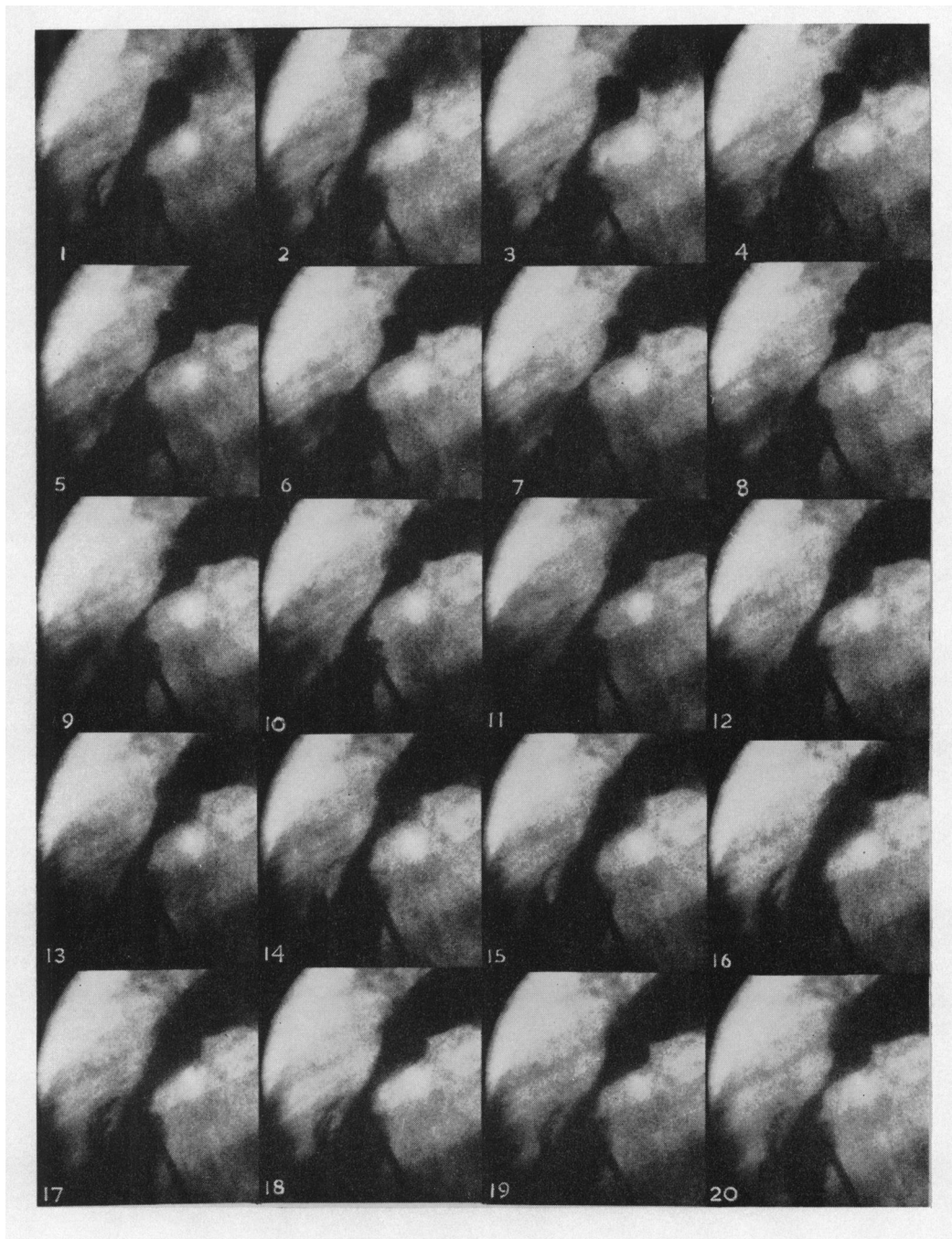


FIG. 4.—Severe isolated pulmonary valvular stenosis—right ventricular pressure 110/0 mm. Hg. A series of 20 consecutive frames taken at approximately 50 frames per second, from a selective cine-angiogram on a 9-year-old boy with pulmonary valvular stenosis, confirmed at operation. Sixteen frames represent a complete cardiac cycle and the position of the patient and the site of the injection are as in Fig. 2. The outflow tract is grossly narrowed throughout its entire length, and though there is a phase of dilatation, No. 15, 16, and 17, it is both brief and incomplete.

As the catheter tip is withdrawn from the pulmonary artery into the right ventricle there is an abrupt and synchronous alteration in both the pressure pulse and the intracardiac electrogram. This change is characteristic of severe stenosis of the pulmonary valve, and in this case the diagnosis was supported by selective cine-angiocardiology (Fig. 4) and later confirmed at operation.

Cine-angiocardiology is carried out using image-intensification and selective injection into the right ventricle (Watson *et al.*, 1958); with this technique cine-films can be taken at 50 or more frames per second and projected at varying speeds or studied as serial stills, thereby facilitating study of the intracardiac circulation. In Fig. 2, 3, and 4, are shown excerpts from such cine-films taken in three representative cases of isolated pulmonary valvular stenosis of mild, moderate, and severe degree respectively. It will be seen that in general the degree of narrowing of the infundibular lumen is roughly proportional to the severity of the pulmonary valvular stenosis, as judged by the right ventricular systolic pressure, and that the duration of the dilated phase in diastole is inversely proportional to the severity of the stenosis. The narrowing of the lumen of the outflow tract in the severe case (Fig. 4) is gross in all phases of the cardiac cycle.

It will be apparent from the figures that this narrowing of the infundibulum is no momentary event, and that in severe valvular stenosis it persists for the greater part of the cardiac cycle. In Fig. 4, for example, where a complete heart cycle is depicted in sixteen consecutive frames (No. 2-18) in three frames only (No. 15, 16, and 17) is the outflow tract partially dilated. In the remaining 12 pictures it shows narrowing, and in many of them this is of extreme degree. It is dilatation that is the momentary event in such cases and in this instance it appears in only three frames.

The demonstration of a phase of dilatation, however brief, is good evidence against obstruction from a fibrous or other unyielding barrier. The infundibular muscle is known to be grossly hypertrophied in such cases and this infundibular hypertrophy associated with incomplete and momentary relaxation in diastole has so impressed us that we have come to speak of it as the *muscle-bound* right ventricular outflow tract in severe isolated pulmonary valvular stenosis. The Oxford English Dictionary defines *muscle-bound* as "with muscles stiff and inelastic through over-exercise".

SUMMARY

Hæmodynamic considerations have led to the concept of acquired infundibular muscular hypertrophy forming a further obstruction to the outflow of blood from the right ventricle in patients with severe isolated valvular pulmonary stenosis. An infundibular pressure gradient may become apparent following successful pulmonary valvotomy. This gradient can be reduced immediately by infundibular resection or may regress spontaneously over some months.

It is suggested that selective cine-angiocardiology of the right ventricular outflow tract and cardiac catheterization with combined recording of the pressure pulse and intracardiac electrogram provide the most complete analysis of the nature of the obstruction in pulmonary stenosis. The cine-angiocardiological findings lend further support to the concept of infundibular obstruction from muscular hypertrophy and show narrowing of the infundibular lumen roughly proportional to the severity of the valvular pulmonary stenosis. Dilatation of the outflow tract in severe cases is brief and incomplete, and its association with the muscular hypertrophy invites the use of the term "*muscle-bound* outflow tract".

We would like to record our appreciation of the willing co-operation we have had from our pædiatric and surgical colleagues and our thanks to Phillips Electrical Ltd. for certain apparatus.

REFERENCES

- Arvidsson, H., Karnell, J., and Möller, T. (1955). *Acta radiol.*, **44**, 209.
 Bing, R. J., Reber, W., Sparks, J. E., Balboni, F. A., Vitale, A. G., and Hanlon, M. (1954). *J. Amer. med. Ass.*, **154**, 127.
 Blount, S. G., Jr., van Elk, J., Balchum, O. J., and Swan, H. (1957). *Circulation*, **15**, 814.
 Brock, R. C. (1955). *Guy's Hosp. Rep.*, **104**, 356.
 Emslie-Smith, D., Lowe, K. G., and Hill, I. G. W. (1956). *Brit. Heart J.*, **18**, 29.

- Engle, M. A., Holswade, G. R., Goldberg, H. P., Lukas, D. S., and Glenn, F. (1958). *Circulation*, **17**, 862.
- Johnson, A. M. (1959). *Brit. Heart J.*, **21**, 429.
- Kirklin, J. W., Connolly, D. E., Ellis, F. H., Jr., Burchell, H. B., Edwards, J. E., and Wood, E. H. (1953). *Circulation*, **8**, 849.
- Kjellberg, S. R., Mannheimer, E., Rudhe, U., and Jonsson, B. (1959). *Diagnosis of Congenital Heart Disease*, 2nd ed. The Year Book Publishers Inc., Chicago.
- McGoon, D. C., and Kirklin, J. W. (1958). *Circulation*, **17**, 180.
- Sobin, S. S., Carson, M. J., Johnson, J. L., and Baker, C. R. (1954). *Amer. Heart J.*, **48**, 416.
- Swan, H., Cleveland, H. C., Mueller, H., and Blound, S. G., Jr. (1954). *J. thorac. Surg.*, **28**, 504.
- Watson, H., Pickard, C., Lowe, K. G., and Hill, I. G. W. (1958). *Brit. Heart J.*, **20**, 459.
- Wood, E. H., Leusen, I. R., Warner, H. R., and Wright, J. L. (1954). *Circulat. Research*, **2**, 294.